

Pedunculated HCC or adrenal metastasis: a diagnostic conundrum

M Mashfiqul A S, Tan Y M, Thng C H, Cheow P C, Chung Y F, Chow P K, Ooi L L P J

ABSTRACT

Hepatocellular carcinoma (HCC) is the commonest primary liver tumour. Recurrences are common in the liver although extrahepatic metastases can occur and frequently involve the adrenals. When this occurs in the right adrenal gland, it can be confused with an exophytic HCC arising from the posterior surface of the liver. The distinction between a primary HCC and a metastasis is important but can be difficult in this clinical setting. We report a 52-year-old man with recurrent HCC presenting as an “exophytic” posterior liver surface lesion that was actually a right adrenal metastasis. Although right-sided adrenal metastases of HCC can be difficult to distinguish from intrahepatic recurrences, even with modern diagnostic imaging, management either way involves surgical exploration and resection whenever possible.

Keywords: adrenal tumour, adrenalectomy hepatocellular carcinoma, liver cancer, pedunculated hepatocellular carcinoma

Singapore Med J 2007; 48(2):e50–e52

INTRODUCTION

Hepatocellular carcinoma (HCC) is the fourth commonest cancer worldwide and the commonest primary liver malignancy. The prognosis is poor unless the lesion is solitary, confined to the liver and resectable. Occasionally, patients with HCC present with metastases and the adrenal gland is a common site of involvement.⁽¹⁾ The right adrenal gland normally lies adjacent to the posterior surface of the liver, and when metastases occur in this location, may be easily mistaken for an exophytic HCC arising from the posterior surface of the liver. The distinction between the two, however, is important, as it affects the stage, prognosis and management of the patient. Iwamoto et al, in the only report in the English literature on this topic, suggested that such “pedunculated” HCC could represent a distinct and novel clinicopathological entity.⁽²⁾ We recently encountered a patient with a “pedunculated” HCC, and describe and discuss the clinical and radiological features of this unique entity.

CASE REPORT

A 52-year-old Vietnamese man with a history of hepatitis B cirrhosis was first diagnosed with HCC in segment V of the liver in August 2001 in Vietnam. He underwent resection of the HCC. Postoperatively, adjuvant 5-Fluorouracil was administered. Serum alpha-fetoprotein (AFP) was used to monitor progress. He remained well until April 2004 when the AFP rose from normal to 1,800 mU/L. Magnetic resonance (MR) imaging of the liver showed a 4.7-cm exophytic pedunculated mass arising from the posterior and inferior surface of segment VI, demonstrating hepatic arterial enhancement that faded in the portal venous phase. Imaging appearances were suspicious for hepatoma (Fig. 1). On the coronal MR images (Fig. 1b), a sliver of normal liver parenchyma could be seen draping over the lateral aspect of the mass giving a “claw-sign”, suggesting that the mass is hepatic in origin. Positron emission tomography confirmed the recurrent HCC in segment VI of the liver.

He underwent a planned resection for his HCC. Intraoperative ultrasonography did not demonstrate the segment VI HCC. However, there was a 6-cm metastatic lesion in the right adrenal gland (Fig. 2a). A right adrenalectomy was performed and the lesion was easily separated from the liver capsule (Figs. 2b–c). Postoperative recovery was uneventful. Histology was HCC of the sinusoidal and trabecular growth pattern, which had replaced almost the entire gland and invaded into the periadrenal fat. There was no lymphovascular invasion.

DISCUSSION

The right adrenal gland is intimately related to the inferior surface of the right lobe of the liver. The close association between the two structures increases with age,⁽³⁾ especially in cirrhotic livers,⁽⁴⁾ and is termed adrenohepatic fusion. This age-related phenomenon results in adhesion of the liver and right adrenal gland with close intermingling of the respective parenchyma cells and partial absence of the fibrous capsule dividing the two organs. In addition, vascular networks between these structures also develop. When adrenal metastases occur in patients with HCC, it is commoner in the right gland. This preference for the right gland cannot be

Department of Surgery, Singapore General Hospital, 1 Hospital Drive, Singapore 169608

M Mashfiqul AS, MBBS
Medical Officer

Cheow PC, MBBS, FRCSE, FAMS
Consultant

Chung YF, MBBS, FRCSE, FAMS
Senior Consultant

Chow PK, MBBS, PhD, FRCSE
Senior Consultant

Department of Oncologic Imaging, National Cancer Centre, 11 Hospital Drive, Singapore 169610

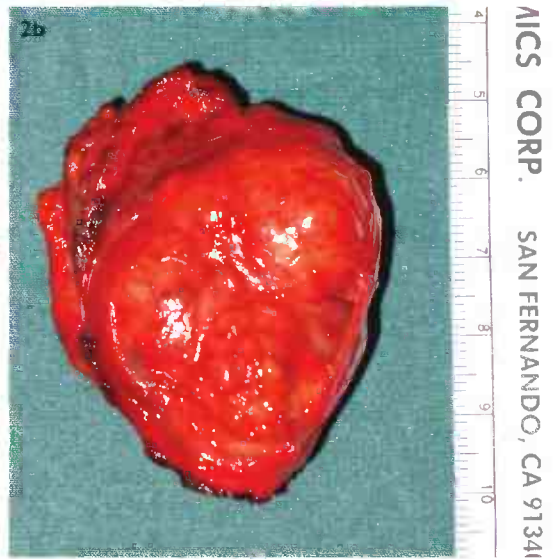
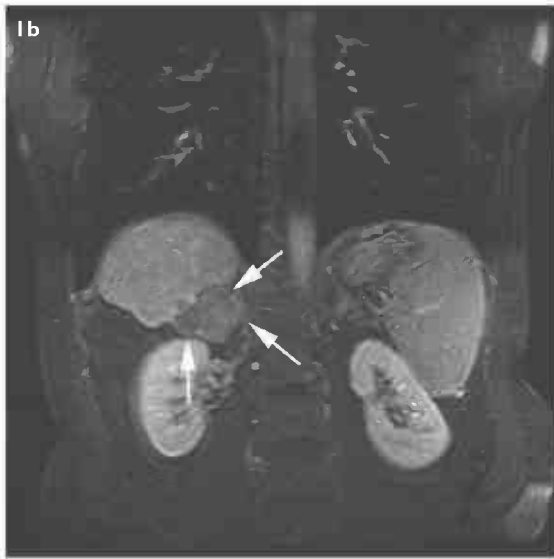
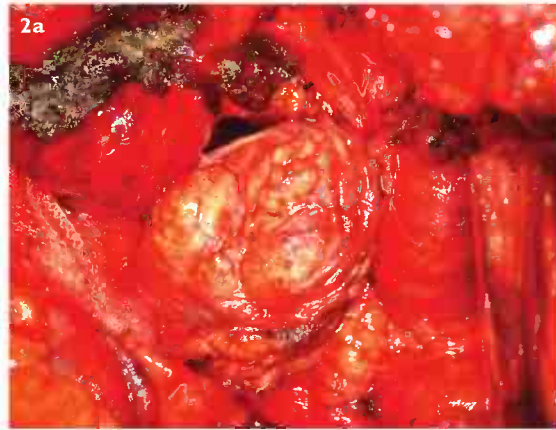
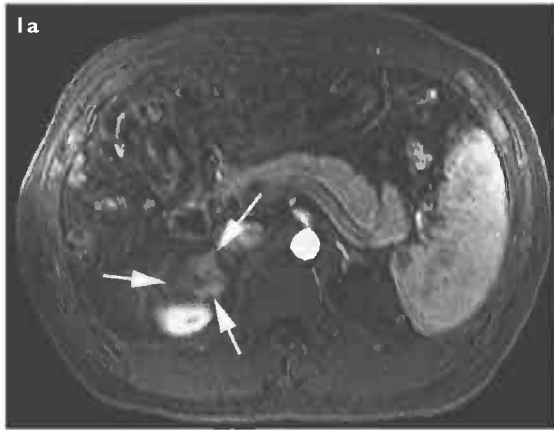
Thng CH, MBBS, FRCP, FAMS
Dy Head

Department of Surgical Oncology, National Cancer Centre

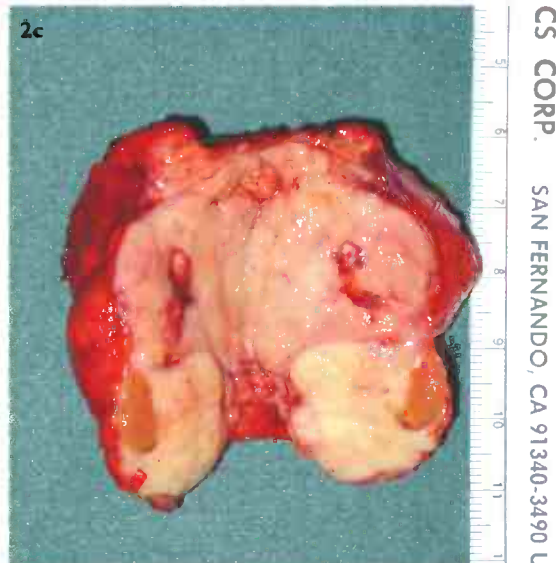
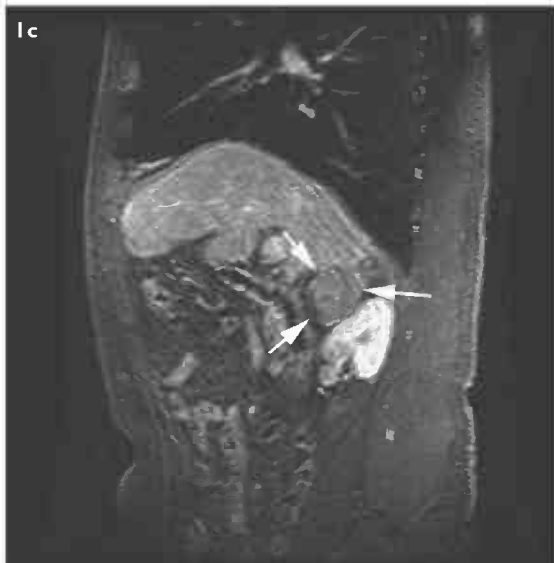Tan YM, MBBS, FRCSE, FAMS
Consultant

Ooi LLPJ, MD, FRCSE, FRCSG
Head

Correspondence to:
Dr London Lucien Ooi
Tel: (65) 6436 8154
Fax: (65) 6225 7559
Email: dsoopj@nccs.com.sg



AICS CORP. SAN FERNANDO, CA 91341



CS CORP. SAN FERNANDO, CA 91340-3490 U

Fig. 1 (a) Contrast-enhanced axial fat-suppressed T1-W gradient echo MR image taken in the hepatic arterial phase. Note that the lesion (white arrows) demonstrates typical hepatic arterial enhancement. (b) Contrast-enhanced coronal fat-suppressed T1-W gradient echo MR image taken in the late portal venous phase. The lesion (arrows) is thought to be exophytic from the liver. (c) Contrast-enhanced sagittal fat-suppressed T1-W gradient echo MR image taken in the late portal venous phase. The lesion (arrows) is typically hypointense in the late portal venous scan.

Fig. 2 (a) Intraoperative photograph of the right adrenal pedunculated tumour taken in-situ. (b) Specimen photograph of the excised right adrenal gland tumour. (c) Specimen photograph of the bivalved specimen of the right adrenal gland.

explained by systemic haematogenous spread and is perhaps best explained by the adrenohepatic fusion phenomenon described earlier.

In our patient, there was a difficulty in preoperative diagnosis between a right adrenal metastatic HCC and a recurrent right lobe HCC, as both MR imaging and PET showed features and characteristics typical of an intrahepatic HCC. This difficulty can also be explained by the phenomenon of adrenohepatic fusion accounting for the enhancement characteristics seen in triphasic CT and MR imaging that is typical of an intrahepatic HCC. Okuda proposed a distinct variant of HCC which he termed "pedunculated HCC" that is a result of this phenomenon.⁽⁴⁾ In his paper, he highlighted the possibility that right-sided pedunculated HCC were actually a form of extrahepatic adrenal metastasis. The patient we describe is similar to the three cases first reported by Okuda. Such tumours originate within the adrenal gland as a result of the intermingling of cells. Early on, these present as distinct adrenal tumours. However, as these tumours enlarge, there is increasing difficulty in differentiating these from a liver lesion. Finally, when fusion has occurred, these tumours are recognised as a "pedunculated" or an exophytic HCC.

The clinical significance of the entity "pedunculated HCC" are several. Firstly, it represents a form of metastasis that is difficult to diagnose preoperatively. The enhancement characteristics of this lesion are similar to that of intrahepatic HCC. Moreover, the growth pattern of the lesion is that of an expansile lesion from the inferior surface of the liver. Absence of the adrenal gland on imaging is not surprising as a locally expansile growth in this area would compress the gland, making it indistinct. The respective capsules of the liver and adrenal gland are also indistinct and do not contribute to differentiating the lesions. The adrenal

gland can occasionally be supplied by the right hepatic artery, and hepatic arterial angiography with lipiodol may be unable to distinguish the two types of lesion.⁽²⁾ Secondly, surgical exploration and resection should be carried out for all these tumours in order to determine the origin of this lesion, as resection for a localised intrahepatic HCC can be curative. In our patient, the "pedunculated" lesion represented an adrenal metastasis that was in close association with the liver. Although the long-term outcome of resection for such adrenal metastases is unknown, the isolated nature of the right adrenal disease can be easily controlled to obtain gross disease clearance and may provide better long-term survival.⁽⁵⁾ Thirdly, it is important to explore the possibility that such lesions may not represent distinct metastases, but are actually intrahepatic disease with extension to involve the right adrenal gland through the adrenohepatic fusion mechanism. This has implications in prognosis.

In conclusion, right-sided adrenal metastases of HCC can be difficult to distinguish from intrahepatic recurrence of HCC in the inferior surface of the liver, even with modern diagnostic imaging. Either way, the management involves surgical exploration and resection, whenever possible.

REFERENCES

1. Edmondson HA, Steiner PE. Primary carcinoma of the liver: a study of 100 cases among 48,900 necropsies. *Cancer* 1954; 7:462-503.
2. Iwamoto S, Okuda K, Takeda N, Sonoda K, Sanefuji H. Case report: right-sided periadrenal metastases supplied by the hepatic artery. Clue to the genesis of pedunculated hepatocellular carcinoma. *J Gastroenterol Hepatol* 1997; 12:392-7.
3. Honma K. Adreno-hepatic fusion. An autopsy study. *Zentralbl Pathol* 1991; 137:117-22.
4. Okuda K. Hepatocellular carcinoma: clinicopathological aspects. *J Gastroenterol Hepatol* 1997; 12 (Suppl):S314-S318.
5. Momoi H, Shimahara Y, Terajima H, et al. Management of adrenal metastasis from hepatocellular carcinoma. *Surg Today* 2002; 32:1035-41.