

# Inflammatory myofibroblastic tumour of the duodenum

Fong SS<sup>1</sup>, MBBS, FRCSE, Zhao C<sup>1</sup>, MBBS, MRCSE, Yap WM<sup>1</sup>, FRACPPath, FAMS, Loke SC<sup>1</sup>, MBChB, FRCR, Lim KH<sup>2</sup>, FRCSE, FAMS

**ABSTRACT** Inflammatory myofibroblastic tumours (IMTs) of the duodenum and head of the pancreas are rare. They are of probable immunological aetiology and preoperatively indistinguishable from adenocarcinomas of the pancreatic head. We describe a patient with duodenal IMT and gastric outlet obstruction, and present a review of pancreatic head and duodenal IMTs in the literature. IMTs of the pancreatic head present as obstructive jaundice, while those of the duodenum present as gastric outlet obstruction. Surgery is the primary modality of treatment. Adjuvant chemotherapy and radiotherapy are controversial and reserved for incomplete resections and IMTs of a pathologically aggressive nature. Otherwise, recurrence is uncommon and surgery curative.

*Keywords:* duodenum, gastric outlet obstruction, inflammatory myofibroblastic tumour, pancreas  
Singapore Med J 2012; 53(2): e28–e31

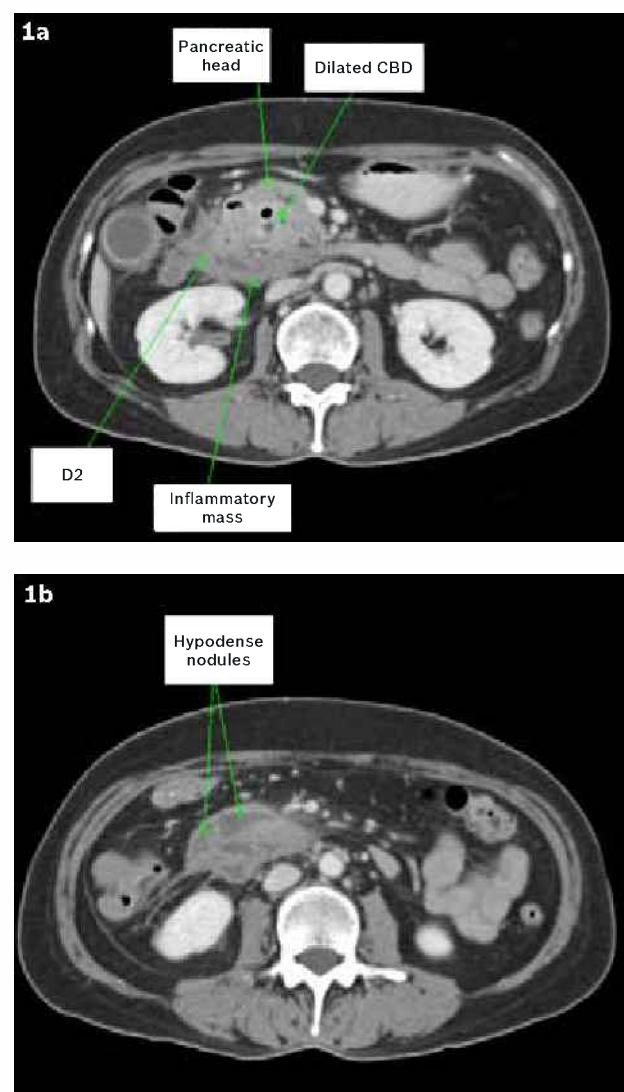
## INTRODUCTION

Inflammatory myofibroblastic tumour (IMT) is an uncommon pathological entity that is usually found in the lung. It rarely involves the pancreatic head or duodenum. This paper discusses the diagnostic and management challenges of this presentation and provides a brief review of the literature.

## CASE REPORT

A 57-year-old healthy Chinese woman presented with acute gastric outlet obstruction without jaundice. Oesophagogastroduodenoscopy revealed a large amount of bilious fluid and food residue in the stomach, which made it impossible to pass beyond the second part of her duodenum. Computed tomography (CT) of the abdomen showed a 3.6 cm × 6.2 cm irregular mass in the second part of the duodenum, the head and uncinate process of the pancreas (Figs. 1a & b). There was no indication of obstruction to the hepatobiliary tract. A water-soluble contrast meal and follow-through demonstrated a stricture at the junction between the second and third part of the duodenum (D2/3). Endoscopic ultrasonography revealed a heterogeneous mass at the pancreatic head abutting against the portal vein, with a dilated common bile duct at 0.9 cm in diameter. Endoscopic fine needle aspiration (FNA) was performed, but this was not diagnostic. All tumour markers were negative (CEA, CA125, CA19-9, AFP).

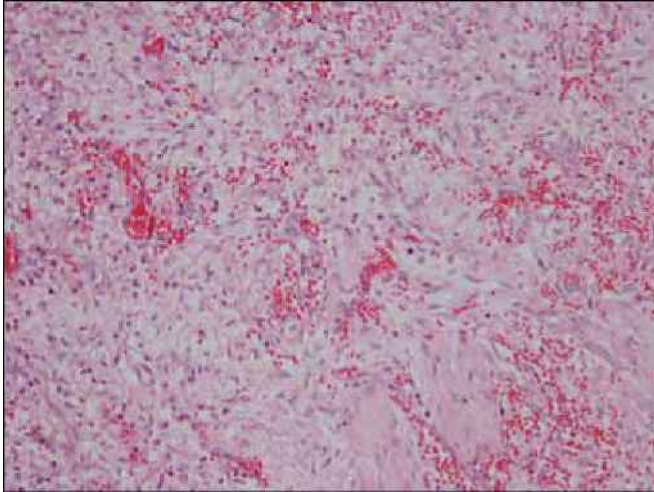
The patient underwent Whipple's operation. This mass was thought to arise from the uncinate process, invading the third part of the duodenum, the transverse mesocolon anteriorly and Gerota's fascia posteriorly. The histology findings were that of a 7 cm × 6 cm × 3 cm haemorrhagic lesion arising from the serosa and muscular wall of the duodenum. Microscopic features were that of a fibroblast-like spindle cell proliferation in the serosa and muscular layer (Fig. 2), with a large component in the periduodenal soft tissue. The lesion extended to involve a portion of the pancreas, Gerota's fascia, colonic serosa and the muscular



**Fig. 1** Computed tomography image shows (a) mass in the region of the third part of the duodenum, the head and uncinate process of the pancreas and (b) surrounding hypodense nodules with enhancing rim, suspicious for inflammatory process.

<sup>1</sup>Tan Tock Seng Hospital, Singapore, <sup>2</sup>Nexus Surgical Associates Pte Ltd, Mount Elizabeth Medical Centre, Singapore

**Correspondence:** Dr Fong Sau Shung, Registrar, Tan Tock Seng Hospital, 11 Jalan Tan Tock Seng, Singapore 308433. fongss@gmail.com



**Fig. 2** Photomicrograph shows spindle cell tumour suggestive of inflammatory myofibroblastic tumour. Proliferation of spindle cells with occasional plasma cells and lymphocytes (Haematoxylin & eosin, x200).

walls of the large arteries. All margins were free of tumour. The lesional cells were negative for CD31, CD34, CD117, caldesmon, beta-catenin (nuclear) and s100, but were positive for calponin and smooth muscle actin. The lesion was thus described as an inflammatory myofibroblastic tumour (Fig. 2). Postoperative recovery was uneventful. The patient remained well, with no evidence of recurrence on surveillance CT for more than two years post procedure.

## DISCUSSION

IMTs have been variously termed as atypical fibromyxoid tumour, pseudosarcomatous fibromyxoid tumour, plasma cell granuloma, pseudosarcomatous myofibroblastic proliferation, postoperative spindle cell nodules and inflammatory pseudotumour. While they are most commonly found as a lesion of the lung (where they have been previously termed as plasma cell granulomas), extra-pulmonary manifestations of IMT are possible, albeit more uncommon.<sup>(1)</sup> The disease can affect virtually any part of the body.<sup>(2)</sup>

The aetiology of IMT is not completely known. The World Health Organization classifies IMTs as tumours of intermediate biological potential, as both local recurrence and systemic metastasis are possible.<sup>(3)</sup> The modern term 'inflammatory myofibroblastic tumour' was first suggested by Pettinato et al,<sup>(4)</sup> based on the finding that myofibroblasts constituted the major component of the lesions; this was observed in a study of 20 inflammatory pseudotumours of the lung. However, the condition could potentially run an aggressive clinical course in keeping with a malignant neoplastic process. An autoimmune process is implicated,<sup>(5)</sup> as well as a viral aetiology.<sup>(2)</sup> Deaths commonly occur due to local invasion rather than distant metastases, and may present in the paediatric age group.<sup>(2)</sup>

Radiological features are mostly indistinguishable from a malignant process.<sup>(6)</sup> Diagnosis is therefore histopathological after biopsy or resection. Our patient had a rare IMT of the duodenum. A literature search on MEDLINE and the

Cochrane database on the terms *inflammatory myofibroblastic tumour*, *atypical fibromyxoid tumour*, *pseudosarcomatous fibromyxoid tumour*, *plasma cell granuloma*, *pseudosarcomatous myofibroblastic proliferation*, *postoperative spindle cell nodules and inflammatory pseudotumour* yielded only 20 case reports (including the present one), where a tumour in the head of the pancreas or within the duodenum were found histologically to be IMT (or similar histology) (Table I).<sup>(7-20)</sup>

There are a few pitfalls in interpreting the data. First, it is uncertain if the histological characteristics of all the tumours described above point to a similar entity, since there is no uniform histopathological diagnostic criteria for IMT. Second, there is a lack of uniformity in management and follow-up among the various patients. The rarity of the tumour precludes a prospective review, and the small numbers precludes a retrospective one. The largest study is a series of six patients with IMT of the pancreatic head by Wreesmann et al.<sup>(16)</sup>

The majority of patients with IMT of the pancreatic head present with jaundice. Newly diagnosed diabetes mellitus was noted in two patients. None of the case reports describing IMT of pancreatic origin has gastric outlet obstruction as a significant presenting feature. Secondary presenting features may include vasculitides and several other autoimmune manifestations.<sup>(19)</sup> On the other hand, duodenal IMTs are much rarer, with only two other cases found in the English literature. In these cases, the patients presented in the paediatric age group with gastric outlet obstruction in one, and pain and night sweats in the other patient.<sup>(8,20)</sup> The only known form of primary treatment for this condition is surgical resection. There is no current acknowledged staging system used for prognostication and management. It is difficult to prognosticate IMT due to the limited literature on the tumour and the absence of a staging system for the disease. The risk of local recurrence is 2%–25%, and systemic metastases do not commonly occur.<sup>(1,2)</sup> The wide difference in local recurrence rates may be secondary to differences in the anatomical site.

Mizukami et al reviewed 25 patients with pancreatic IMTs (including IMT of the body and tail) for autoimmune processes in association with the lesion. In their series, about half of the patients survived for more than five years. However, with regard to local recurrence, in the same review, only one of the 25 patients had recurrence of the condition (at one-year follow-up) after surgical resection.<sup>(19)</sup> Another study by Kovach et al had a recurrence rate of 8% (three out of 44). However, all recurrences in their study occurred in patients who underwent incomplete resection.<sup>(21)</sup>

It would appear that certain histochemical characteristics of atypia, ganglion-like cells, aneuploidy and p53 expression may predict more aggressive behaviour. In fact, IMTs have been known to undergo malignant transformation and metastasise.<sup>(22)</sup> Intra-abdominal rupture of the neoplasm has also been reported to result in seeding of the peritoneal cavity.

Chemoradiation is of limited benefit due to the small risk of recurrence and because acceptable results are generally associated with complete surgical resection. Local recurrences can

**Table 1. Summary of case reports on inflammatory myofibroblastic tumours of the duodenum and the head of the pancreas.**

Author	Age of patient (yrs)	Size of tumour (cm)	Location of tumour	Presentation
Johnson 1983 <sup>(17)</sup>	29	10	Head	Abdominal pain
Stringer 1992 <sup>(65)</sup>	5	7	Duodenum	Gastric outlet obstruction
Uzoaru 1993 <sup>(34)</sup>	8	3	Head	Jaundice
Eckstein 1995 <sup>(20)</sup>	65	Unknown	Head	Chest and back pain
Petler 1998 <sup>(17)</sup>	64	5	Head	Jaundice
Walsh 1998 <sup>(7)</sup>	11	4	Head	Jaundice, abdominal pain
McClain 2000 <sup>(34)</sup>	11	Unknown	Head	Jaundice
Liu 2000 <sup>(14)</sup>	54	5	Head	Abdominal pain
Slavotinek 2000 <sup>(7)</sup>	4	3	Head	Jaundice
Wreesmann 2001 <sup>(16)</sup>	62	3	Head	Jaundice
Wreesmann 2001 <sup>(16)</sup>	56	Unknown	Head	Jaundice, diabetes mellitus
Wreesmann 2001 <sup>(16)</sup>	50	5	Head	Jaundice
Wreesmann 2001 <sup>(16)</sup>	57	Unknown	Head	Jaundice
Wreesmann 2001 <sup>(16)</sup>	45	Unknown	Head	Jaundice
Wreesmann 2001 <sup>(16)</sup>	32	2.5	Head	Jaundice
Yamamoto 2002 <sup>(7)</sup>	55	1.5	Head	Mass, diabetes mellitus
Nakamura 2005 <sup>(8)</sup>	29	6	Head	Abdominal mass, diabetes mellitus
Mizukami 2006 <sup>(19)</sup>	40	7.5	Head	Jaundice, abdominal pain
Wynn 2008 <sup>(20)</sup>	16	6	Duodenum	Abdominal pain, night sweats
Current study	57	7	Duodenum	Gastric outlet obstruction

be managed by a re-laparotomy and surgical resection, with good long-term results in at least one patient.<sup>(23)</sup> Chemoradiotherapy could be considered in patients with incomplete resection of the specimen, or if the specimen is of an aggressive nature. Modalities attempted include radiotherapy, immunosuppressive therapy (with steroids), chemotherapy or a combination. There is some evidence to suggest that non-steroidal anti-inflammatory drugs can shrink the size of IMTs in children,<sup>(24)</sup> and in at least one case, result in regression of disease.<sup>(25)</sup> There is a paucity of evidence for any one regimen for the management of postoperative IMT. Karnak et al<sup>(26)</sup> described a series of seven children with intra-abdominal IMT; six responded well to surgery alone, and one child who had a particularly aggressive form of tumour was post-operatively treated with immunomodulation and chemotherapy, but later succumbed to neutropenic sepsis.

An alternative diagnosis of a non-malignant pancreatic mass is that of tuberculosis. This rare tumour, generally occurring in younger patients within a tuberculosis-endemic zone, is amenable to non-surgical management. Although a positive FNA<sup>(27)</sup> can be diagnostic and radiological characteristics have been described,<sup>(28)</sup> unless they manifest with synchronous active tuberculosis of a separate system, they are rarely diagnosed preoperatively.<sup>(29)</sup>

In conclusion, IMT of the duodenum is rare. Preoperatively, it is virtually impossible to differentiate it from a tumour of the pancreatic head. Tumours of the pancreatic head generally present with obstructive jaundice, whereas duodenal IMTs present with gastric outlet obstruction. Due to concerns of malignancy, as well as to relieve gastric outlet obstruction or obstructive jaundice,

surgical resection with oncological principles is indicated. There is limited evidence for adjuvant chemotherapy. Once the diagnosis is confirmed histologically, in the absence of incomplete resection and parameters of aggressiveness, the prognosis is generally positive and recurrence uncommon.

## REFERENCES

- Coffin CM, Watterson J, Preist JR, Dehner LP. Extrapulmonary inflammatory myofibroblastic tumour (inflammatory pseudotumour). A clinicopathologic and immunohistochemical study of 84 cases. *Am J Surg Pathol* 1995; 19:859-72.
- Gleason BC, Hornick JL. Inflammatory myofibroblastic tumours: where are we now? *J Clin Pathol* 2008; 61:428-37.
- Coffin CM, Fletcher JA. Inflammatory myofibroblastic tumor. In: Fletcher CDM, Unni KK, Mertens F, eds. World Health Organization classification of tumours. Pathology and genetics of tumours of soft tissue and bone. Lyon: IARC Press, 2002: 91-3.
- Pettinato G, Manivel JC, De Rosa N, Dehner LP. Inflammatory myofibroblastic tumour (plasma cell granuloma); Clinicopathologic study of 20 cases with immunohistochemical and ultrastructural observation. *Am J Clin Pathol* 1990; 94: 538-46.
- Mizukami H, Yajima N, Wada R, et al. Pancreatic malignant fibrous histiocytoma, inflammatory myofibroblastic tumour, and inflammatory pseudotumour related to autoimmune pancreatitis: characterization and differential diagnosis. *Virchows Arch* 2006; 448:552-60.
- Kim SJ, Kim WS, Cheon JE, et al. Inflammatory myofibroblastic tumors of the abdomen as mimickers of malignancy: imaging features in nine children. *AJR Am J Roentgenol* 2009; 193:1419-24.
- Johnson RL, Page DL, Dean RH. Pseudotumor of the pancreas. *South Med J* 1983; 76:647-9.
- Stringer MD, Ramani P, Yeung CK. Abdominal inflammatory myofibroblastic tumours in children. *Br J Surg* 1992; 79:1357-60.
- Uzoaru I, Chou P, Reyes-Mugica M, Shen-Schwarz S, Gonzalez-Crussi F. Inflammatory myofibroblastic tumour of the pancreas. *Surg Pathol* 1993; 181-8.

10. Eckstein RP, Hollings RM, Martin PA, Katelaris CH. Pancreatic pseudotumour arising in association with Sjögren's syndrome. *Pathology* 1995; 27:284-8.
11. Petter LM, Martin JK Jr, Menke DM. Localized lymphoplasmacellular pancreatitis forming a pancreatic inflammatory pseudotumour. *Mayo Clin Proc* 1998; 73:447-50.
12. Walsh SV, Evangelista F, Khettry U. Inflammatory myofibroblastic tumour of the pancreaticobiliary region: morphologic and immunocytochemical study of three cases. *Am J Surg Pathol* 1998; 22:412-8.
13. McClain MB, Burton EM, Day DS. Pancreatic pseudotumour in an 11-year old child: imaging findings. *Pediatr Radiol* 2000; 30:610-3.
14. Liu TH, Consorti ET. Inflammatory pseudotumour presenting as a cystic tumour of the pancreas. *Am Surg* 2000; 66:993-7.
15. Slavotinek JP, Bourne AJ, Sage MR, Freeman JK. Inflammatory pseudotumour of the pancreas in a child. *Pediatr Radiol* 2000; 30:801-3.
16. Wreemann V, van Eijck CH, Naus DC, et al. Inflammatory pseudotumour (inflammatory myofibroblastic tumour) of the pancreas: a report of six cases associated with obliterative phlebitis. *Histopathology* 2001; 38:105-10.
17. Yamamoto H, Watanabe K, Nagata M, et al. Inflammatory myofibroblastic tumor (IMT) of the pancreas. *J Hepatobiliary Pancreat Surg* 2002; 9:116-9.
18. Nakamura Y, Inui K, Yoshino J, et al. Inflammatory myofibroblastic tumor (inflammatory fibrosarcoma) of the pancreas: a case report. *Hepatogastroenterology* 2005; 52:625-8.
19. Mizukami H, Yajima N, Wada R, et al. Pancreatic malignant fibrous histiocytoma, inflammatory myofibroblastic tumor, and inflammatory pseudotumor related to autoimmune pancreatitis: characterization and differential diagnosis. *Virchows Arch* 2006; 448:552-60.
20. Wynn GR, Giles A, Steger AS, Wilkinson ML. Case report: inflammatory myofibroblastic tumor of the duodenum. *J Gastrointest Cancer* 2008; 39:79-81.
21. Kovach SJ, Fischer AC, Katzman PJ, et al. Inflammatory myofibroblastic tumours. *J Surg Oncol* 2006; 94:385-91.
22. Kim KA, Park CM, Lee JH, et al. Inflammatory myofibroblastic tumour of the stomach with peritoneal dissemination in a young adult: imaging findings. *Abdom Imaging* 2004; 29:9-11.
23. Hamidah A, Khu SY, Thambidorai CR, et al. Recurrent gastric inflammatory myofibroblastic tumour in a 13 year old male. *Pediatr Surg Int* 2007; 23:601-3.
24. Applebaum H, Kieran MW, Cripe TP, et al. The rationale for nonsteroidal anti-inflammatory drug therapy for inflammatory myofibroblastic tumours: a Children's Oncology Group study. *J Pediatr Surg* 2005; 40:999-1003.
25. Przkora R, Bolder U, Schwarz S, et al. Regression of nonresectable inflammatory myofibroblastic tumours after treatment with nonsteroidal anti-inflammatory drugs. *Eur J Clin Invest* 2004; 34:320-1.
26. Karnak I, Senocak ME, Ciftci AO, et al. Inflammatory myofibroblastic tumour in children: diagnosis and treatment. *J Pediatr Surg* 2001; 36:908-12.
27. Kumar R, Kapoor D, Singh J, Kumar N. Isolated tuberculosis of the pancreas: a report of two cases and review of the literature. *Trop Gastroenterol* 2003; 24:76-8.
28. De Backer AI, Mortelé KJ, Bomans P, et al. Tuberculosis of the pancreas: MRI features. *AJR Am J Roentgenol*. 2005; 184:50-4.
29. Saluja SS, Ray S, Pal S, et al. Hepatobiliary and pancreatic tuberculosis: a two decade experience. *BMC Surg* 2007; 7:10.