

# Medium-term results of ultrasonography-guided, catheter-assisted foam sclerotherapy of the long saphenous vein for treatment of varicose veins

Tan VKM<sup>1</sup>, MBBS, MMed, Abidin SZ<sup>1</sup>, MBBS, Tan SG<sup>1</sup>, FRCS, FAMS

**INTRODUCTION** We previously reported our technique of ultrasonography-guided, catheter-assisted foam sclerotherapy of the long saphenous vein for treatment of primary varicose veins. In this study, we present the technical results, based on follow-up duplex images, and patient-reported symptom improvement and satisfaction.

**METHODS** All patients treated with ultrasonography-guided, catheter-assisted foam sclerotherapy between March 2006 and August 2007 were included in this review. Prospectively collected clinical data and follow-up postoperative duplex examinations at one day, six months and 12 months were reviewed. Telephone interviews with a standard questionnaire were conducted.

**RESULTS** During the study period, 66 lower limbs in 62 patients were treated using the described technique. The median follow-up period was 12 months (range one day to 38 months). Successful occlusion rate was 98% at six months and 80% at 12 months for patients who attended follow-up duplex imaging. Seven patients underwent a second procedure. Patient satisfaction was good, with 96% reporting symptom improvement.

**CONCLUSION** Ultrasonography-guided, catheter-assisted foam sclerotherapy is safe, minimally invasive and yields good medium-term occlusion rates of the treated veins.

*Keywords: catheter-guided foam sclerotherapy, varicose veins*  
*Singapore Med J 2012; 53(2): 91-94*

## INTRODUCTION

Varicose veins are a common disorder and an estimated 15% of men and 25% of women suffer symptoms from varicose veins.<sup>(1)</sup> Many treatment options are currently available. These include compression hosiery, surgical ligation of the saphenofemoral junction (SFJ) with stripping of the long saphenous vein (LSV), and minimally invasive procedures such as radio frequency ablation (RFA), endovenous laser ablation and sclerotherapy. The use of sclerosants in a foamed form has been shown to be superior to liquid sclerosant, largely because foam more effectively displaces blood and creates an increased effective surface area of contact between the sclerosant and endothelium.<sup>(2)</sup>

We recently reported a technique of foam sclerotherapy for treatment of primary varicose veins.<sup>(3)</sup> This technique was developed due to an increase in demand for an inexpensive, minimally invasive yet effective treatment for primary varicose veins among our local population. Our technique comprised the use of a vascular catheter to deposit foam sclerosant evenly throughout the LSV. The procedure was performed under ultrasonography guidance with a local anaesthetic. This study reports the medium-term outcome of this technique.

## METHODS

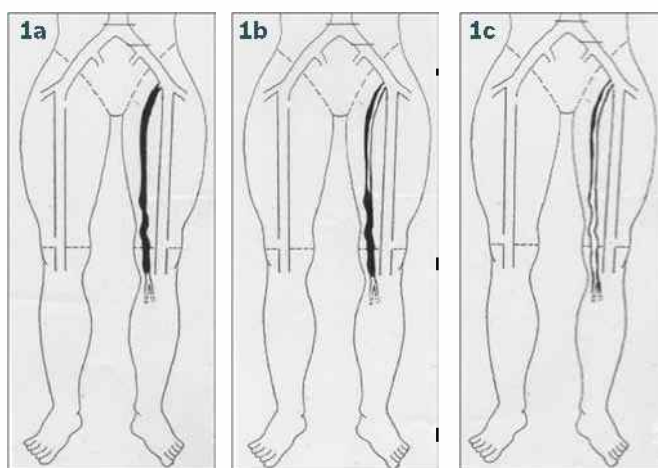
Approval from the hospital's Institutional Review Board was obtained before we reviewed the use of this technique. Only patients with an incompetent SFJ and reflux down the LSV, as

determined by a handheld continuous wave Doppler device, were eligible to participate in this study. The patients had no prior interventions to the SFJ or LSV and were offered the option of foam sclerotherapy if they were deemed unfit for surgery or preferred a minimally invasive intervention. Absolute contraindications included a known allergy to the sclerosant, acute superficial thrombosis or a history of deep venous thrombosis, severe systemic illness, a patent foramen ovale or pregnancy. Informed consent was obtained from each patient. All patients who underwent our described technique of ultrasonography-guided, catheter-assisted foam sclerotherapy between March 2006 and August 2007 were included in this study.

All patients had foam sclerotherapy performed by a single consultant vascular surgeon using our institution's original technique of ultrasonography-guided, catheter-assisted foam sclerotherapy.<sup>(3)</sup> Briefly, the procedure was performed with the use of a local anaesthetic under aseptic conditions. Real-time ultrasonographic guidance was used throughout. The SFJ was identified by ultrasonography and occluded by digital pressure provided by an assistant. A size 8 sterile latex glove was used as a tourniquet and applied below the knee, allowing for distension of the LSV. The LSV was then accessed 5–10 cm below the knee using a Micropuncture Access Set (Cook MPIS-401-U, Bloomington, IN, USA). A J tipped guide wire (Diomed Inc, Andover, MA, USA) was inserted and a 5-Fr 0.038" Headhunter vascular catheter (Terumo Corporation, Tokyo, Japan) was advanced over the wire guide such that the tip of the catheter was positioned 1 cm distal to the SFJ.

<sup>1</sup>Department of General Surgery, Singapore General Hospital, Singapore

**Correspondence:** Dr Veronique Tan, Registrar, Department of General Surgery, Singapore General Hospital, Outram Road, Singapore 169608. vquetan@gmail.com



**Fig. 1** Pictorial depiction of venous ultrasonographic outcomes of the long saphenous vein (LSV) shows (a) thrombosed LSV; (b) partially recanalised LSV; and (c) fully recanalised (patent) LSV.

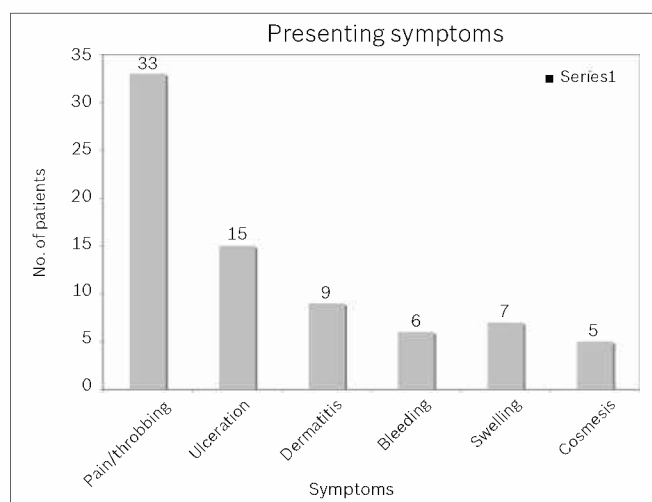
**Table 1. Demographic data of patients and the treated veins.**

Demographic	Value
No. of patients	62
No. of legs	66
Median age; range (yrs)	59; 29–78
Male	18
Female	44
Median diameter of LSV; range (mm)	7.6; 4–13.4

LSV: long saphenous vein

The patients were then placed in a Trendelenburg position, and their limb was elevated. Foam sclerosant was prepared using the Tessari method with 3% sodium tetradecyl sulphate to air in a ratio of 1:3.<sup>4</sup> Depending on the size of the LSV, 4–12 ml of foam was used. The foam sclerosant was injected into the Headhunter catheter as the catheter was withdrawn. Sonographic visualisation of the echogenic foam bubbles allowed for adequate, uniform deposition of foam sclerosant within the LSV. Gentle pressure exerted with the ultrasonography probe facilitated an even distribution of the foam sclerosant. Pressure packs were applied at the SFJ, and firm crepe bandaging of the lower limb was performed after removal of the Headhunter catheter. The patients were then instructed to ambulate for 30 minutes prior to discharge, in order to encourage flow within the deep venous system of the lower limb. Patients exchanged the lower limb bandages for compression hosiery the following day and were advised to wear these continually for one month post procedure. This maximises compression of the LSV to promote lasting luminal occlusion.

All patients were scheduled for a venous duplex assessment a day after the procedure. The venous duplex imaging was performed by certified vascular technologists at our institution's vascular studies unit. The imaging served to exclude acute thrombosis of the deep veins and evaluated the extent of thrombosis of the LSV. Outpatient clinical review included physical examination and patient feedback on improvement in symptoms. Patients also had repeat venous duplex evaluation at six, 12 and 18 months or when indicated, in order to assess technical success of foam sclerotherapy of the LSV. Complete



**Fig. 2** Graph shows the presenting symptoms of varicose veins.

occlusion was defined as occlusion of the entire length of the treated LSV, and included both an entirely thrombosed LSV or an obliterated, vestigial LSV. Thrombosed veins that had a recanalised segment, usually from a junction with the deep vein, but had complete luminal occlusion at some point and did not allow antegrade or retrograde flow, were classified as partially recanalised. A fully recanalised vein had a patent lumen evident on the duplex imaging and allowed for either antegrade or retrograde flow (Fig. 1).


Telephone interviews with the patients were performed by one author (SZA) using a standard questionnaire. These were conducted between September and November 2009 in order to establish the subjective outcomes of symptom improvement and patient satisfaction with the procedure.

## RESULTS

From March 2006 to August 2007, a total of 66 legs in 62 patients were treated by this technique of foam sclerotherapy. There were 18 male and 44 female patients aged 29–78 years. The median diameter of the LSV was 7.6 (range 4–13.4) mm (Table 1). The most common presenting symptom among our patients was pain – a cramping and throbbing discomfort with prolonged standing. This was present in 33 patients. The other symptoms for which our patients sought treatment included lower limb ulceration, bleeding varicosities, dermatitis, visible varicosities and leg swelling (Fig. 2).

All patients attended venous duplex evaluation the day after the procedure. Ten patients (13 legs) did not attend the follow-up after the first venous ultrasonography. The median follow-up for this cohort was 12 months. Several patients defaulted planned follow-up, and not every patient who attended follow-up was agreeable to a repeat duplex evaluation. Only 38 legs underwent repeat duplex assessment at six months. At 12 months, only 34 limbs were evaluated with venous duplex imaging (Fig. 3). Most patients were reluctant to undergo further imaging, as their symptoms were already alleviated.

All patients had a duplex imaging done on the day after foam sclerotherapy to assess the technical success of LSV thrombosis



**Fig. 3** Flowchart shows a summary of ultrasonography duplex outcomes of treated veins on postoperative Day 1, and at six and 12 months.

as well as to exclude deep venous thrombosis. As previously reported, 62 of the 66 treated veins were completely thrombosed. Four treated veins had partial thrombosis, but retrograde flow was demonstrated. The immediate success rate of the procedure was thus 94%. These four patients were offered a repeat treatment with foam sclerotherapy. Three of the four patients underwent a second injection of foam sclerosant with resultant complete obliteration of the vein, while one patient declined a repeat procedure. 38 patients (38 legs out of a possible 49 that reached six-month follow up) attended venous duplex imaging at six months. The LSV was occluded in 28 (74%) legs, partially recanalised in nine (24%) legs and patent in one (2%) leg. 34 legs were scanned at 12 months, of which 19 (56%) legs had an occluded LSV and partial recanalisation was noted in 8 limbs (24%). Seven (20%) legs had a patent LSV. A total of seven patients underwent a repeat procedure. Six patients had repeat foam sclerotherapy injections to the LSV. One patient underwent endovascular laser therapy (EVLT).

Fifty patients responded to our telephone interview. All were able to recollect their experience of injection foam sclerotherapy and were forthcoming with their feedback. The majority of patients (96%) reported an improvement in symptoms. In a semi-quantitative fashion, 33 (66%) patients reported > 50% improvement, while 15 (30%) patients reported < 50% amelioration. Only two patients felt that the procedure provided no benefit. Our patients were also asked to report on overall satisfaction, taking into account all factors, including the convenience of the day-procedure, symptom-relief, complication(s) experienced and cost. Satisfaction was subjectively categorised as 'excellent', 'good', 'average' and 'poor'. 14 (28%) patients considered foam sclerotherapy to be an excellent treatment option, while 27 (54%) thought it was good, and nine (18%) patients subjectively deemed the procedure to be average. No patient thought that it was a poor intervention.

Adverse effects arising from the procedure developed early. In our series, five patients developed thrombosis within the deep venous system. All five patients were asymptomatic, and diagnosis was based on the routine post-procedural duplex

imaging done one day after foam sclerotherapy. One patient with complete thrombosis of the deep vein underwent thrombectomy. All received anticoagulation, and ultrasonic resolution of deep vein thrombosis was noted in all five patients by three months. Minor complications were encountered in the immediate post-procedural period, as reported in our first publication.<sup>(3)</sup> These included superficial thrombophlebitis (7.6%), skin pigmentation (6.1%) and cellulitis (1.5%). None of our patients reported blurring of vision or nerve injury.

## DISCUSSION

Primary lower limb varicose veins develop as a result of valvular insufficiency with reflux down the LSV. Surgery with SFJ ligation and LSV stripping with avulsions is still the gold standard therapeutic option. For patients who are not fit for surgery or unwilling to undergo an open operation, minimally invasive options include RFA, EVLT and foam sclerotherapy. These procedures help to abolish varicose veins by inducing thrombosis, resulting in obliteration of the lumen of the LSV. Locally, EVLT has gained much popularity, primarily because it is a day-procedure performed under local anaesthesia. However, the high cost of the procedure is prohibitive to a population of patients. Foam sclerotherapy is a cheaper alternative. We have developed a method of instilling foamed sclerosant within the LSV using real-time ultrasonography guidance and the placement of a Headhunter catheter within the LSV. This method allows for the precise deposition of foam throughout the entire length of the vein. This report is an update on the medium-term outcome of our technique.

The results of duplex imaging categorised the treated veins as those that are occluded, partially recanalised and patent. Veins that are partially recanalised have a segment that is not thrombosed, but complete luminal obliteration is still present at a segment within the LSV. No antegrade or retrograde flow is demonstrated in these partially recanalised veins, and we consider them a technical success. Among the legs that were assessed with duplex imaging at six months, 98% retained luminal obliteration. This proportion decreased to 80% among those who had duplex imaging at 12 months. A recent meta-analysis on the effectiveness of endovenous therapies for lower limb varicosities found the pooled success rate of ultrasonography-guided foam sclerotherapy to be 80.9% (95% CI 71.8%–87.6%) at one year.<sup>(5)</sup> The known occlusion rate achieved by our method of foam sclerotherapy is thus comparable to other methods of foam sclerotherapy described.

We have reported the anatomic occlusion rate of this cohort of patients, which provides an objective account of our results. However, a limitation of this report is the high dropout rate; ten (20% of treated limbs) patients defaulted follow-up after the first postoperative ultrasonography, and only 38 of the 49 limbs being followed up at six months were imaged. It may have been that the patients stopped attending the clinic because they experienced symptomatic improvement. Several patients

declined a repeat duplex ultrasonography, as they had become asymptomatic. We recognise that these results reflect only the outcomes of the proportion of patients who agreed to undergo a repeat duplex ultrasonography at one year. The high incidence of default also precludes meaningful assessment of recurrence in the long term, an event that commonly occurs in all treatments for varicose veins. The five-year recurrence rate after surgery has been reported to be 25%–39%, while recurrence after treatment by EVLT and RFA at five years has been reported to be 5% and 20%, respectively.<sup>(5,6)</sup> One way to better evaluate our outcomes after foam sclerotherapy would be to conduct a prospective randomised trial, comparing this treatment method with other treatment modalities. Such a study would allow for comparison of effectiveness and risks, and cost analysis may also be performed. A prospective randomised trial is being planned at our institution, and we hope that follow-up with interval imaging at no charge to the patients would address the issue of dropouts.

Treatment of varicose veins aims mainly to alleviate the patients' symptoms. Patient feedback and satisfaction is thus an important aspect in the evaluation of the treatment. Most of our patients presented with pain in the lower limbs. Other presenting symptoms included dermatitis, bleeding varicosities, lower limb swelling and venous ulceration. During follow-up clinic attendance, the patients were asked to provide feedback on clinical improvement, but many had difficulty quantifying the degree of symptom improvement. The semi-quantitative measure of improvement, where patients graded improvement as either 'greater than 50%' or 'less than 50%' used in our questionnaire was suggested by a patient, and we found that subsequent patients could provide such an indication of improvement with ease. This was especially so in our local context where patients speak various languages and dialects. We thus adopted this measurement in assessing subjective improvement during the telephone interview. We noted that the majority (96%) of patients had improvement in symptoms after foam sclerotherapy, with most (66%) reporting a significant 'greater than 50%' improvement. Patient-reported overall satisfaction was also high, with 82% indicating that it was good or excellent. As a pilot study, we felt that these parameters provided adequate subjective feedback from our patients, although we concede that more structured surveys using validated questionnaires to ascertain the

precise degree of improvement in quality of life would provide more robust feedback. The other subjective outcomes that we hope to evaluate in future studies include postoperative pain, analgesia use and time to return to normal activity.

There is a low complication rate with our method of instilling a foamed sclerosant into the LSV. Immediate minor complications include superficial thrombophlebitis (7.6%), skin pigmentation (6.1%) and cellulitis (1.5%). These local complications were likely due to the inflammatory effect of the sclerosant, and effective symptomatic relief was effected with oral anti-inflammatory agents with minimal patient distress. Deep vein thrombosis is known to occur with all endovenous therapies, and five patients in this series were affected. All five patients were asymptomatic and diagnosed at the post-procedural duplex imaging done one day after the treatment. They received prompt treatment with anticoagulation and have no long-term sequelae to date. No instance of pulmonary embolism, visual deficit or stroke was encountered by our patients.

In conclusion, we have developed a technique of precisely instilling foamed sclerosant into the LSV for treatment of primary varicose veins. It is cheaper than other current endovenous therapies, causes minimal discomfort and has since shown good medium-term results among patients who presented for follow-up. Almost all patients reported an improvement in their symptoms after the treatment, and the overall patient satisfaction was good.

## REFERENCES

1. Callam MJ. Epidemiology of varicose veins. *Br J Surg* 1994; 81:167-73.
2. Yamaki T, Nozaki M, Iwasaka S. Comparative study of duplex-guided foam sclerotherapy and duplex-guided liquid sclerotherapy for the treatment of superficial venous insufficiency. *Dermatol Surg* 2004; 30:718-22; discussion 722.
3. Tan VK, Tan SG. Technique and early results of ultrasound-guided foam sclerotherapy of the long saphenous vein for treatment of varicose veins. *Singapore Med J* 2009; 50:284-7.
4. Tessari L, Cavezzi A, Frullini A. Preliminary experience with a new sclerosing foam in the treatment of varicose veins. *Dermatol Surg* 2001; 27:58-60.
5. van den Bos R, Arends L, Kockaert M, Neumann M, Nijsten T. Endovenous therapies of lower extremity varicosities: a meta-analysis. *J Vasc Surg* 2009; 49:230-9.
6. Dwerryhouse S, Davies B, Harradine K, Earnshaw JJ. Stripping the long saphenous vein reduces the rate of reoperation for recurrent varicose veins: five-year results of a randomized trial. *J Vasc Surg* 1999; 29:589-92.