

# Proliferating tricholemmal tumour: clinicopathological aspects of a case

Khoja A A, Yan B, Lee S J, Cheong E C, Tan K B

## ABSTRACT

We report the case of a 49-year-old man who presented with an enlarging mass over his occipital scalp. The clinical impression was either a squamous cell carcinoma or an unusual adnexal tumour. A wide excision was performed with skin grafting. Gross examination revealed a large exophytic tumour mass measuring 10 cm. Histopathological examination showed a circumscribed, well-differentiated squamoproliferative lesion with a lobulated architecture. Clear cell features, pilar-type keratinisation, microcalcifications and the presence of mucinous degeneration were noted. A diagnosis of proliferating tricholemmal tumour was made. This entity incorporates a spectrum of lesions, ranging from the mostly benign proliferating tricholemmal cyst to tumours having more atypical cellular and invasive features, the latter features correlating with an increased capacity for aggressive behaviour. Management-wise, such tumours require complete excision with follow-up. As the tumours are often large in size at presentation, reconstruction is required.

**Keywords:** adnexal and skin appendage neoplasms, pillar cyst, reconstructive surgical procedures, skin neoplasms

*Singapore Med J 2011; 52(12): e255-e257*

## INTRODUCTION

Proliferating tricholemmal tumour (PTT) is a rare tumour of the skin, which is more common in adults and the elderly. The tumour has a female preponderance and is mostly seen in the scalp region (90%), with occurrences on the face, trunk, back and forehead in decreasing order of frequency.<sup>(1)</sup> PTT typically presents as a solitary large exophytic mass featuring a solid-cystic multi-lobulated morphology. The tumour is derived from the outer sheath of the hair follicle. Benign mimics of the tumour include epidermal or tricholemmal cyst, while malignant mimics mainly comprise squamous cell carcinoma (SCC) and tricholemmal carcinoma. While most of these tumours

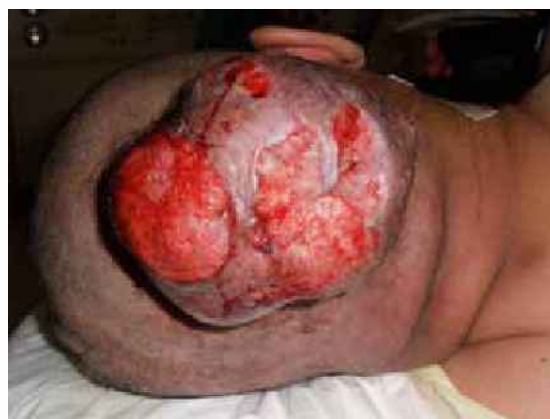

Fig. 1 Photograph shows a large exophytic scalp tumour mass.

have a benign outcome following complete excision, a subset of them exhibits biologically unpredictable behaviour.

We present a case of PTT displaying many of the characteristic clinicopathological features, while highlighting an unusual finding of prominent mucinous degeneration. We also briefly review the range of behaviour and treatment of this tumour.

## CASE REPORT

A 49-year-old Malay man with no remarkable medical or family history presented with an enlarging mass over his occipital scalp (Fig. 1). A clinical diagnosis of SCC or unusual adnexal tumour was suspected. The patient underwent complete excision of the tumour with clear margins and skin grafting. Gross examination revealed a large exophytic mass measuring 10.0 cm × 8.0 cm × 6.0 cm and weighing 694 g. The tumour appeared to be greater than 1 cm from the deep resection margin and peripheral margins. A cut surface of the mass showed a well-circumscribed, lobulated and tan-coloured appearance with no obvious areas of necrosis or haemorrhage (Fig. 2).

Histopathologically, the tumour was composed of lobules of squamous cells with clear cell change and tricholemmal-type (pilar) keratinisation (Figs. 3 & 4). Multinucleated giant cells and foci of dystrophic calcification were present. There was minimal cytologic atypia; mitotic activity was low and confined to the basal cellular layers of the tumour lobules. The well-

Sindh Medical College,  
Dow University of Health Sciences,  
Baba-E-Urdu Road,  
Karachi 74200,  
Pakistan

Khoja AA  
Final-year MBBS Student

Department of Pathology,  
Yong Loo Lin School of Medicine  
National University Health System,  
Lower Kent Ridge Road,  
Singapore 119074

Yan B, MBBS  
Registrar

Tan KB, FRCPATH,  
FRCPA, Dip Dermatopathology  
Senior Consultant and Associate Professor

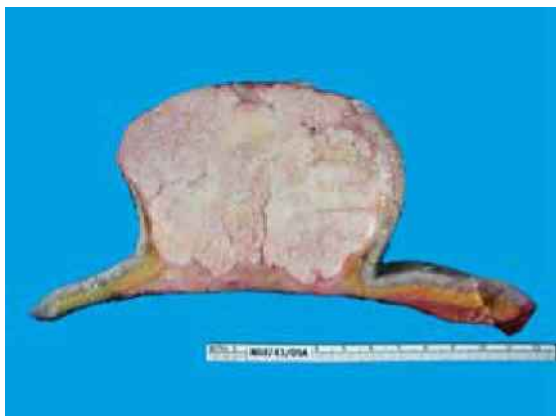Division of Aesthetic, Plastic and Reconstructive Surgery,  
Department of Surgery

Lee SJ, MMed, MRCSE, MD  
Consultant

Department of General Surgery,  
Tan Tock Seng Hospital,  
11 Jalan Tan Tock Seng,  
Singapore 308433

Cheong EC, MBBS, MMed, MRCSE  
Consultant

Correspondence to:  
Dr Kong-Bing Tan  
Tel: (65) 6772 2057  
Fax: (65) 6778 0671  
Email: pattankb@nus.edu.sg



**Fig. 2** Photograph of the cut surface of gross pathological specimen shows a solid tumour mass centered in the dermis.

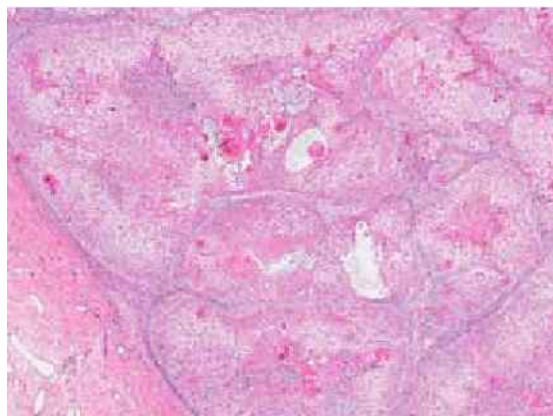
circumscribed tumour had a pushing-type tumour front. Foci of mucinous change were noted within the tumour, which were highlighted with the Alcian-blue stain (at pH 2.5). A mixed acute-on-chronic inflammatory infiltrate, composed of neutrophils, lymphocytes and histiocytes, was present in the surrounding dermis.

## DISCUSSION

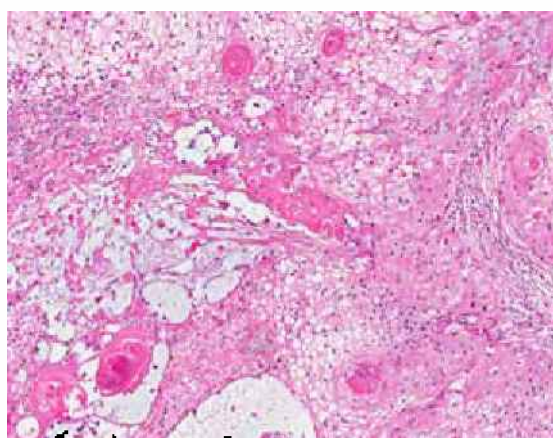
PTT is an uncommon cutaneous neoplasm that has been a subject of interest in the dermatology literature for many years due to its unpredictable behaviour and similarity with SCC.<sup>(2)</sup> It is also known as a proliferating tricholemmal cyst or pilar tumour of the scalp.<sup>(3)</sup> The typical age of patients with PTT is 54–83 years, with the mean age being 65 years.<sup>(2)</sup> The tumour may arise in a tricholemmal or pilar cyst that has been present for many years. PTT can grow to a very large size of up to 25 cm.<sup>(4)</sup> It enlarges slowly and can be painful. It can also ulcerate, bleed or produce a purulent discharge. The histopathological features of the current case are archetypical of this tumour. An unusual feature in our patient was the presence of mucinous change, which is degenerative in nature. Although such change is well reported in other cutaneous tumours, e.g. basal cell carcinoma, to the best of our knowledge, it has not been reported in PTTs.

The presence of marked keratinisation, pilar-type keratinisation, minimal nuclear pleomorphism, low mitotic activity, sharp circumscription, dystrophic calcification and absence of a premalignant lesion such as actinic keratosis helps to differentiate PTT from SCC.<sup>(4,5,6)</sup> PTT must also be distinguished from tricholemmal carcinoma. The presence of circumscribed borders and the absence of cellular atypia are useful features that mark the presence of PTT.

Atypical histopathological features may predict more aggressive tumour behaviour. In the series by Ye



**Fig. 3** Photomicrograph shows a circumscribed squamous tumour with lobulated architecture (Haematoxylin & eosin, × 20).



**Fig. 4** Photomicrograph shows tumour cells with clear cytoplasm, tricholemmal keratinisation and prominent mucinous change (left side) (Haematoxylin & eosin, × 70).

et al, PTTs without invasion and atypia, which are the features exemplified in our case, behaved in a benign manner, while 15% of tumours with invasive features but without atypia, necrosis or abnormal mitoses had local recurrences following excision. Tumours with invasion as well as nuclear atypia, abnormal mitoses or geographical necrosis had a 50% chance of developing recurrence or lymph nodal metastases.<sup>(7)</sup> A tumour with the latter characteristics can be regarded as a malignant PTT and is likely to behave in a manner similar to SCC and tricholemmal carcinoma. Distant metastases have been reported in cases of malignant PTT.<sup>(6)</sup>

In conclusion, patients with PTT require complete excision with clear margins and clinical follow-up. Local tumour recurrence is treated with re-excision, and malignant tumours may require adjuvant chemotherapy and radiation therapy.<sup>(7,8)</sup>

## REFERENCES

1. Brownstein MH, Arluk DJ. Proliferating trichilemmal cyst: a simulant of squamous cell carcinoma. *Cancer* 1981; 48:1207-14.
2. Folpe AL, Reizenauer AK, Mentzel T, Rütten A, Solomon AR.

- Proliferating trichilemmal tumors: clinicopathologic evaluation is a guide to biologic behavior. *J Cutan Pathol* 2003; 30:492-8.
3. Janitz J, Wiedersberg H. Trichilemmal pilar tumors. *Cancer* 1980; 45:1594-7.
  4. Headington JT. Tumors of the hair follicle. A review. *Am J Pathol* 1976; 85:480-514.
  5. Amaral AL, Nascimento AG, Goellner JR. Proliferating pilar (trichilemmal) cyst. Report of two cases, one with carcinomatous transformation and one with distant metastases. *Arch Pathol Lab Med* 1984; 108:808-10.
  6. Park BS, Yang SG, Cho KH. Malignant proliferating trichilemmal tumor showing distant metastases. *Am J Dermatopathol* 1997; 19:536-9.
  7. Ye J, Nappi O, Swanson PE, Patterson JW, Wick MR. Proliferating pilar tumors: a clinicopathologic study of 76 cases with a proposal for definition of benign and malignant variants. *Am J Clin Pathol* 2004; 122:566-74.
  8. Weiss J, Heine M, Grimm M, Jung EG. Malignant proliferating trichilemmal cyst. *J Am Acad Dermatol* 1995; 32:870-3.