

# Effect of vitamin E administration on histopathological changes in rat testes following torsion and detorsion

Ranade A V, Tripathi Y, Rajalakshmi R, Vinodini N A, Soubhagya R N, Nayanatara A K, Rekha D K, Kumari M

Department of Anatomy,  
Gulf Medical College,  
PO Box 4184,  
Ajman,  
United Arab Emirates

Ranade AV, PhD  
Assistant Professor  
and Research Assistant

Department of Physiology,  
Santhosh Medical College,  
Maliwara,  
Nehru Nagar II,  
Ghaziabad 201001,  
Uttar Pradesh,  
India

Tripathi Y, MBBS,  
MS, PhD  
Professor

Department of Anatomy,  
Centre for Basic Sciences,  
Kasturba Medical College  
(Unit of Manipal University),  
Mangalore 575004,  
Karnataka,  
India

Rajalakshmi R, PhD  
Selection Grade Lecturer

Department of Physiology

Vinodini NA, PhD  
Associate Professor

Rekha DK, PhD  
Selection Grade Lecturer

Nayanatara AK, PhD  
Selection Grade Lecturer

Department of Anatomy,  
College of Medicine  
and JNM Hospital,  
West Bengal  
University of Health Sciences,  
Kalyani PO,  
Nadia 741235,  
West Bengal,  
India

Soubhagya RN, PhD  
Assistant Professor

## ABSTRACT

**Introduction:** Testicular torsion is a medical emergency, especially in male neonates and adolescents. It is a common clinical outcome and a significant urological issue. From the literature, it is evident that the use of antioxidants in the prevention of testicular reperfusion injury following detorsion is conflicting. This study was conducted to investigate the role of vitamin E in testicular reperfusion injury following detorsion.

**Methods:** Male Wistar albino rats were divided into Groups I, II, III and IV. Only Group IV rats were pre-treated with vitamin E 100 mg/kg body weight for 30 days. Ischaemia was induced manually by rotating the rat testis to 720 degrees clockwise and counter rotating for reperfusion. The testes were fixed in Bouin's fluid and processed for histopathological examination.

**Results:** A significant decrease in the standard tubular diameter and epithelial height was observed in Group III rats compared to those in Groups I and II. However, the seminiferous tubules in Group IV rats showed recovery in the standard tubular diameter and epithelial height when compared with the untreated control groups.

**Conclusion:** The results showed that vitamin E, when administered before torsion of the spermatic cord in rats, provided significant protection against acute testicular torsion and detorsion injury.

**Keywords:** ischaemia, reperfusion, testicular torsion, testis

*Singapore Med J 2011; 52(10): 742-746*

## INTRODUCTION

Testicular torsion is a medical emergency and a source of morbidity, especially in children and adolescent males.<sup>(1)</sup> Despite immediate interventions by manual

or surgical detorsion, there exists a possibility of impaired fertility.<sup>(2)</sup> Rotation of the testis and torsion of the spermatic cord lead to interference of its vascular mechanism, resulting in testicular ischaemic injury, including germinal cell loss, aspermatogenesis and testicular atrophy.<sup>(3)</sup> Antioxidants protect sperms from damage caused by reactive oxygen species (ROS), and oxygen radical scavengers have prevent effects on testicular function after acute experimental torsion, thus suggesting that antioxidants act as a factor for survival and ensure germ cell function.<sup>(4)</sup> The role of the antioxidant enzymatic defence system against ROS-induced injury following ischaemia and reperfusion has been studied by administering antioxidants such as allopurinol, superoxide dismutase (SOD), surfactant and catalase (CAT) exogenously.<sup>(5)</sup>

Akgür et al reported that pre-treatment with allopurinol before detorsion of the spermatic cord prevents reperfusion injury in rat models.<sup>(5)</sup> Prillaman and Turner reported a significant decrease in testicular reperfusion injury in rats that were subjected to one hour of torsion with SOD and CAT. However, they did not find any significant decrease in animals that were subjected to two hours of torsion.<sup>(6)</sup> Prevention of reperfusion injury using a combination of enzymes and drugs has been studied along with the assessment of histopathological changes after testicular torsion, but no consensus on standard therapy has been reached.<sup>(7,8)</sup>

Alpha ( $\alpha$ )-tocopherol (vitamin E) is one of eight forms of vitamin E.<sup>(9)</sup> Its cell membranes and plasma lipoproteins contain  $\alpha$ -tocopherol, a lipid-soluble molecule that functions as a chain-breaking antioxidant.<sup>(10)</sup> Vitamin E is widely available in the market in the oral form. Experiments on laboratory animals have shown that increased intake of vitamin E leads to the generation of fewer toxic free radicals. However, in vitamin E-deficient rats, free radical production increases during ischaemic re-oxygenation.<sup>(11,12)</sup> Few studies have been conducted on ischaemia or reperfusion injury using vitamin E. Therefore, the present study was designed to address the issue of testicular reperfusion

Department of Anatomy,  
International  
Medical University,  
126, Jalan Jalil  
Perkasa 19,  
Bukit Jalil,  
Kuala Lumpur  
57000,  
Malaysia

Kumari M, Msc  
Lecturer

Correspondence to:  
Dr Anu V Ranade  
Tel: (971) 6 743 1333  
Fax: (971) 6 743 1222  
Email: anuranade@gmail.com

**Table I. Effects of three hours of ischaemia followed by one hour of reperfusion on STD and SEH.**

Group	Mean Group $\pm$ SD	
	STD ( $\mu$ m)	SEH ( $\mu$ m)
I (n = 8)	597.51 $\pm$ 28.4	75.14 $\pm$ 9.38
II (n = 8)	561.76 $\pm$ 38.5*	76.35 $\pm$ 4.60*
III (n = 8)	450.42 $\pm$ 66.2 <sup>†</sup>	34.54 $\pm$ 7.83 <sup>†</sup>
IV (n = 8)	518.72 $\pm$ 45.89 <sup>‡</sup>	64.84 $\pm$ 7.57 <sup>‡</sup>

\* Group I vs. Group II: p-value is not significant

<sup>†</sup> Group III vs. Group I & II: p-value < 0.0001<sup>‡</sup> Group IV vs. Group III: p-value < 0.0001

SD: standard deviation; STD: standard tubular diameter; SEH: standard epithelial height

**Table II. Microscopically demonstrable changes in the seminiferous tubules in the animals that had undergone torsion and counter-rotation in the four groups.**

Group	Grade
I	Grade 0: Normal testicular architecture with an orderly arrangement of germinal cells. Absence of coagulation and necrosis in the seminiferous tubules.
II	Grade 0: Normal testicular architecture with an orderly arrangement of germinal cells with absence of coagulation and necrosis in the seminiferous tubules.
III	Grade 3: Seminiferous, with coagulative necrosis of germinal cells. 75% or more of the seminiferous tubules demonstrated complete necrosis.
IV	Grade 2: Exhibits disordered, sloughed germinal cells. 25% or more of the seminiferous tubules contained variable degrees of necrosis.

injury following torsion of the testis and to examine the role of vitamin E as an antioxidant in ameliorating the testicular damage induced by torsion, under different experimental conditions in male Albino rats. The results of this study may potentiate medical therapies that would improve the timely rescue of the testis during torsion repair and provide further promising outcomes.

## METHODS

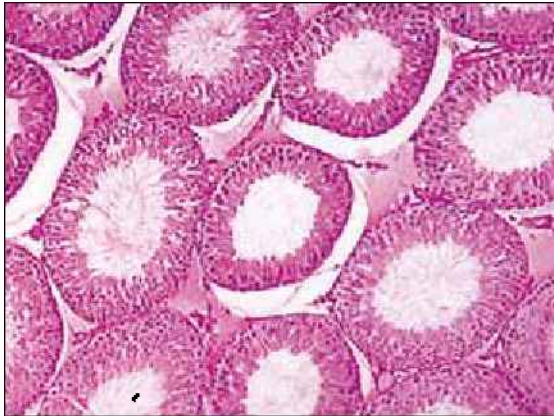
Adult male Albino rats of Wistar strain weighing 200–300 g were used in the present study. Orchiectomy, torsion and counter-rotation were performed through mid-scrotal vertical incisions. Ischaemia was manually induced by rotating the left testis 720° clockwise. The testis was counter-rotated (detorsion) to its original alignment for variable time for reperfusion. To study the effect of torsion and counter-rotation on the testis, the animals were randomly divided into four groups, each consisting of eight rats.

Group I rats (normal control group) underwent an operation to determine the basal values for histopathological evaluation. The left testis was brought out through the incision. Orchiectomy was performed, and the testis was processed for histopathological examination. In Group II rats (sham control group), the testicle was brought out through the incision, rotated 720° clockwise and immediately counter-rotated to its original alignment, with no additional intervention. The testis was then harvested and processed for histopathological examination. Group III (untreated control group) was designed to study the effects of testicular torsion on ipsilateral testes. In this group, after three hours of torsion and one hour of detorsion, orchiectomy was performed and the testis was processed for histopathological examination. Group IV rats, which were pre-treated with vitamin E (Merck Company Ltd, Bombay, India) 100 mg/kg body weight orally for 30 days, underwent torsion for three hours, followed by reperfusion for one

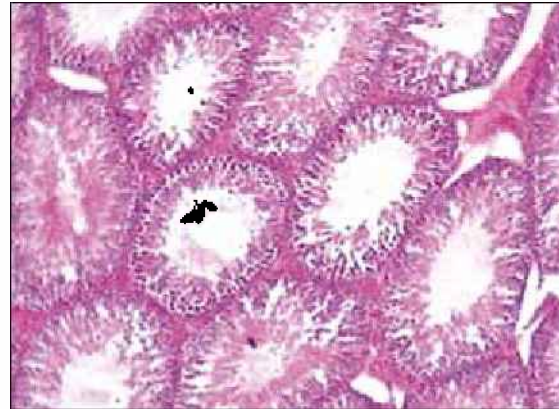
hour. Unilateral orchiectomy was performed, and the testis was processed for histopathological examination.

To obtain the quantitative analysis of testicular damage, the tissues were processed and paraffin blocks were prepared as per standard protocols.<sup>(13)</sup> Five-micron-thick sections were obtained and stained with haematoxylin and eosin for light microscopic analysis. To measure the standard tubular diameter (STD), five transversely cut seminiferous tubules from each testis at stage VII were selected randomly and measured per cross-section using a stage micrometer that was calibrated with an eyepiece micrometer. The two diameters of the tubules, one perpendicular to the other, were measured. The average of the transverse and perpendicular diameters was taken for each animal.<sup>(14)</sup> To measure the standard epithelial height (SEH), five transversely cut seminiferous tubules at stage VII were randomly selected and measured per cross-section tubules according to Canan et al's method.<sup>(14)</sup>

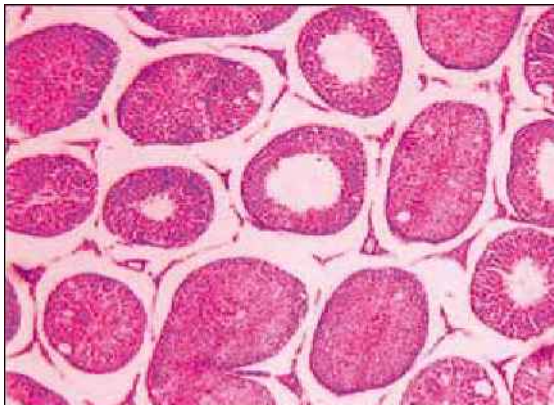For qualitative evaluation, the testes were examined for the presence of coagulation-type necrosis and classified into four grades.<sup>(8)</sup> Grade 0 showed an absence of coagulation and necrosis in the seminiferous tubules. Grade 1 indicated slight coagulation, with < 25% of the seminiferous tubules containing evidence of necrosis, which varied from an absence of spermatogenesis with disorganisation and loss of maturation layers to individual cell necrosis. Grade 2 indicated moderate coagulation with  $\geq$  25% of the seminiferous tubules containing variable degrees of necrosis, which varied from an absence of spermatogenesis with disorganisation and loss of maturation layers to individual cell necrosis. Grade 2 damage contained overlapping features of Grade 1 and Grade 3. Grade 3 indicated severe coagulation, where  $\geq$  75% of the seminiferous tubules demonstrated complete necrosis.



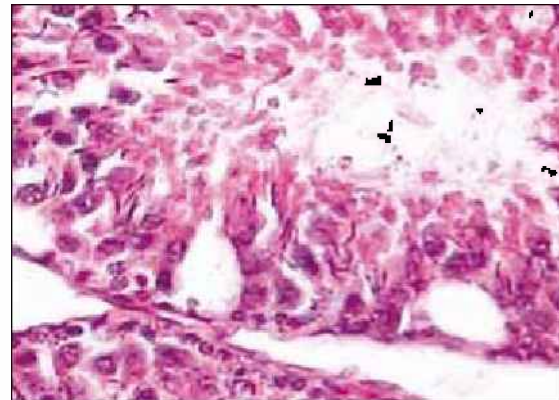
**Fig. 1** Photomicrograph of rat testis shows normal histological features in the normal control group (Group I) (Haematoxylin & eosin,  $\times 10$ ).



**Fig. 2** Photomicrograph of rat testis shows normal histological features in the sham control group (Group II) (Haematoxylin & eosin,  $\times 10$ ).



**Fig. 3** Photomicrograph shows necrosis in more than 75% of the seminiferous tubules in rats that had undergone three hours of testicular torsion followed by counter-rotation for one hour (Group III) (Haematoxylin & eosin,  $\times 10$ ).

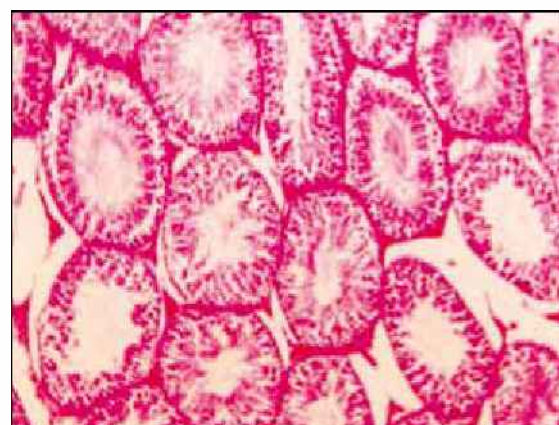


**Fig. 4** Photomicrograph shows cytoplasmic vacuoles in the seminiferous tubules of rats that had undergone three hours of testicular torsion followed by counter-rotation for one hour (Group III) (Haematoxylin & eosin,  $\times 60$ ).

Data were presented as mean  $\pm$  standard deviation (SD). Statistical analysis was calculated using the Statistical Package for the Social Sciences version 2 (SPSS Inc, Chicago, IL, USA). The analysis of multiple group variation was done by ANOVA. The post hoc least significant difference test was done for inter-group comparison. A p-value  $< 0.05$  was considered to be statistically significant.

## RESULTS

The changes in testicular STD and SEH after three hours of ischaemia followed by one hour of reperfusion are summarised in Table I. The untreated control group (Group III) exhibited a significant decrease in the STD, confirming testicular atrophy. The SEH in Group III was also decreased when compared to that of the control groups (Group I and Group II), thus demonstrating the degree of damage. However, rats that were pre-treated with vitamin E (Group IV) showed significant improvement in these parameters when compared to the untreated control group (Group III).



**Fig. 5** Photomicrograph shows less than 25% of necrosis in the seminiferous tubules of rats that were pre-treated with vitamin E prior to the induction of three hours of testicular torsion followed by counter-rotation for one hour (Group IV) (Haematoxylin & eosin,  $\times 10$ ).

Results of the histopathological analysis of the various control and test groups are summarised in Table II. The normal architecture of the seminiferous tubules

for Group I and II is shown in Figs. 1 & 2, respectively. The rats that had undergone torsion for three hours followed by one hour of detorsion (Group III) showed severe destruction of the tubular cells, i.e. Grade 3 (Figs. 3 & 4). There was disorganisation in the normal appearance of the testis. The majority of the cells showed degeneration, especially the spermatocytes and spermatids, in the form of vacuolated cytoplasm in variable configuration at the basal aspect of the germinal epithelium. The tubules had hardly any sperms when compared to Group I, the normal controls (Fig. 1). The haematoxylin and eosin-stained section of Group IV rats, the vitamin E pre-treated group (Fig. 5), showed lesser atrophic and degenerative changes (Grade 1) to the tubular epithelium when compared to the untreated control group (Group III). The seminiferous tubules in many of the sections showed near-normal architecture, with different layers of spermatogenic cells up to the spermatids. No vacuoles were observed in the germinal epithelium. However, in a few of the sections, the capsules showed mild atrophy.

## DISCUSSION

Testicular torsion may cause ipsilateral atrophy in about 30%–80% of the cases.<sup>(15)</sup> A possible cause of testicular injury during torsion is the oxygen free radicals produced during this phenomenon.<sup>(16)</sup> Hence, oxidative stress has been shown to be a major cause of male infertility, and a large proportion of infertile men have elevated levels of seminal ROS.<sup>(17-19)</sup> These ROS interact with lipids, proteins and nucleic acids, leading to the loss of membrane integrity, structural or functional changes in proteins and genetic mutations, respectively.<sup>(20)</sup> Resumption of blood flow or reperfusion following a period of ischaemia is thought to further damage the tissue due to the increased production of oxygen-derived free radicals through peroxidation of lipids in mitochondria and cell membranes.<sup>(21)</sup>

Serious lesions following ischaemic injury to the testis affecting the germinal epithelium, sertoli cells, tunica propria, interstitial tissue and Leydig cells is a well-known fact.<sup>(6)</sup> Prevention of reperfusion injury using a combination of several enzymes and drugs has been studied along with the assessment of histopathological changes after testicular torsion in rats.<sup>(7,8)</sup> Many tissues contain powerful endogenous scavengers that provide protection against free radical damage, including SOD, CAT, glutathione peroxidase (GPX), ascorbic acid and  $\alpha$ -tocopherol.<sup>(22)</sup> Even a ten-minute duration showed minor transient effects on the seminiferous epithelium.<sup>(23)</sup>

In the current study, the rats that were subjected to ischaemia (torsion) for three hours followed by reperfusion (counter-rotation) for one hour showed a decrease in STD

and SEH, a lesser degree of maturation of spermatozoa and cohesion of germinal cells. Sikka et al have reported that adequate levels of antioxidants such as SOD, CAT and possibly GPX and reductase, maintain the scavenging potential in gonads and seminal fluids, which is referred to as oxidative stress status.<sup>(24)</sup> Studies have shown that antioxidants play a critical role in monitoring sperm dysfunction and infertility.<sup>(25)</sup> In the present study, the rats that were pre-treated with antioxidant vitamin E for 30 days prior to the induction of torsion for three hours followed by one hour of counter-rotation (Group IV) showed a decrease in testicular tissue damage caused by reperfusion injury. Kolski et al studied the effect of hyperbaric oxygen on rat testis following counter-rotation by measuring the thickness of germinal epithelium and reported that a thicker epithelium was the sign of an effective treatment.<sup>(26)</sup>

In the present study, the rats that were treated with vitamin E showed an increased SEH compared to the untreated experimental controls. The results of the present study show that the STD and SEH decreased significantly in the untreated rats that had undergone torsion for three hours followed by reperfusion for one hour (Group III). However, upon pre-treatment with antioxidant vitamin E (Group IV), the seminiferous tubules in these rats showed less damage when compared to the untreated control group. The finding of our study was in accordance with Bozlu et al's study, where the animals that were pre-treated with poly (adenosine diphosphate-ribose) polymerase after two hours of testicular torsion showed a statistically significant increase in the mean diameter of the seminiferous tubules and germinal epithelial cell thickness.<sup>(27)</sup> The appearance of symplasts or multinucleated giant cells is known to be associated with the final common pathway of germinal cell degeneration in animals treated with tamoxifen citrate.<sup>(28)</sup> Multinucleated giant cells are thought to be formed due to karyokinesis that is not followed by cytokinesis.<sup>(29)</sup> Giant cells with a single nucleus are mostly degenerating cells, and are found in the lumen of the tubule. Hence, multinucleated cells are young, while mononucleated cells are older in the process of degeneration.<sup>(30)</sup>

The results of the present study also show that vitamin E plays a significant role in reducing histological damage by reducing sloughing of the germinal cells and increasing spermatogenesis after induction of ischaemia for three hours followed by one hour of reperfusion. Studies have shown that vitamins C and E are essential for normal spermatogenesis and that in the absence of such vitamins, the animals showed dysfunction of the germinal layers.<sup>(31,32)</sup> Supplementation of vitamins C and E has been found to reduce testicular ROS and restore normal testicular function in cadmium-exposed rats.<sup>(33)</sup> Both these

vitamins have often been simultaneously used in clinical and experimental medicine, as they synergistically exert a potent antioxidant action, which can provide protection against excessive oxidative damage.<sup>(34)</sup> Therefore, the results of the present study suggest that vitamin E, when administered before torsion of the spermatic cord in rats, offers significant protection against acute testicular torsion and detorsion injury.

## REFERENCES

- Dunne PJ, O'Loughlin BS. Testicular torsion: time is the enemy. *Aust N Z J Surg* 2000; 70:441-2.
- Kehinde EO, Anim JT, Mojiminiyi OA, et al. Allopurinol provides long-term protection for experimentally induced testicular torsion in a rabbit model. *BJU Int* 2005; 96:175-80.
- Steinberger E, Tjioe DY. Spermatogenesis in rat testes after experimental ischemia. *Fertil Steril* 1969; 20:639-49.
- Oeda T, Henkel R, Ohmori H, Schill WB. Scavenging effect of N-Acetyl-L-cysteine against reactive oxygen species in human semen: a possible therapeutic modality for male factor infertility? *Andrologia* 1997; 29:125-31.
- Akgür FM, Kilinç K, Aktuğ T, Olguner M. The effect of allopurinol pretreatment before detorting testicular torsion. *J Urol* 1994; 151:1715-7.
- Prillaman HM, Turner TT. Rescue of testicular function after acute experimental torsion. *J Urol* 1997; 157:340-5.
- Akhter S, Sridhar S, Katlowitz NM, et al. Immune response to testicular ischemia and reperfusion. *J Urol* 1990; 143:262.
- Greenstein A, Smith-Harrison LI, Wakely PE, et al. The effect of polyethylene glycol superoxide dismutase administration on histological damage following spermatic cord torsion. *J Urol* 1992; 148 (pt 2):639-41.
- Niki E. Handbook of antioxidants. In: Packer L, Cadenas E. eds. *α-Tocopherol*. Marcel Dekker, Inc. New York. Basel, Hong Kong. 1996:3-25.
- Halliwell B. Reactive oxygen species in living systems: source, biochemistry, and role in human disease. *Am J Med* 1991; 91:14S-22S.
- McCay PB. Vitamin E: interactions with free radicals and ascorbate. *Annu Rev Nutr* 1985; 5:323-40.
- McCay PB, King MM, Lia EK, Poyer JL. The effect of antioxidants on free radical production during IN VIVO metabolism of carbon tetrachloride. *Int J Toxicol* 1983; 2:195-206.
- Culling CFA, Allison RT, Barr WT. *Cellular pathology technique*. 4th ed. London: Butterworth-Heinemann, 1985.
- Canan S, Sahin B, Odaci E, et al. Estimation of the reference volume, volume density and volume ratios by a stereological method: Cavalieri's principle. *T Clin J Med Sci* 2002; 22:7-14.
- Smith-Harrison LI, Koontz WW Jr. Torsion of the testis: Changing concepts. *AUA update Series* 1990; 32:250.
- Southorn PA, Powis G. Free radicals in medicine. I. Chemical nature and biologic reactions. *Mayo Clin Proc* 1988; 63:381-9.
- Agarwal A, Said TM. Oxidative stress, DNA damage and apoptosis in male infertility: a clinical approach. *BJU Int* 2005; 95:503-7.
- Allamaneni SS, Agarwal A, Nallella KP, et al. Characterization of oxidative stress status by evaluation of reactive oxygen species levels in whole semen and isolated spermatozoa. *Fertil Steril* 2005; 83:800-3.
- Aitken RJ, Baker MA. Oxidative stress, sperm survival and fertility control. *Mol Cell Endocrinol* 2006; 250:66-9.
- Gillham B, Papachristodoulou DK, Thomas JH. *Wills' Biochemical Basis of Medicine*. 3rd ed. London: Butterworth-Heinemann, 1997.
- Kagan VE. *Lipid peroxidation in biomembranes*. Boca Raton: Florida: CRC Press, 1988:1-146.
- Demopoulos HB, Flamm ES, Pietronigro DD, Seligman ML. The free radical pathology and the microcirculation in the major central nervous system disorders. *Acta Physiol Scand Suppl* 1980; 492:91-119.
- Oettle AG, Harrison RG. The histological changes produced in the rat testis by temporary and permanent occlusion of the testicular artery. *J Pathol Bacteriol* 1952; 64:273-97.
- Sikka SC, Rajasekaran M, Hellstrom WJ. Role of oxidative stress and antioxidants in male infertility. *J Androl* 1995; 16:464-8.
- Alvarez JG, Touchstone JC, Blasco L, Storey BT. Spontaneous lipid peroxidation and production of hydrogen peroxide and superoxide in human spermatozoa. Superoxide dismutase as major enzyme protectant against oxygen toxicity. *J Androl* 1987; 8:338-48.
- Kolski JM, Mazolewski PJ, Stephenson LL, et al. Effect of hyperbaric oxygen therapy on testicular ischemia-reperfusion injury. *J Urol* 1998; 160:601-4.
- Bozlu M, Eskandari G, Cayan S, et al. The effect of poly (adenosine diphosphateribose) polymerase inhibitors on biochemical changes in testicular ischemiareperfusion injury. *J Urol* 2003; 169:1870-3.
- Gopalkrishnan K, Gill-Sharma MK, Balasinar N, et al. Tamoxifen-induced light and electron microscopic changes in rat testicular morphology and serum hormonal profile of reproductive hormones. *Contraception* 1998; 57:261-9.
- Reddy KJ, Svoboda DJ. Alterations in rat testis due to an antispermatogenic agent. Light and electron microscopic study. *Arch Pathol* 1967; 84:376-92.
- Chapin RE, Morgan KT, Bus JS. The morphogenesis of testicular degeneration induced in rats by orally administered 2,5-hexanedione. *Exp Mol Pathol* 1983; 38:149-69.
- Mason KE, Mauer SI. Reversible testis injury in the vitamin E-deficient hamster. *J Nutr* 1975; 105:484-90.
- Chinoy NJ, Mehta RR, Seethalakshmi L, Sharma JD, Chinoy MR. Effects of vitamin C deficiency on physiology of male reproductive organs of guinea pigs. *Int J Fertil* 1986; 31:232-9.
- Sen Gupta R, Sen Gupta E, Dhakal BK, Thakur AR, Ahnn J. Vitamin C and vitamin E protect the rat testes from cadmium-induced reactive oxygen species. *Mol Cells* 2004; 17:132-9.
- Leung HW, Vang MJ, Mavis RD. The cooperative interaction between vitamin E and vitamin C in suppression of peroxidation of membrane phospholipids. *Biochim Biophys Acta* 1981; 664:266-72.