

Multiple nodules on the face and trunk in metastatic adenocarcinoma of unknown primary origin

Furtado S, Bhat R M, Sukumar D, Krishnamurthy S G, Rao S D, Nandakishore B

ABSTRACT

Metastatic cancer of unknown primary (CUP) may unexpectedly manifest on the skin and subcutaneous tissue, prompting the patient to first visit a dermatologist. We describe an interesting case of cutaneous metastases from poorly differentiated adenocarcinoma of an unknown primary site in a 57-year-old man. The CUP had an unusually long period of indolence between presentation as a solitary axillary lymph node metastasis and rapid cutaneous dissemination. The possible causes of such a presentation are reviewed, and the management is briefly discussed. Diagnosis of unusual cutaneous manifestations of occult systemic malignancies could pose a diagnostic challenge to dermatologists.

Keywords: axilla, carcinoma, cutaneous metastasis, chemotherapy, tumour marker

Singapore Med J 2011;52(7):e163-e166

INTRODUCTION

Cutaneous metastasis is a rare presentation of metastatic cancer of unknown primary (CUP) and usually presents in the fifth to seventh decade of life. Most metastatic adenocarcinomas arise from a primary carcinoma in the lung, gastrointestinal tract, mammary tissue or prostate.⁽¹⁻³⁾ Our patient presented with multiple nodules on the face and trunk from a metastatic poorly differentiated adenocarcinoma (PDA). Determining the primary carcinoma in this case proved to be a diagnostic challenge.

CASE REPORT

A 57-year-old Indian man presented with a fungating lesion in the right axilla for five years. He had painless raised lesions over the face, scalp and trunk for four months and a recent onset of painful erythematous swelling of the right arm. The axillary lesion was indolent and painless, and was gradually increasing in size. He had an unremarkable systemic, oral, genital and

otorhinolaryngeal examination. His past medical and family history was insignificant, and he had no history of addictions.

On physical examination, we found multiple non-tender, indurated, erythematous or hyperpigmented nodules measuring 2–5 cm in diameter present over the trunk,

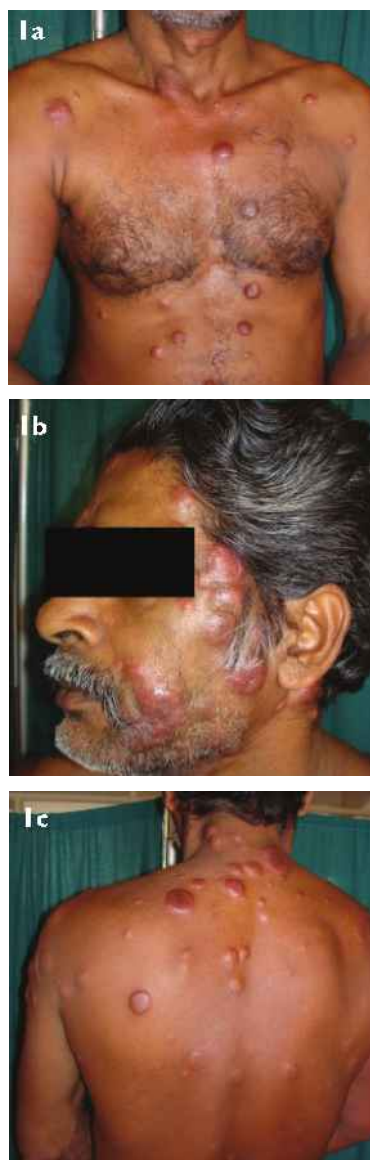

Fig. 1 Photographs show (a) nodules with central necrosis on the anterior trunk and (b) face; and (c) skin-coloured, erythematous nodules on the posterior trunk of the patient.

Department of
Dermatology,
Father Muller
Medical College
and Hospital,
Kankanady,
Mangalore 575002,
Karnataka,
India

Furtado S, MD
Senior Resident

Bhat RM, MD, DNB
Head

Sukumar D, MD
Professor

Nandakishore B, MD
Professor

Department of
Pathology

Krishnamurthy SG,
MD
Professor

Department of
Oncology

Rao SD, MD
Professor

Correspondence to:
Dr Shireen Furtado
Tel: (91) 824 2432439
Fax: (91) 824 2436352
Email: shireenseq@
gmail.com

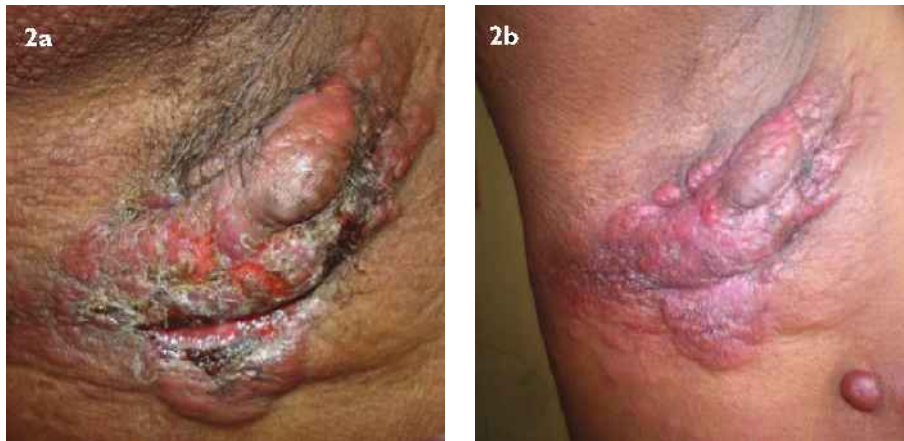

Fig. 2 Photographs show (a) a fungating mass in the right axilla at initial presentation and (b) regression of the axillary lesion after the fifth cycle of chemotherapy.

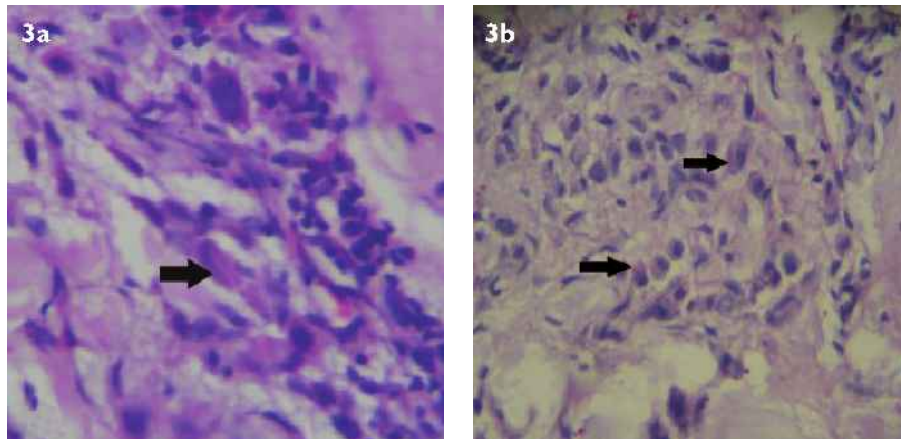


Fig. 3 Photomicrographs of the skin biopsy show (a) large atypical cells of poorly differentiated adenocarcinoma (arrow) (Haematoxylin & eosin, $\times 400$) and (b) atypical cells taking up a dark stain (arrows) (Mucicarmine stain, $\times 400$).

proximal upper extremities, face and scalp (Fig. 1). There were a few areas of central necrosis, and the proximal right arm showed early signs of cellulitis. No other palpable lymph nodes were found elsewhere. Cutaneous examination revealed a tender, fungating, oozing, ulcerated erythematous mass, measuring 6 cm \times 6 cm in the right axilla (Fig. 2a).

Haemogram, peripheral blood smear, blood chemistry, liver and renal parameters as well as urine analysis were all normal (Table I). Stool examination for occult blood was negative. Venereal Disease Research Laboratory test was non-reactive. Biopsy from the axillary mass revealed PDA, and biopsy from an indurated nodule on the chest showed a normal epidermis with dermal collection of large, atypical signet-ring cells, suggestive of a metastatic adenocarcinoma (Fig. 3a). Mucicarmine stain demonstrated mucin within the cells (Fig. 3b). Immunohistochemistry reports were negative for CD3, CD20 and CD68, thus ruling out cutaneous lymphoma.

Negative p53, along with the described histopathological picture, ruled out primary skin carcinoma and sweat gland tumour.

A search for the occult primary tumour was undertaken using the clinical recommendations of the European Society for Medical Oncology Group (ESMO).⁽¹⁾ Magnetic resonance (MR) imaging of the chest, abdomen and pelvis, together with gastroscopy, colonoscopy and thyroid ultrasonography, were normal. Tumour markers for breast (ER-PR), prostate-specific antigen (PSA) for prostate and carcinoembryonic antigen (CEA) for intestinal and lung malignancies were also negative (Table I). A diagnosis of CUP was made after reviewing the above clinical features and investigations.

The patient was started on palliative chemotherapy. Each cycle consisted of cisplatin (100 mg/m² IV on Day 1) and etoposide (100 mg/m² IV on Days 1–3), and the regime was repeated every three weeks for six cycles. Although no clinical improvement was

Table I. Laboratory investigations at initial presentation.

Parameter	Result (normal range)
Haemoglobin (gm/dl)	12.7 (13–15.5)
ESR (0–10 mm/hr)	110 mm/hr
Serum total bilirubin (0.2–1.0 mg/dl)	0.45 mg/dl
Serum albumin (3.5–5 gm/dl)	3.9 gm/dl
Serum creatinine (0.7–1.2 mg/dl)	1 mg/dl
Peripheral smear	Normal
Stool for occult blood	Negative
ER-PR	Negative
PSA (< 3 ng/ml)	1.9 ng/ml
CEA (< 2.5 ng/ml)	0.5 ng/ml
p53 from skin biopsy	Negative
CD3, CD20, CD68 from skin biopsy	Negative

ESR: erythrocyte sedimentation rate; ER-PR: tumour markers for breast; PSA: prostate-specific antigen; CEA: carcinoembryonic antigen

observed after the first three cycles, gradual shrinkage of the lesions was seen thereafter (Fig. 2b). After nine months of chemotherapy, all the lesions and axillary fungation had regressed, and no other site of metastasis was found. The patient had no new skin lesions and remained symptom-free for a period of six months after completion of chemotherapy. Repeat MR imaging of the chest, abdomen and pelvis after treatment revealed no pathology. However, he developed another crop of metastatic lesions on the skin over the inguinal region and the liver one-and-a-half years after the initial diagnosis of CUP. At this stage, radiological and serological investigations did not reveal the primary site, and the patient succumbed to liver failure one month later.

DISCUSSION

CUP is an intriguing phenomenon that is found in 5%–10% of all newly diagnosed patients with cancer.^(1,2) It is defined as histologically confirmed metastasis in the absence of an identifiable primary tumour, despite exploration with standardised diagnostic approach.^(1,3) The hallmarks of this clinical entity are dormancy of the primary tumour, early systemic metastasis and general resistance to treatment.^(3–6)

The frequency of cutaneous metastasis from visceral malignancies is 0.6%–10%, with lung carcinoma being the most common primary malignancy.^(7,8) Cutaneous metastases represent 2% of all skin tumours and occur in an area near the primary tumour served by its lymphatic drainage or vascular supply.^(8,9) Skin and soft tissue metastases, however, are unusual manifestations of CUP.⁽¹⁰⁾ Skin metastases are classified morphologically

as nodular, infiltrative, diffuse, or intravascular and top heavy or bottom heavy.⁽⁸⁾ Top heavy and bottom heavy patterns refer to cutaneous cellular infiltrates with a large base in the superficial or deep part of the dermis, respectively.⁽⁸⁾

PDA commonly arises from a primary tumour in the chest, abdomen or prostate.⁽¹⁰⁾ A high index of suspicion for cutaneous metastasis should be maintained in patients presenting with such florid clinical manifestations, especially those that do not fit any primary dermatological pathology. In our case, the initial site of metastasis was possibly the right axillary lymph node. Interestingly, the axillary metastasis remained asymptomatic for five years. It was a recent onset (four months) of cutaneous and scalp metastases that prompted our patient's visit to the hospital. This was an extremely rare presentation of CUP, and the metastatic lesion may have possibly contained additional genetic or phenotypic alterations that were not observed in the primary or in the axillary metastasis, prompting its rapid spread.⁽¹¹⁾ There are reports of 'precocious metastasis' from malignancies like renal cell carcinomas and lung malignancies, where the primary site remains occult due to involution or small tumour size.⁽¹²⁾ Based on the sites of metastases in our patient, we surmise that the presumptive site of the 'occult' primary may have been the gastrointestinal tract or lung. It could be argued that the skin tumour in our patient was eccrine or apocrine in origin. However, apocrine cell tumours have 'decapitation secretion' characteristics, and eccrine tumours show 'tubular lumina' in some sections. These were not documented in the biopsies of the masses on the axilla and chest. The fact that the primary remained undiagnosed in our case at both presentations of cutaneous metastasis is noteworthy.

The management of CUP requires a multi-disciplinary approach, involving both medical and surgical oncologists and pathologists. Their collective effort is required to diagnose the clinical entity, plan appropriate treatment and prognosticate the patient's outcomes. A combination of chemotherapy and etoposide for treatment of CUP has shown good response rates. In a preliminary study, the combination of etoposide and cisplatin has been shown to produce a high response rate of 60% within a median duration of five months, with 37% of patients having complete response.⁽¹³⁾ Disease-free survival of 39–63 months after completion of therapy was recorded in a minority of patients in the same study.⁽¹³⁾ Similarly, our patient initially responded well to this combination chemotherapy. In a phase II study involving a combination of paclitaxel and cisplatin in CUP, an

overall response rate of 42% was reported, along with a median survival time of 11 months.⁽¹⁴⁾

According to Nashan et al, cutaneous metastasis has led to the diagnosis of internal malignancy in 22% of cases.⁽⁹⁾ Chopra et al reported that 56% of their patients had skin metastasis as the first presenting sign, which subsequently led to the diagnosis of visceral malignancy.⁽⁷⁾ Such metastases have also been reported in surgical scars and excisions performed for unrelated cutaneous malignancies.⁽¹⁵⁾ The incidence of cutaneous metastasis from colorectal and lung carcinoma is 4%–6.5% and 7%–19%, respectively.⁽¹⁶⁾ Skin metastasis is an indication of late presentation of an internal malignancy, and is associated with a poor prognosis and survival rate of one year in 50% and three years in 20% of patients,⁽¹²⁾ as demonstrated in our case.

REFERENCES

- Briasoulis E, Pavlidis N, Felip E, ESMO Guidelines Working Group. Cancers of unknown primary site: ESMO clinical recommendation for diagnosis, treatment and follow-up. *Ann Oncol* 2008; 19 Suppl 2:106-7.
- van de Wouw AJ, Jansen RL, Speel EJ, Hillen HF. The unknown biology of the unknown primary tumour: a literature review. *Ann Oncol* 2003; 14:191-6.
- Pavlidis N, Fizazi K. Cancer of unknown primary (CUP). *Crit Rev Oncol Hematol* 2005; 54:243-50.
- Pavlidis N, Briasoulis E, Hainsworth J, Greco FA. Diagnostic and therapeutic management of cancer of an unknown primary. *Eur J Cancer* 2003; 39:1990-2005.
- Nystrom JS, Weiner JM, Heffelfinger-Juttner J, et al. Metastatic and histologic presentations in unknown primary cancer. *Semin Oncol* 1977; 4:53-8.
- Pentheroudakis G, Briasoulis E, Karavassilis V, et al. Chemotherapy for patients with two favourable subsets of unknown primary carcinoma: Active, but how effective? *Acta Oncol* 2005; 44:155-60.
- Chopra R, Chhabra S, Samra SG, et al. Cutaneous metastases of internal malignancies: a clinicopathologic study. *Indian J Dermatol Venereol Leprol* 2010; 76:125-31.
- Fernandez-Flores A. Cutaneous metastases: a study of 78 biopsies from 69 patients. *Am J Dermatopathol* 2010; 32:222-39.
- Nashan D, Müller ML, Braun-Falco M, et al. Cutaneous metastases of visceral tumours: a review. *J Cancer Res Clin Oncol* 2009; 135:1-14.
- Bowen GM, Chang AE, Lowe L, et al. Solitary melanoma confined to the dermal and/or subcutaneous tissue: evidence for revisiting the staging classification. *Arch Dermatol* 2000; 136:1397-9.
- Speel EJ, van de Wouw AJ, Claessen SM, et al. Molecular evidence for a clonal relationship between multiple lesions in patients with unknown primary adenocarcinoma. *Int J Cancer* 2008; 123:1292-300.
- Bhatia S, Ng S, Hodder SC. Metastatic cutaneous head and neck renal cell carcinoma with no known primary: case report. *Br J Oral Maxillofac Surg* 2010; 48:214-5.
- Hainsworth JD, Johnson DH, Greco FA. The role of etoposide in the treatment of poorly differentiated carcinoma of unknown primary site. *Cancer* 1991; 67 Suppl 1:310-4.
- Park YH, Ryoo BY, Choi SJ, Yang SH, Kim HT. A phase II study of paclitaxel plus cisplatin chemotherapy in an unfavourable group of patients with cancer of unknown primary site. *Jpn J Clin Oncol* 2004; 34:681-5.
- Resnik KS, DiLeonardo M, Gibbons G. Clinically occult cutaneous metastases. *J Am Acad Dermatol* 2006; 55:1044-7.
- Molina Garrido MJ, Mora Rufete A, Guillén Ponce C, Maciá Escalante S, Carrato Mena A. Skin metastases as first manifestation of lung cancer. *Clin Transl Oncol* 2006; 8:616-7.