

Ectopic pregnancy in previous Caesarean section scar

Hong S C, Lau M S K, Yam P K L

ABSTRACT

We report two cases of Caesarean scar pregnancies that were managed surgically. The first case was a 33-year-old woman who presented at 21 weeks of gestation with lower abdominal pain. An exploratory laparotomy was performed as she was hypotensive and had a drastic drop in haemoglobin level. Intraoperatively, a ruptured scar ectopic pregnancy with placenta percreta was found. A hysterectomy was performed in view of uncontrolled haemorrhage. The second case was a 30-year-old woman who presented with irregular per vaginal spotting without abdominal pain. Ultrasonography revealed a gestational sac at a previous Caesarean scar, with interval increase in size and development of a yolk sac. On laparoscopy, the diagnosis of scar pregnancy was confirmed, and the gestational sac and surrounding myometrium were excised. Our case report shows that early diagnosis of scar pregnancy is important, as timely intervention can prevent life-threatening complications and preserve fertility.

Keywords: Caesarean scar pregnancy, ectopic pregnancy, placenta praevia, placenta percreta, uterine rupture

Singapore Med J 2011;52(6):e115-e117

INTRODUCTION

Implantation of an ectopic pregnancy within a previous Caesarean section (CS) scar is a rare condition. However, its incidence is increasing over the years due to the rise in CS rates worldwide. Caesarean scar pregnancy is potentially life-threatening if not diagnosed and treated early. It may lead to catastrophic complications, such as uncontrolled haemorrhage and uterine rupture as the pregnancy progresses, which may require hysterectomy and result in subsequent loss of fertility. The outcome is dependent on early diagnosis and timely intervention. Hence, it is important that antenatal care providers are aware of this rare form of ectopic pregnancy. We report two cases of Caesarean scar pregnancy that were diagnosed at different periods during gestation,

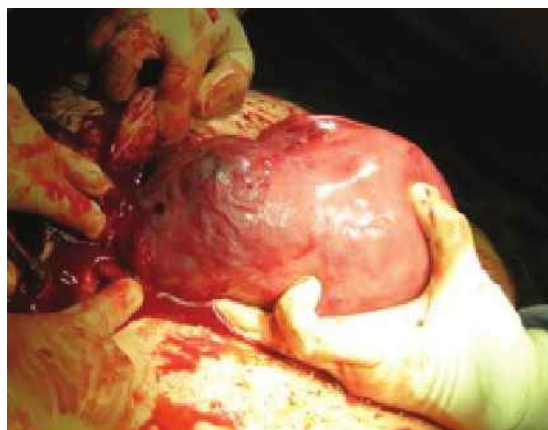

Fig. 1 Photograph shows ruptured Caesarean scar pregnancy during laparotomy.

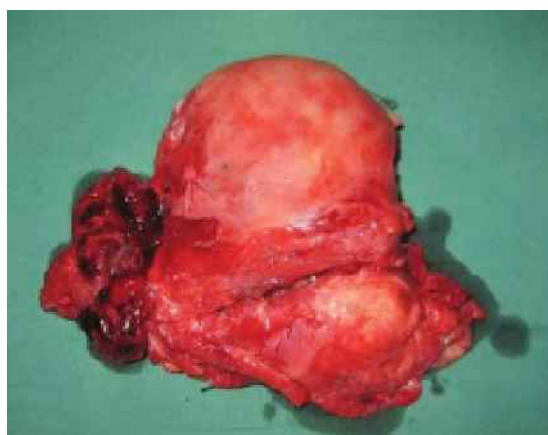


Fig. 2 Photograph of the uterus after hysterectomy shows placenta percreta.

illustrating our experience with the management as well as the description of different outcomes.

CASE REPORT

Case 1

The first case was a 33-year-old mother of one with a history of two previous CSs. Her second CS was performed for uterine rupture following a trial of vaginal birth after CS at term. She presented to our hospital at 21 weeks' gestation with sudden onset of lower abdominal pain and hypotension. On examination, there was marked pallor and her blood pressure was 67/39 mmHg. Abdominal examination revealed tenderness over the CS scar, without any signs of peritonism. Bedside

Department of
General Obstetrics
and Gynaecology,
KK Women's and
Children's Hospital,
100 Bukit Timah
Road,
Singapore 229899

Hong SC, MBBS,
MMed, MRCOG
Registrar

Lau MSK, MBBS,
MMed, MRCOG
Associate Consultant

Yam PKL, MBBS,
MMed, FRCOG
Senior Consultant
and Head

Correspondence to:
Dr Hong Sze Ching
Tel: (65) 8121 1749
Fax: (65) 6298 6343
Email: hong_sze_ching@hotmail.com

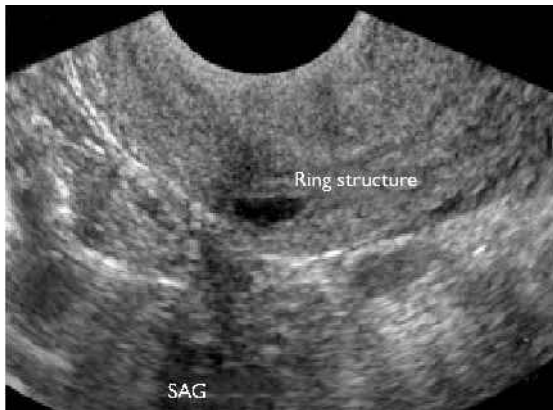

Fig. 3 Transvaginal US image shows a ring structure measuring 1.2 cm × 0.9 cm × 0.7 cm in the lower anterior uterine wall at the region of the previous scar.

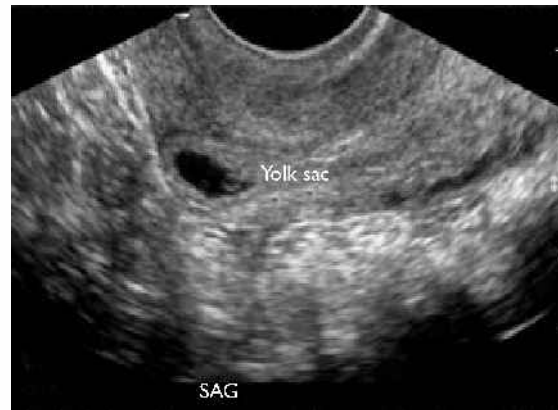

Fig. 4 Repeat transvaginal US image shows interval development of a small yolk sac within the cystic structure.

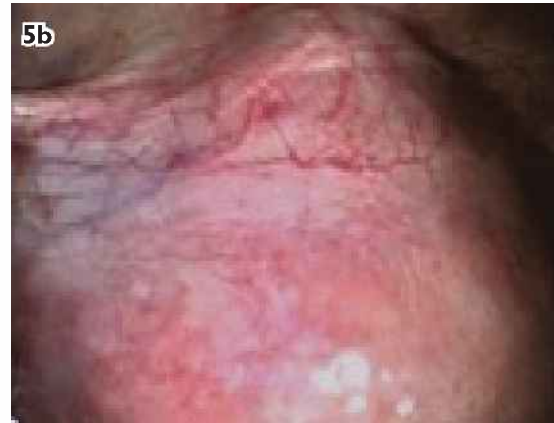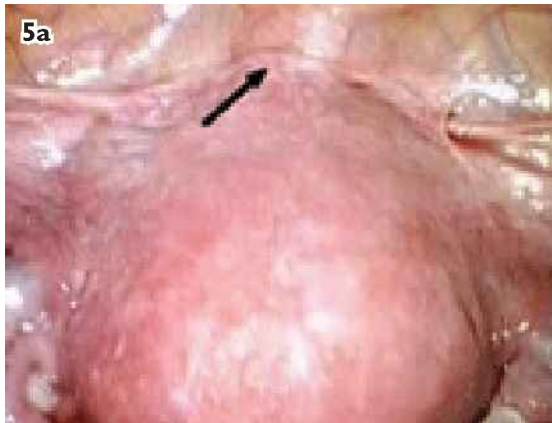


Fig. 5 Laparoscopic images show (a) Caesarean scar pregnancy (arrow) at the lower uterine segment and (b) Caesarean scar pregnancy after intramyometrial vasopressin injection.

transabdominal ultrasonography (US) revealed a viable foetus and placenta praevia major. The patient was resuscitated, and her haemoglobin level dropped from 9.0 g/dL on admission to 5.5 g/dL the following morning. She subsequently underwent exploratory laparotomy.

Intraoperatively, we found a ruptured uterine scar with part of the amniotic sac protruding through the scar with placenta percreta, and the placenta edge had reached the lower edge of the defect (Fig. 1). The uterus was evacuated, and a decision was made for hysterectomy in view of the uncontrolled haemorrhage (Fig. 2). As the placenta was closely adherent to the bladder, the operation was complicated by inadvertent bladder cystotomy, which was quickly repaired. An estimated 5 L of blood was lost, and the patient received massive blood transfusion. Postoperative recovery was uneventful. Histopathology showed placental tissue extending outside the anterior uterine wall to the adjacent fibrofatty tissue. She was discharged well on postoperative Day 7. An outpatient cystogram on postoperative Day 14 was normal, and

her urinary catheter was removed without any further complications.

Case 2

The second case was a 30-year-old woman with a history of one previous CS, who presented with spotting per vaginum at five weeks' amenorrhoea. Transvaginal pelvic US showed a 1.2-cm ring structure in the anterior lower uterine wall at the location of the previous CS scar (Fig. 3). No intrauterine gestational sac, adnexal masses or free fluid were noted on the scan. The patient's first set of serum beta-hCG was 5031.8 IU/L. She was offered admission for diagnostic laparoscopy, which she declined. Her second set of beta-hCG increased to 10,470.1 IU/L after 56 hours. Repeat transvaginal pelvic US showed a similar finding, with an interval development of a small yolk sac within the cystic structure (Fig. 4). The patient did not experience any symptom of pain or bleeding at this point, and was clinically stable. She was offered the options of methotrexate therapy or diagnostic laparoscopy

with the possibility of repairing the scar defect, and she opted for the latter. On laparoscopy, the diagnosis of scar pregnancy was confirmed intraoperatively. A gestational sac with definite products of conception was seen at the lower anterior uterine wall, and this was excised together with the surrounding myometrium after intramyometrial vasopressin injection (Fig. 5). The uterine defect was repaired laparoscopically. Histopathology of the specimen showed fibrotic smooth muscle with implantation reaction and chorionic villi. Postoperative recovery of the patient was uneventful, and her beta-hCG level was undetectable at three weeks' follow-up.

DISCUSSION

Caesarean scar pregnancy is the rarest form of ectopic pregnancy. It was first reported by Larsen and Solomon in 1978,⁽¹⁾ and its incidence was reported by Seow et al to be 6.1%.⁽²⁾ However, with the increasing rates of CS worldwide over the years, we can expect the overall incidence of scar pregnancy to increase as well. Early and accurate diagnosis of the condition is crucial, as a delay in diagnosis may lead to life-threatening complications such as uterine rupture and massive haemorrhage. As the gestational sac may continue to develop in the CS scar, the trends of beta-hCG increment may mimic a viable intrauterine pregnancy. Hence, a high index of suspicion is important, and close monitoring should be rendered when the diagnosis is suggested by transvaginal US. A variety of conservative and surgical approaches have been proposed for the treatment of Caesarean scar pregnancy; however, the optimal mode of management is yet to be established due to its rare occurrence. Most of the recent literature mainly consists of case reports and small case series.

Methotrexate is the most common type of medical therapy that is suitable for use in early pregnancy, and can be administered systemically and locally. It may be single- or multidose, and can be combined with uterine artery embolisation or curettage as an adjunct. This procedure, however, has been met with variable success.⁽³⁻⁵⁾ The advantages include preservation of fertility and eliminating the need for surgery with its associated risks and complications. However, it requires a long period of follow-up for beta-hCG to decline to normal levels and for the gestational mass to resolve completely. It may also be associated with symptoms such as spotting per vaginum. Failure of medical therapy will eventually necessitate secondary surgical

intervention. Medical treatment is also unsuitable in cases of advanced gestation and uterine rupture, as illustrated in the first case, where the patient was haemodynamically unstable. As spontaneous rupture is a rare event antenatally, we postulate that it occurred in the presence of a scar ectopic pregnancy.

Surgical interventions include resection of the ectopic pregnancy or hysterectomy. Curettage was considered unsuitable as the first-line treatment option; the trophoblastic tissue was outside the uterine cavity and perforation of the implantation site may occur and result in severe peritoneal haemorrhage, which may ultimately require further surgical treatment.^(1,6) In the event of emergency, laparotomy and hysterectomy may be required. However, if the diagnosis is made during early gestation in a haemodynamically stable patient, laparoscopic excision of the ectopic pregnancy is possible, with minimal morbidity and preservation of future fertility.^(7,8) The ectopic pregnancy can thus be removed, the uterine defect repaired and the uterus conserved.

In conclusion, scar pregnancy, if not detected early in pregnancy, may lead to serious morbidity or mortality. With a high index of suspicion, early diagnosis is possible with US. Serial beta-hCG is of limited value in the diagnosis of scar pregnancy. Early scar pregnancy may be treated successfully with laparoscopic surgery, with preservation of future fertility.

REFERENCES

1. Larsen JV, Solomon MH. Pregnancy in a uterine scar sacculus--an unusual cause of postabortal haemorrhage. A case report. *S Afr Med J* 1978; 53:142-3.
2. Seow KM, Huang LW, Lin YH, et al. Caesarean scar pregnancy: issues in management. *Ultrasound Obstet Gynecol* 2004; 23:247-53.
3. Kiley J, Shulman LP. Caesarean scar ectopic pregnancy in a patient with multiple prior caesarean sections: a case report. *J Reprod Med* 2009; 54:251-4.
4. Zhuang Y, Huang L. Uterine artery embolization compared with methotrexate for the management of pregnancy implanted within a cesarean scar. *Am J Obstet Gynecol* 2009; 201:152.e1-3.
5. Wang JH, Xu KH, Lin J, Xu JY, Wu RJ. Methotrexate therapy for cesarean section scar pregnancy with and without suction curettage. *Fertil Steril* 2009; 92:1208-13.
6. Fylstra DL. Ectopic pregnancy within a cesarean scar: a review. *Obstet Gynecol Surv* 2002; 57:537-43.
7. Wang CJ, Chao AS, Yuen LT, et al. Endoscopic management of cesarean scar pregnancy. *Fertil Steril* 2006; 85:494.e1-4.
8. Wang YL, Su TH, Chen HS. Laparoscopic management of an ectopic pregnancy in a lower segment cesarean section scar: a review and case report. *J Minim Invasive Gynecol* 2005; 12:73-9.