

# Autoimmune hepatitis in children: a report of two cases

Basir N, Yew T G, Telisinghe P U, Chong V H

## ABSTRACT

**In regions where chronic hepatitis B infections are still endemic, autoimmune hepatitis (AIH) is considered rare, and it is even rarer in the paediatric population. AIH in the paediatric population is categorised into type 1 and 2, which are differentiated by their autoantibody profiles. We present two cases of paediatric type 1 AIH. Two girls aged 11 and 15 years were referred to our hospital with chronic liver disease, one of whom had decompensated disease. Both patients were started on prednisolone. The patient with advanced liver disease died from complications due to infections that included the pandemic novel influenza A H1N1, while the other patient responded to treatment. These two cases serve to highlight the importance of considering AIH in any paediatric patient presenting with features of chronic liver disease, as the response to treatment is good.**

**Keywords: autoantibodies, autoimmune hepatitis, chronic hepatitis, complications, human leukocyte antigens**

*Singapore Med J 2011; 52(2):e27-e30*

## INTRODUCTION

Autoimmune hepatitis (AIH) is a progressive inflammatory disorder characterised by the presence of interphase hepatitis, plasma cell infiltrations and rosette formations on histology, the presence of circulating non-organ-specific autoantibodies and increased levels of serum IgG of unknown aetiology.<sup>(1)</sup> AIH is generally uncommon and is even less common among the paediatric population. The profiles of AIH in the paediatric population are similar to those in adults, the only difference being that the disease tends to be more severe in the former.<sup>(2,3)</sup> Literature search shows that only a single case of AIH in the paediatric population has been reported from the Southeast Asian region.<sup>(4)</sup> These two cases serve to highlight and bring to the attention of clinicians that AIH should always be considered in paediatric patients presenting with chronic liver disease.<sup>(5)</sup>

## CASE REPORTS

### Case 1

An 11-year-old Malay girl presented to the paediatric clinic with a history of intermittent jaundice from the age of one. However, in the past one month, her symptoms had worsened and were associated with intermittent fever and mild nonspecific abdominal pain. There was no history of previous operation, blood transfusion or any use of traditional medications. On physical examination, she had pallor, jaundice, pedal oedema and hepatosplenomegaly. Her vital signs were normal.

Laboratory investigations showed hypochromic, microcytic anaemia (Hb 7.8 gm/dl, range 12–16 gm/dl), deranged coagulation profile (activated partial thrombin time [APTT] 56 sec, prothrombin time [PT] 44.5 sec, international normalised ratio [INR] 4.2), hypoalbuminaemia (17 gm/L, range 35–45 gm/L), hyperbilirubinaemia (200 umol/l, range 17–34 umol/l) and transaminitis (alanine aminotransferase [ALT] 170 IU/L). Serum IgG was elevated (44.1 gm/L). Viral hepatitis screens (HAV IgM, HBsAg, HBsIgM and IgG, HCVIgG, Epstein-Barr virus, cytomegalovirus and herpes simplex virus) were all negative. Metabolic markers were also negative. Only serum anti-smooth muscle antibody (SMA) was positive at 1:40. Serum anti-nuclear antibody (ANA) and anti-liver kidney microsomal antibody (LKM-1) were negative. Ultrasonography (US) of the abdomen showed hepatosplenomegaly and coarse liver echotexture, which was consistent with chronic liver disease. There was no ascitis.

At this point, the patient was advised on hospital admission, but her parents declined. She re-presented four days later with signs of liver failure. She was referred to the general hepatologist, and a liver biopsy was considered. However, this was deferred as her coagulation profiles were persistently deranged despite repeated doses of vitamin K and fresh frozen plasma transfusions. Her case was discussed with an overseas liver transplant centre, and the overseas doctors concurred with the authors' suspicion of type 1 AIH. Human leukocyte antigen (HLA) testing was positive for A24, B18, B75, Cw7, Cw8, DRB1\*04 (DR4), DRB\*16 (DR2) and DQB1\*05. The patient's International Autoimmune Hepatitis Group (IAIHG) score before treatment was 15,

Division of  
Gastroenterology  
and Hepatology,  
Department of  
Medicine,  
Raja Isteri Pengiran  
Anak Saleha  
Hospital,  
Bandar Seri  
Begawan,  
BA 1710,  
Brunei Darussalam

Basir N, MBChB  
Medical Officer

Chong VH, MRCP,  
FAMS, FRCP  
Consultant

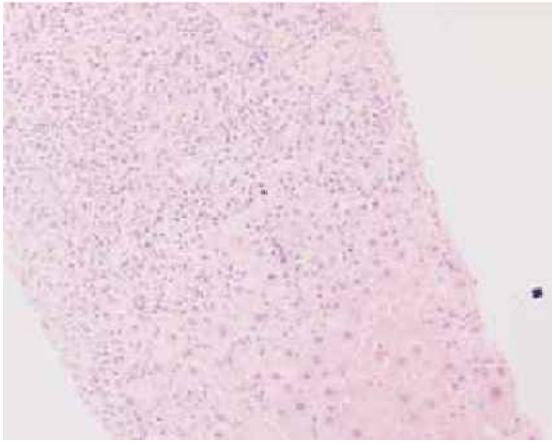
Department of  
Paediatrics

Yew TG, MBChB,  
MRCP  
Consultant

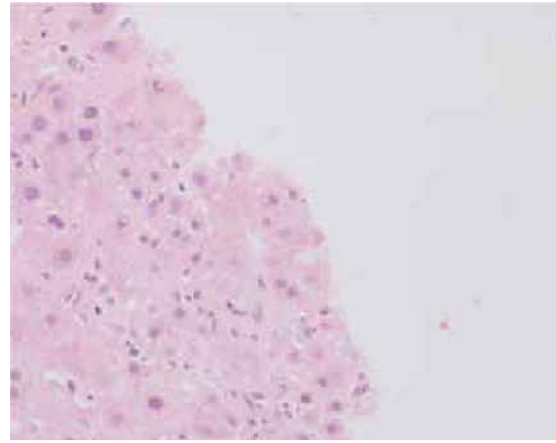
Department of  
Pathology

Telisinghe PU,  
MBBS, FRCPPath  
Senior Consultant

Correspondence to:  
Dr Vui Heng Chong  
Tel: (673) 8778218  
Fax: (673) 2242690  
Email: chongvuih@  
yahoo.co.uk



**Fig. 1** Photomicrograph of the liver shows interphase hepatitis (Haematoxylin & eosin,  $\times 20$ )



**Fig. 2** Photomicrograph of the liver shows rosette formation (Haematoxylin & eosin,  $\times 40$ )

which was consistent with a probable diagnosis of AIH. Interestingly, it later came to light that the patient's older brother had died of liver failure of unknown aetiology at the age of 11 years.

The patient was started on prednisolone (2 mg/kg/day) and evaluated for suitability for liver transplantation. Detailed discussions with the transplant team suggested that the most likely aetiology was AIH and that transplant was indicated. Unfortunately, the patient's condition progressed. She developed Grade III hepatic encephalopathy that was precipitated by bronchopneumonia and was transferred to the paediatric intensive care unit. Serum ammonia level was elevated. This was further complicated by right-sided pneumothorax, requiring insertion of a chest drain. The patient was electively intubated and ventilated. Respiratory secretions collected after intubation later tested positive for the novel influenza A H1N1, adenovirus and mycoplasma (IgM). Unfortunately, her condition deteriorated, and she died 20 days after admission.

## Case 2

A 15-year-old Chinese girl was referred with a four-month history of jaundice and dark-coloured urine. There was no fever or abdominal pain. The patient was previously well and had not taken any supplements or traditional medications. There was no family history of chronic liver disease or any autoimmune disorder. Physical examination showed mild hepatosplenomegaly, but no ascitis. Laboratory investigations showed anaemia (Hb 9.1 gm/dL), thrombocytopenia ( $112 \times 10^9/L$ ) elevated erythrocyte sedimentation rate (33 mm/hr), deranged clotting profiles (APTT, 47 sec and INR, 1.4), hyperbilirubinaemia (166 mmol/L), transaminitis (ALT 234 U/L) and mildly elevated ALP (197 U/L) and

GGT (87 U/L). The serum ANA and anti-LKM-1 were both negative, but strongly positive for SMA (1:640). Metabolic and hepatitis viral markers were negative. US of the liver showed diffuse coarse echotexture. A liver biopsy showed Grade 3 and Stage 3 (METAVIR score) changes, with plasma cell infiltrations, interphase hepatitis (Fig. 1) and rosette formation (Fig. 2), consistent with AIH. There were no bile duct changes. The pre-treatment IAHG score was 20, which was definite for AIH. HLA typing was positive for A29, A33, B7, Cw3, DRB1\*03 (DR3), DRB1\*10, DQB1\*02 and DQB1\*05. The patient responded to prednisolone (1.5 mg/kg/day) therapy, and on her last clinic visit, which was more than a year since her diagnosis, the clinical and biochemical profiles had normalised.

## DISCUSSION

AIH in the paediatric population is categorised into two types, type 1 and type 2, depending on the antibody profile. AIH type 1 is characterised by the presence of SMA and/or ANA, whereas AIH type 2 is positive for anti-LKM-1 antibody. Type 2 AIH is also commonly associated with IgA deficiency.<sup>(3)</sup> Most children are diagnosed before the age of 18 years, with peak incidence before puberty. Three-quarters of affected children are female. The disease severity is similar in both types of AIH. However, type 2 AIH is less common and tends to present at a younger age and more acutely.<sup>(3)</sup> Both our patients had type 1 AIH, based on their profiles.

In the East, AIH is considered uncommon among adults and is even less common among the paediatric population. Therefore, most clinicians caring for adult and paediatric patients may not come across an AIH case in their lifetime of practice. Only one case report from Malaysia has been found among the entire southeast region.<sup>(4)</sup> However, it is likely that the actual number is

**Table 1 The International Autoimmune Hepatitis Group Scoring System<sup>(5)</sup>**

Factor	Score
Gender	
Female	+2
Serum ALP:AST ratio	
< 1.5	+2
1.5–3.0	0
> 3.0	-2
Serum globulin or IgG above normal	> 2
Serum ANA, SMA, LKMI*	
> 1:80	+3
1:80	+2
1:40	+1
< 1:40	0
Drug use history	
Positive	-4
Negative	+1
Average daily alcohol intake	
< 25 gm/day	+2
> 60 gm/day	-2
Hepatitis viral markers	
Positive	-3
Negative	+3
AMA	
Positive	-4
Negative	0
Other autoimmune diseases	
Positive	+2
Negative	0
Novel antibodies (anti-SLA/LP, anti-LCI, pANCA, anti-ASGPR)	
Positive	+2
HLA DR3 or DR4	
Positive	+1
Histological findings	
Interface hepatitis	+3
Lymphoplasmacytic infiltrate	+1
Rosette formation	+1
None of the above	-5
Biliary changes	-3
Other changes	+2
Response to corticosteroids	
Complete	+2
Relapse after drug withdrawal	+3
Aggregate score without treatment	
Definite AIH	> 15
Probable AIH	10–15
Aggregate score post treatment	
Definite AIH	> 17
Probable AIH	12–17

\* In paediatric population, the score assigned is slightly different: >1:40 (+3); 1:40 (+2); 1:20 (+1); <1:20 (0)

ALP: alkaline phosphatase; AST: aspartate aminotransferase; Ig: immunoglobulin; ANA: antinuclear antibody; SMA: smooth muscle antibody; LKMI: liver kidney microsomal antibody; AMA: antimitochondrial antibody, SLA/LP: soluble liver antigen/liver-pancreas; LCI: liver cytosol type I; pANCA: perinuclear antineutrophil cytoplasm; ASGPR: asialoglycoprotein receptor; HLA: human leukocyte antigen; AIH: autoimmune hepatitis

more than expected, as some cases may have remained undiagnosed or unreported. In our setting, experience with AIH had mostly been with the adult population, and these are the first two cases to be diagnosed among our paediatric population. Therefore, it is not unexpected that local paediatricians are not familiar with the disorder.

The diagnosis of AIH in the paediatric population uses the established IAIHG scoring system for the adult population.<sup>(5,6)</sup> The scoring system takes into account several variables, including clinical, laboratory and histological features, which are assigned a score (Table 1). The responsiveness to treatment, particularly to steroid therapy, and relapses are also important. Scores > 17 before treatment, between 15 and 17, and < 15 provide a definite diagnosis, probable diagnosis and exclude a diagnosis of AIH, respectively. The only obvious difference between the score used for paediatric and adult population is the amount of titre considered as significant for autoimmune antibodies. In the paediatric population, autoimmune positivity is extremely rare and a titre of 1:20 is considered significant.

Our second patient had a definite score for AIH, whereas our first case was only probable. This was because we were not able to perform a liver biopsy, which would have provided additional information. Despite this, we have no doubt that the first patient had AIH, as the overall profiles were consistent. Furthermore, the paediatric transplant team was also certain of the diagnosis. The scoring system has recently undergone some simplifications and certain variables, including gender, serum ALP:AST ratio, drug history, serum AMA status, other autoimmune disease and alcohol use, have been omitted. The scoring for serum IgG ratio and autoimmune antibodies titre has also been simplified. The simplified scoring is still new and has not been fully accepted, and will thus require further validation.<sup>(7)</sup>

Generally, liver biopsy is essential for the diagnosis and assessment of disease severity so as to determine the need for treatment. It is also important to rule out the possibility of autoimmune sclerosing cholangitis (ASC), especially if there is a cholestatic profile.<sup>(8,9)</sup> In fact, ASC is as prevalent as AIH in the paediatric population and the two conditions share many similarities (interphase hepatitis and antibodies profiles). However, in ASC, both genders are equally affected. Diagnosis usually requires imaging of the biliary tree, and treatment requires the addition of ursodeoxycholic acid, as steroid therapy will only address the parenchyma inflammation. None of our patients had cholestatic profiles.

The presentations of our patients were consistent with AIH.<sup>(3)</sup> Our first patient presented with a long history of intermittent exacerbations. The advanced nature of her disease contributed to the poor outcome after contracting the novel influenza A H1N1, mycoplasma and adenovirus infections. At that time, the outbreak of the novel influenza H1N1 had just started in our local setting, and thus, the diagnosis was not initially suspected. The

patient was immediately started on oseltamivir. Our second patient had a shorter history and presented earlier. She also presented soon after our first patient and hence, the diagnosis was made without much delay.

The indications for treatment in children are similar to those in adult patients with AIH.<sup>(3,8)</sup> However, children tend to present at advanced stages, which could be partly attributed to delayed presentations or late diagnosis.<sup>(3,9)</sup>

<sup>10</sup> The milder forms of the disease described in adults are not typically observed in children.<sup>(9,11)</sup> In fact, 50% of affected children have cirrhosis at presentation. Therefore, it is particularly important to consider AIH in paediatric patients presenting with chronic liver disease. Immunosuppression with prednisolone is the mainstay of treatment.<sup>(9)</sup> Azathioprine can be used as a steroid-sparing agent. It has been shown that regardless of the severity of the disease at presentation, the response to treatment is generally excellent in children. Biochemical profiles usually normalise after six to nine months of therapy in 75%–90% of affected children.<sup>(3)</sup> However, relapse is also common, and treatment failure is reported in 5%–15% of patients. Without treatment, most cases will rapidly progress to cirrhosis and liver failure, the only treatment for which is liver transplantation.

In the West, the HLA A1-B8-DR3 haplotype is associated with younger age at diagnosis and poor response to steroid therapy.<sup>(12,13)</sup> HLA-DR4 is more common in the East, especially in Japanese patients, and is usually detected in those negative for DR3. Interestingly, the HLA profiles of AIH in the East are different from those in the West. However, studies are still limited. We have previously shown that HLA-Cw7 and DQB1\*04 were significantly associated with our adult AIH patients, but not DR3 or DR4. However, both DR3 and DR4 were detected in 18.2% and 45.5% of our adult AIH patients, respectively.<sup>(14)</sup> HLA-Cw7, DR4 and DQB1\*04 were detected in the first patient who died, while DR3 was detected in the second patient.

In conclusion, AIH in the paediatric population is considered rare. As the condition is eminently treatable, clinicians, including general practitioners and paediatricians, should always consider AIH in children presenting with chronic or acute liver disease. This is especially true in regions where chronic hepatitis B infection remains endemic.

## REFERENCES

1. Czaja AJ, dos Santos RM, Porto A, Santrach PJ, Moore SB. Immune phenotype of chronic liver disease. *Dig Dis Sci* 1998; 43:2149-55.
2. Gregorio GV, Portmann B, Reid F, et al. Autoimmune hepatitis in childhood: a 20-year experience. *Hepatology* 1997; 25:541-7.
3. Mieli-Vergani G, Heller S, Jara P, et al. Autoimmune hepatitis. *J Pediatr Gastroenterol Nutr* 2009; 49:158-64.
4. Lee WS, Saw CB, Sarji SA. Autoimmune hepatitis/primary sclerosing cholangitis overlap syndrome in a child: diagnostic usefulness of magnetic resonance cholangiopancreatography. *J Paediatr Child Health* 2005; 41:225-7.
5. Alvarez F, Berg PA, Bianchi FB, et al. International Autoimmune Hepatitis Group Report: review of criteria for diagnosis of autoimmune hepatitis. *J Hepatol* 1999; 31:929-38.
6. Ebbeson RL, Schreiber RA. Diagnosing autoimmune hepatitis in children: is the International Autoimmune Hepatitis Group scoring system useful? *Clin Gastroenterol Hepatol* 2004; 2:935-40.
7. Hennes EM, Zeniya M, Czaja AJ, et al. Simplified criteria for the diagnosis of autoimmune hepatitis. *Hepatology* 2008; 48:169-76.
8. Gregorio GV, Portmann B, Karani J, et al. Autoimmune hepatitis/sclerosing cholangitis overlap syndrome in childhood: a 16-year prospective study. *Hepatology* 2001; 33:544-53.
9. Maggiore G, Bernard O, Hadchouel M, et al. Treatment of autoimmune chronic active hepatitis in childhood. *J Pediatr* 1984; 104:839-44.
10. Maggiore G, Veber F, Bernard O, et al. Autoimmune hepatitis associated with anti-actin antibodies in children and adolescents. *J Pediatr Gastroenterol Nutr* 1993; 17:376-81.
11. Roberts EA. Autoimmune hepatitis. *Indian J Pediatr* 1995; 62:525-31.
12. Donaldson PT. Genetics in autoimmune hepatitis. *Semin Liver Dis* 2002; 22:353-64.
13. Czaja AJ, Freese DK; American Association for the Study of Liver Disease. Diagnosis and treatment of autoimmune hepatitis. *Hepatology* 2002; 36:479-97.
14. Jalihal A, Telisinghe PU, Chong VH. Profiles of autoimmune hepatitis in Brunei Darussalam. *Hepatobiliary Pancreat Dis Int* 2009; 8:602-7.