

## CME Article

# ECG ST segment elevation in patients with chest pain

Poh K K, Tan H C, Teo S G

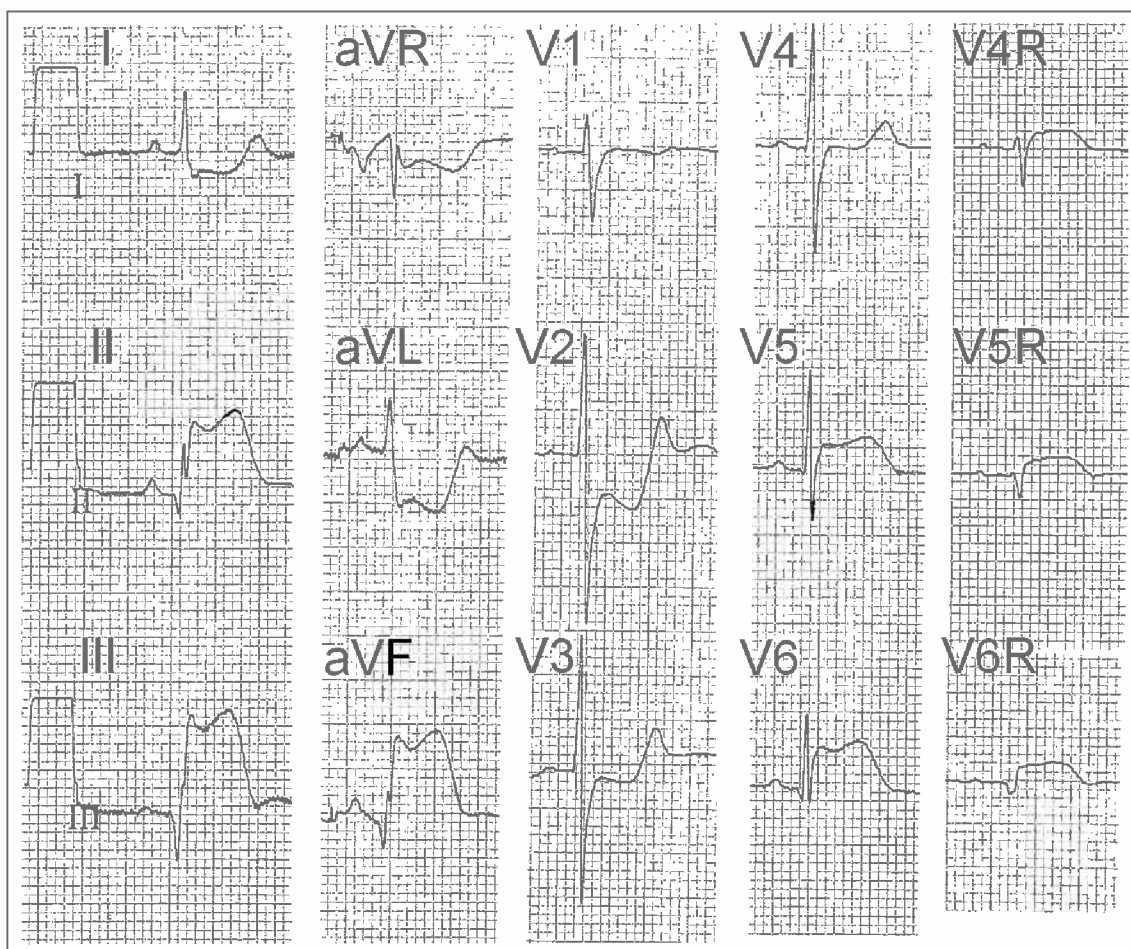


Fig. 1 ECG shows inferoposterior ST elevation myocardial infarction of the left ventricle, with lateral wall extension and right ventricular infarction.

Cardiac Department,  
National University  
Heart Centre,  
Yong Loo Lin School  
of Medicine,  
National University  
of Singapore,  
1E Kent Ridge Road,  
NUHS Tower Block,  
Level 9,  
Singapore 119228

Poh KK, MBBChir,  
FRCP, FACC  
Consultant and  
Associate Professor

Tan HC, MBBS,  
FRCP, FACC  
Senior Consultant and  
Associate Professor

Teo SG, MBBS, MRCP  
Consultant

Correspondence to:  
A/Prof Poh Kian Keong  
Tel: (65) 9237 3289  
Fax: (65) 6872 2998  
Email: doctorpoh@  
yahoo.com

## CASE I CLINICAL PRESENTATION

A 52-year-old woman presented to the emergency department with a history of severe chest pain, diaphoresis, vomiting and nausea. Clinical examination revealed no abnormalities. The blood pressure was 156/89 mmHg. An electrocardiography (ECG) was recorded, chest radiography was performed and blood

tests were taken. Based on the findings seen in the ECG, intravenous streptokinase was administered. The patient was then admitted to the coronary care unit for monitoring. Due to the recurrence of chest pain post thrombolytic therapy, a coronary angiogram was performed. The ECG recorded in the coronary care unit is shown in Fig. 1. What are the ECG abnormalities? What is the diagnosis?

### ECG INTERPRETATION

The 12-lead ECG in Fig. 1 shows (a) sinus rhythm; and (b) marked ST elevation in leads II, III, aVF (III > II), with reciprocal ST depression in leads aVL and I. There is also a prominent Q wave in lead III. These changes indicate inferior ST elevation myocardial infarction (STEMI). The ST segment is depressed in leads V2 and V3, indicating posterior STEMI. The elevated ST in leads V5 and V6 reflects an extension of the infarction to the lateral wall. Right-sided chest leads V4R, V5R and V6R all show > 1 mm ST elevation, indicating concomitant right ventricular infarction.

### CLINICAL COURSE

Coronary angiography revealed a tubular 75% stenosis of the mid right coronary artery (RCA). There was also a 50% stenosis of the mid left anterior descending artery (LAD). Left ventricular (LV) angiogram showed akinesia of the inferior wall of the left ventricle. The LV ejection fraction (EF) was estimated to be about 45%. Coronary angioplasty with stenting was successfully performed on the stenosed lesion of the RCA. The patient's subsequent hospital stay was uneventful.

The serum creatine kinase (CK), CKMB fraction and

troponin T levels at the time of hospital admission were all markedly elevated, confirming that the patient had suffered an acute myocardial infarction. The blood test, in addition, showed that she had diabetes mellitus. She was discharged from hospital with the following medications: aspirin, clopidogrel, lovastatin, metformin, atenolol and enalapril. The patient has been followed up for close to nine years as an outpatient, and has been found to be well and asymptomatic.

### CASE 2

#### CLINICAL PRESENTATION

A 52-year-old man was admitted with severe chest pain. What are the ECG abnormalities in Fig. 2? Which is the culprit coronary artery?

#### ECG INTERPRETATION

The 12-lead ECG in Fig. 2 shows (a) sinus rhythm; and (b) marked ST elevation in leads V2 to V6, I and aVL. There is reciprocal ST depression in leads II, III and aVF.

#### CLINICAL COURSE

Coronary angiography revealed obstruction of the proximal LAD.

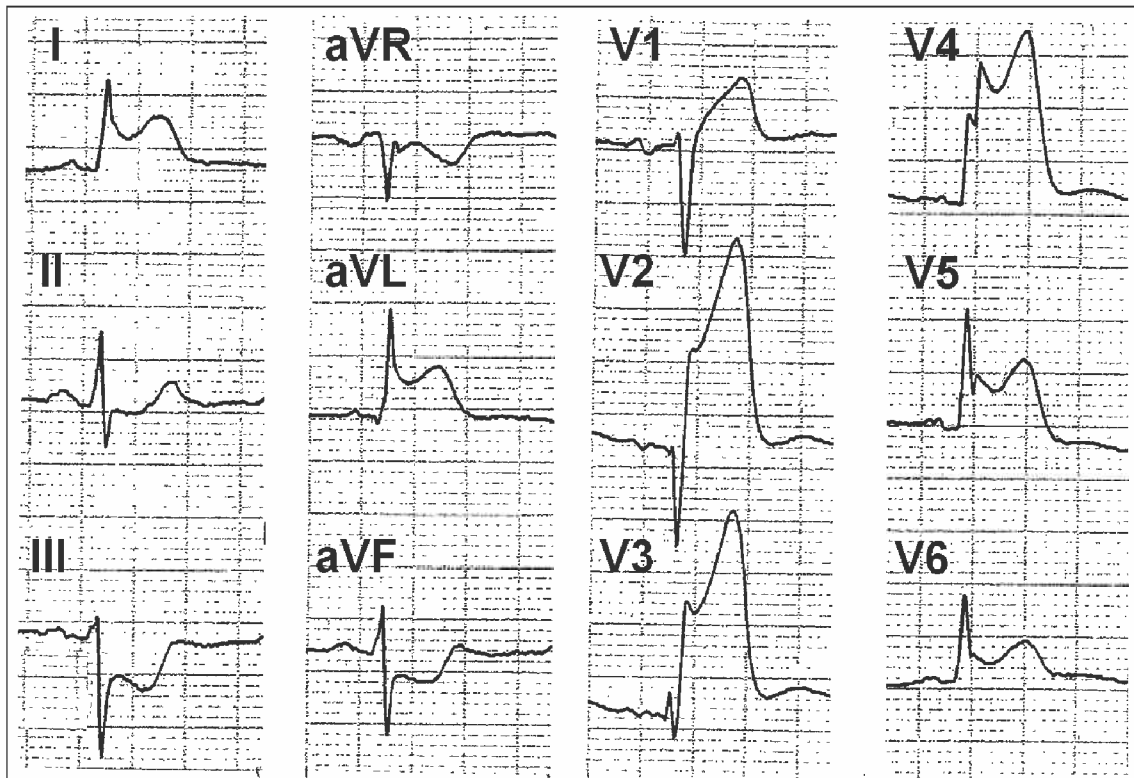


Fig. 2 ECG shows anterior ST elevation myocardial infarction of the left ventricle.

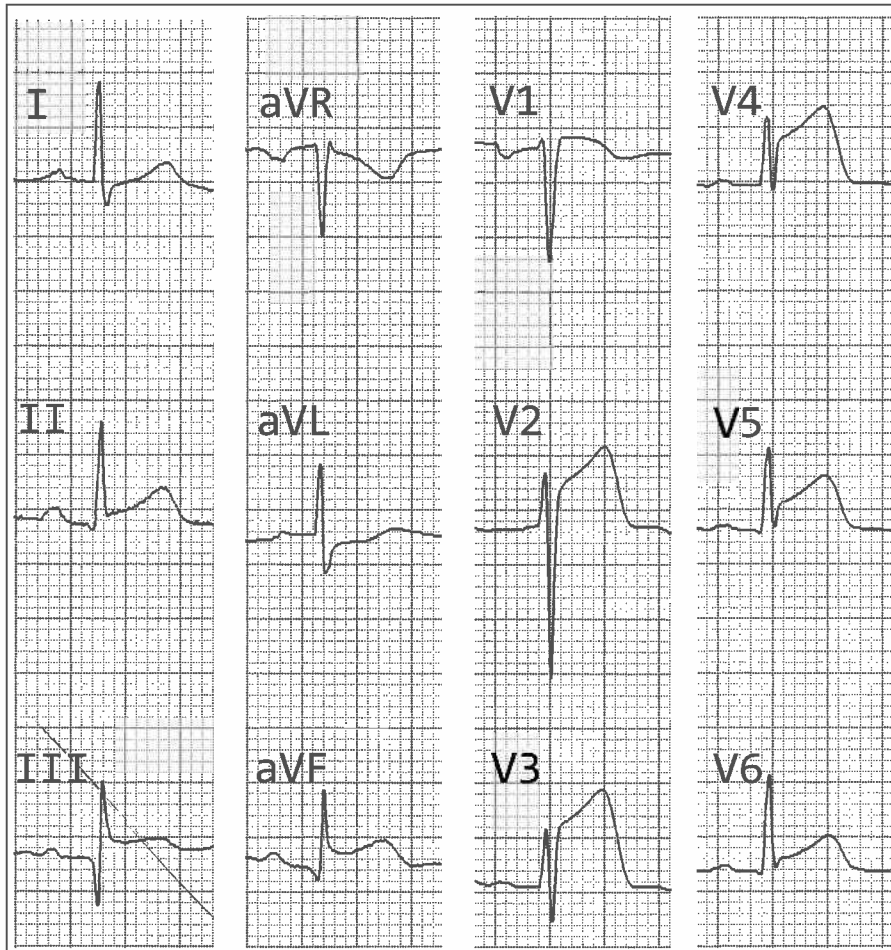


Fig. 3 ECG shows concomitant anterior and inferior ST elevation myocardial infarction of the left ventricle.

### CASE 3

#### CLINICAL PRESENTATION

A 51-year-old man with a history of cigarette smoking and a normal ECG several months ago, presented with a one-day history of left-sided chest pain associated with diaphoresis. The physical examination was unremarkable. On arrival at the hospital's emergency room, a 12-lead ECG was performed (Fig. 3). What are the ECG abnormalities? What is the diagnosis?

#### ECG INTERPRETATION

Fig. 3 shows (a) ST elevation in the anterior leads V1 to V6 (maximum in lead V3); (b) ST elevation in the inferior leads II, III and aVF (< 2 mm), with reciprocal ST depression in lead aVL; and (c) prominent Q wave in lead III.

#### CLINICAL COURSE

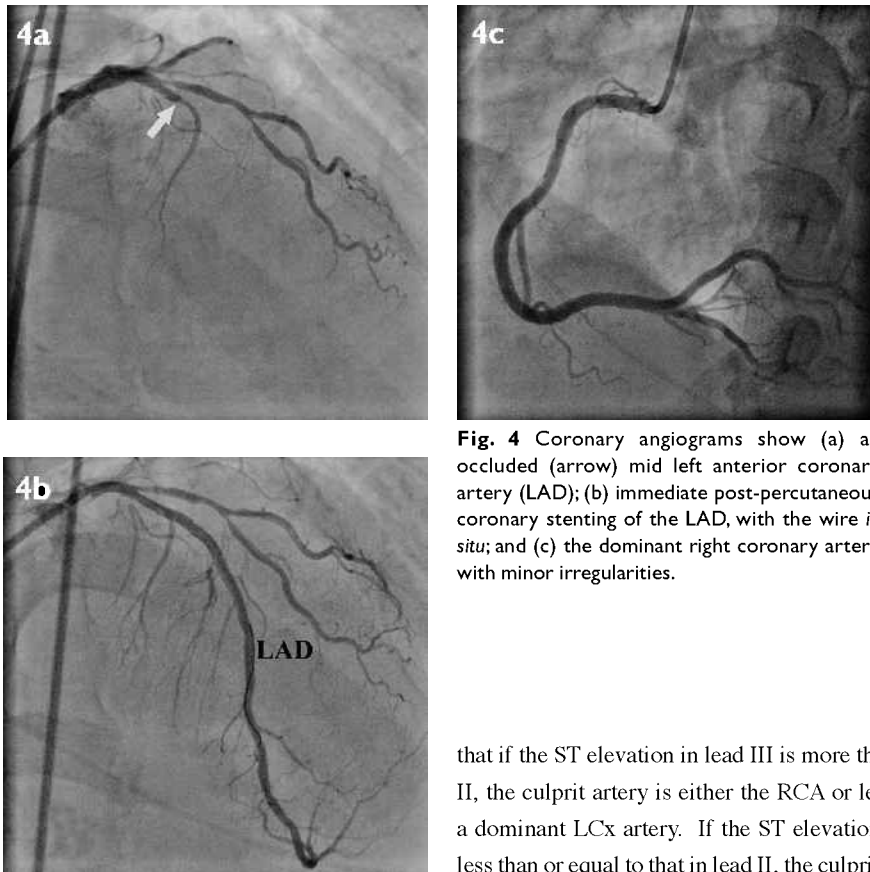
The patient was immediately sent to the invasive catheterisation laboratory. Urgent coronary angiogram showed an occluded mid LAD (Fig. 4a). Primary percutaneous coronary intervention was successfully

performed (Fig. 4b). The dominant RCA was not significantly stenosed (Fig. 4c). His serum cardiac enzymes were elevated. Serum CK was 1,353 U/L, CKMB was 88 ug/L and troponin I was 19.5 ug/L. The patient was prescribed dual antiplatelet therapy (prasugrel and aspirin), simvastatin, enalapril and metoprolol. Pre-discharge echocardiography showed regional wall motion abnormalities in the LAD territory, but preserved LVEF and an absence of LV thrombus. He was discharged well with a follow-up appointment.

#### DISCUSSION

ST segment elevation may be due to many causes. However, the three most important causes are STEMI, which was previously known as acute transmural myocardial infarction, acute pericarditis and early repolarisation. A fourth important cause of ST elevation that has been recognised in the past few years is Brugada syndrome, which is associated with sudden death in the young.

STEMI is most commonly caused by a sudden total occlusion of the coronary blood flow due frequently to



**Fig. 4** Coronary angiograms show (a) an occluded (arrow) mid left anterior coronary artery (LAD); (b) immediate post-percutaneous coronary stenting of the LAD, with the wire *in situ*; and (c) the dominant right coronary artery with minor irregularities.

rupture of an atherosclerotic plaque. This is followed by coronary thrombosis. The hallmark ECG finding in the hyperacute or early stage of STEMI is ST segment elevation in at least two adjacent or contiguous leads (e.g. leads V2 and V3, I and aVL, or III and aVF). In order to qualify for the definition of ST elevation in the diagnosis of STEMI, the ST segment must be  $\geq 2$  mm at the J point in leads V1, V2 and V3, or  $\geq 1$  mm in all the other leads. If reciprocal ST depression is present, this is a strong indicator of STEMI as opposed to the other causes of ST elevation.<sup>(1)</sup>

The LAD and RCA are the two most common culprit arteries in STEMI. Less commonly, the left circumflex artery (LCx) and rarely, the left main coronary artery (LMCA) are involved. Anterior STEMI, where the ST is elevated in leads V1 to V6, I and aVL with reciprocal ST depression in leads II, III and aVF, is most likely due to LAD occlusion. However, rarely, it may be due to LMCA occlusion. Inferior STEMI, where the ST is elevated in leads II, III and aVF with reciprocal ST depression in leads I and aVL, is most often due to RCA occlusion and less commonly due to LCx occlusion. In both these situations, posterior infarction (as reflected by ST depression in leads V1 to V3) is frequently seen.<sup>(2)</sup> Recent studies have shown

that if the ST elevation in lead III is more than that in lead II, the culprit artery is either the RCA or less commonly, a dominant LCx artery. If the ST elevation in lead III is less than or equal to that in lead II, the culprit artery is very likely a non-dominant LCx artery.<sup>(3)</sup> Right-sided chest leads V4R to V6R should be performed when the 12-lead ECG shows inferior STEMI. ST elevation ( $\geq 1$  mm) in these leads (especially lead V4R) indicates the presence of concomitant right ventricular infarction<sup>(4)</sup> (as seen in Case 1). This occurs in more than one-third of the cases of inferior STEMI and is due to occlusion of the RCA, before the origin of the first major right ventricular branch (usually at the proximal segment of the RCA).

In Case 3, there was inferior ST elevation associated with acute anterior myocardial infarction. This occurs uncommonly (about 4% in a large retrospective series).<sup>(5)</sup> It may suggest the presence of transmural ischaemic myocardium in the inferior as well as the anterior walls. Often, occlusion of a wrap-around LAD distal to its first diagonal branch is observed.<sup>(6)</sup> In this situation, the LAD wraps around the LV apex and supplies part of the inferior wall. In this group of patients, the peak serum CK level tends to be comparatively lower, with better preserved LVEF and lower in-hospital mortality.<sup>(6)</sup> However, if this is not due to a wrap-around LAD occlusion, the clinical presentation is frequently serious and the clinical outcomes unfavourable. The patients have a significantly higher incidence of cardiogenic shock, pulmonary oedema, sudden cardiac death due to sustained malignant ventricular tachyarrhythmias and a higher 30-day mortality rate. This group of patients tends to have ST segment elevation  $\geq 2$  mm in the inferior leads

compared to the wrap-around LAD occlusion patients, where the ST segment elevation is < 2 mm in the inferior leads. Coronary angiography shows that the incidence of multivessel disease and the incidence of severe obstructive two-vessel disease are significantly higher in the non-wrap-around LAD occlusion group. Identification of these clinical and ECG features would be important for early, aggressive and appropriate management.

#### ABSTRACT

**We discussed three cases of ST elevation myocardial infarction with ST elevation in the inferoposterior territory and anterior territory, and more uncommonly, concomitant ST elevations in the anterior and inferior electrocardiography (ECG) leads. Correct interpretation of the ECG is crucial in recognising this cardiac emergency, which often necessitates urgent coronary revascularisation. In addition, ECG aids localisation of the infarct-related artery and adds prognostic value.**

**Keywords: culprit vessel, diagnosis, electrocardiography, management, myocardial infarction, prognosis, ST-elevation**

*Singapore Med J 2011;52(1): 3-8*

#### ACKNOWLEDGEMENTS

We acknowledge Professor Chia Boon Lock for his help and advice in the writing of this article.

#### REFERENCES

1. Rowlandson I, Xue J, Farrell R. Computerized STEMI recognition: an example of the art and science of building ECG algorithms. *J Electrocardiol* 2010; 43:497-502.
2. Zhan ZQ, Wang W, Dang SY, et al. Electrocardiographic characteristics in angiographically documented occlusion of the dominant left circumflex artery with acute inferior myocardial infarction: limitations of ST elevation III/II ratio and ST deviation in lateral limb leads. *J Electrocardiol* 2009; 42:432-9.
3. Chia BL, Yip JW, Tan HC, Lim YT. Usefulness of ST elevation II/III ratio and ST deviation in lead I for identifying the culprit artery in inferior wall acute myocardial infarction. *Am J Cardiol* 2000; 86:341-3.
4. Wagner GS, Macfarlane P, Wellens H, et al. AHA/ACCF/HRS recommendations for the standardization and interpretation of the electrocardiogram: part VI: acute ischemia/infarction: a scientific statement from the American Heart Association Electrocardiography and Arrhythmias Committee, Council on Clinical Cardiology; the American College of Cardiology Foundation; and the Heart Rhythm Society. Endorsed by the International Society for Computerized Electrocardiology. *J Am Coll Cardiol* 2009; 53:1003-11.
5. Yip HK, Chen MC, Wu CJ, et al. Acute myocardial infarction with simultaneous ST-segment elevation in the precordial and inferior leads: evaluation of anatomic lesions and clinical implications. *Chest* 2003; 123:1170-80.
6. Tamura A, Kataoka H, Nagase K, Mikuriya Y, Nasu M. Clinical significance of inferior ST elevation during acute anterior myocardial infarction. *Br Heart J* 1995; 74:611-4.

**SINGAPORE MEDICAL COUNCIL CATEGORY 3B CME PROGRAMME**  
**Multiple Choice Questions (Code SMJ 201101A)**

	True	False
<b>Question 1.</b> What is the cause of chest pain in the patients who are presented?		
(a) Acute myocardial infarction.	<input type="checkbox"/>	<input type="checkbox"/>
(b) Angina pectoris.	<input type="checkbox"/>	<input type="checkbox"/>
(c) Pneumothorax.	<input type="checkbox"/>	<input type="checkbox"/>
(d) Pulmonary embolism.	<input type="checkbox"/>	<input type="checkbox"/>
<b>Question 2.</b> The following are often seen in acute myocardial infarction:		
(a) Diaphoresis.	<input type="checkbox"/>	<input type="checkbox"/>
(b) Nausea.	<input type="checkbox"/>	<input type="checkbox"/>
(c) Numbness of the legs.	<input type="checkbox"/>	<input type="checkbox"/>
(d) Dyspnoea.	<input type="checkbox"/>	<input type="checkbox"/>
<b>Question 3.</b> ST elevation may be seen in:		
(a) ST elevation myocardial infarction.	<input type="checkbox"/>	<input type="checkbox"/>
(b) Jaundice.	<input type="checkbox"/>	<input type="checkbox"/>
(c) Acute gout.	<input type="checkbox"/>	<input type="checkbox"/>
(d) Acute pericarditis.	<input type="checkbox"/>	<input type="checkbox"/>
<b>Question 4.</b> The two most common culprit artery lesions causing ST elevation myocardial infarction are:		
(a) Left main coronary artery.	<input type="checkbox"/>	<input type="checkbox"/>
(b) Left circumflex artery.	<input type="checkbox"/>	<input type="checkbox"/>
(c) Left anterior descending artery.	<input type="checkbox"/>	<input type="checkbox"/>
(d) Right coronary artery.	<input type="checkbox"/>	<input type="checkbox"/>
<b>Question 5.</b> In patients presenting with ST elevation, the presence of reciprocal ST depression suggests:		
(a) ST elevation myocardial infarction.	<input type="checkbox"/>	<input type="checkbox"/>
(b) Acute pericarditis.	<input type="checkbox"/>	<input type="checkbox"/>
(c) Early repolarisation.	<input type="checkbox"/>	<input type="checkbox"/>
(d) Brugada syndrome.	<input type="checkbox"/>	<input type="checkbox"/>

**Doctor's particulars:**

Name in full: \_\_\_\_\_

MCR number: \_\_\_\_\_ Specialty: \_\_\_\_\_

Email address: \_\_\_\_\_

**SUBMISSION INSTRUCTIONS:**

(1) Log on at the SMJ website: <http://www.sma.org.sg/cme/smj> and select the appropriate set of questions. (2) Select your answers and provide your name, email address and MCR number. Click on "Submit answers" to submit.

**RESULTS:**

(1) Answers will be published in the SMJ March 2011 issue. (2) The MCR numbers of successful candidates will be posted online at [www.sma.org.sg/cme/smj](http://www.sma.org.sg/cme/smj) by 7 March 2011. (3) All online submissions will receive an automatic email acknowledgment. (4) Passing mark is 60%. No mark will be deducted for incorrect answers. (5) The SMJ editorial office will submit the list of successful candidates to the Singapore Medical Council.

**Deadline for submission: (January 2011 SMJ 3B CME programme): 12 noon, 28 February 2011.**