

# Pulmonary *Scopulariopsis* in a chronic tobacco smoker

Satyavani M, Viswanathan R, Harun N S, Mathew L

## ABSTRACT

**A 70-year-old male smoker, with a three-month status of post-balloon angioplasty for ischaemic heart disease, presented with a one-week history of fever, haemoptysis and chest discomfort on coughing. The patient did not report any loss of weight or appetite. On examination, he was febrile. Pulmonary function tests revealed obstructive airway disease. High resolution computed tomography of the lungs revealed fibrosis with bronchiectasis in both the upper lobes and a spiculating subpleural mass in the posterior aspect of the right lung apex. Subsequent bronchoalveolar lavage (BAL) culture yielded the *Scopulariopsis* species. Our patient was treated with a four-week course of amphotericin B, followed by itraconazole. At the 24-month follow-up, the patient was asymptomatic. Subsequent BAL cultures revealed no fungal growths, and radiological studies showed a regression in the lesion.**

**Keywords:** pulmonary, *Scopulariopsis*, tobacco smoker

*Singapore Med J* 2010; 51(8): e137-e139

## INTRODUCTION

Pulmonary infections due to *Scopulariopsis* have been reported, especially in immunocompromised patients. We report a rare instance of *Scopulariopsis* in the lung of an immunocompetent tobacco smoker.

## CASE REPORT

A non-alcoholic, 70-year-old male smoker for the last 50 years (20 sticks of cigarettes per day), who had ischaemic heart disease and balloon angioplasty performed three months earlier, presented to the hospital with a history of fever, haemoptysis and chest discomfort on coughing for a period of one week. Haemoptysis initially consisted of speckled blood mixed with sputum. At the time of presentation, frank blood was found in the sputum. The patient also complained of mild intermittent giddiness. No loss of weight or appetite was reported.

On examination, the patient was febrile. The jugular venous pressure was raised. The examination of the respiratory system was normal, but a right supraclavicular lymph node was palpable. The blood investigations revealed anaemia (haemoglobin 9.9 gm%) with normal white blood cell count. The differential count showed 51.9% neutrophils and 33.6% lymphocytes. The initial sputum that was sent for microscopy and culture yielded nothing significant.

High resolution computed tomography (CT) of the lung revealed fibro-bronchiectatic changes in both the upper lobes, with a spiculating subpleural mass and an eccentric cavity spot in the posterior aspect of the right lung apex. No radiological evidence of a fungal ball was observed in the cavitating lesion. CT-guided fine needle aspiration cytology revealed few inflammatory cells and no malignant cells or acid-fast bacilli (AFB) (Fig. 1a), while the pulmonary function test revealed obstructive airway disease. The echocardiography findings were normal. Bronchoscopy showed a blood clot in the posterior segment of the bronchus of the left upper lobe of the lung. Bronchoalveolar lavage (BAL) from this site was sent for cytological and microbiological assessment. On removal of the clot, no bleeding or endobronchial lesion was observed. Pleural biopsy was not done as the lesion was intrapulmonary. Cytological study of the bronchial aspirate revealed red blood cells, bronchoalveolar cells, acute inflammatory cells and pigmented histiocytes. Large numbers of branching septate fungal hyphae were also seen.

There was no evidence of malignant cells and AFB. On culture, *Klebsiella pneumoniae* was isolated from the BAL using the quantitative method, but the amount was less than 10<sup>4</sup> colonies, which was insignificant. Hence, no treatment was administered, as we did not consider the bacterium to be responsible for the lesion. The AFB culture performed using the Lowenstein-Jensen medium and the MGIT 960 System did not show any growth after six weeks. A cinnamon-coloured fungal growth was found, which was identified as *Scopulariopsis brevicaulis*, due to the presence of chains of rough and spiny thick-walled conidia on shorter conidiophores (Fig. 2) that

Department of  
Laboratory Services,  
Raja Isteri Pengiran  
Anak Saleha Hospital,  
Ministry of Health,  
Bandar Seri Begawan,  
BA 1710  
Brunei Darussalam

Satyavani M, MD  
Senior Medical Officer

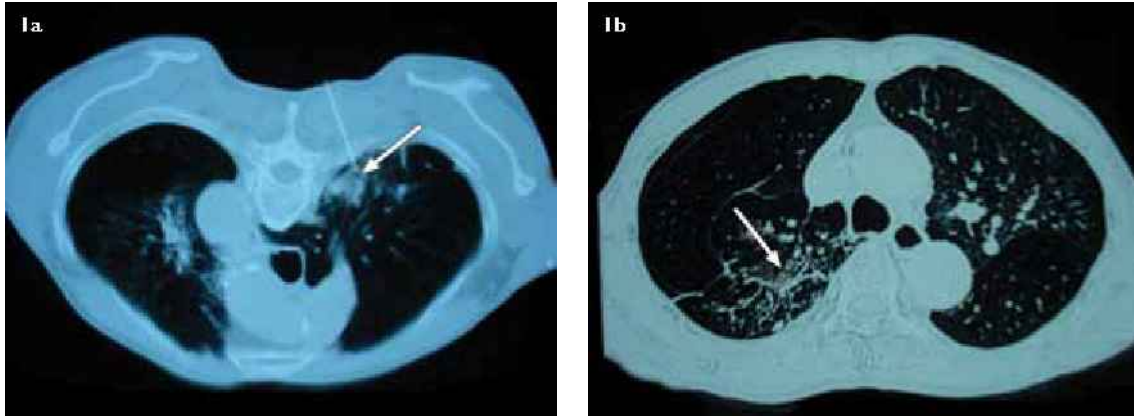
Viswanathan R, MD,  
DNBE, FRCPPath  
Clinical Microbiologist  
and Infection Control  
Doctor

Department of  
Respiratory medicine

Harun NS, BMBS,  
MRCP  
Senior Medical Officer

Mathew L, MD, MRCP  
Specialist

**Correspondence to:**  
Dr Roopa Viswanathan  
Tel: (673) 8163344  
Fax: (673) 2455340  
Email: ruvishy@  
rediffmail.com



**Fig. 1** (a) CT image shows the fine needle aspiration cytology needle (arrow) in the lesion of the lung (posteroanterior view). (b) CT image shows resolution of the lesion (arrow) in the lung at 24 months after the diagnosis and treatment with antifungal agents for six weeks (anteroposterior view).

were repeatedly isolated from subsequent sputum specimens as well.

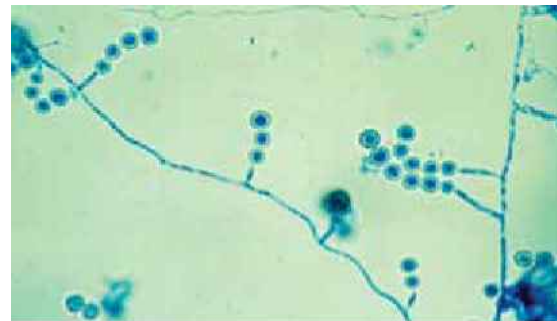The patient was treated with amphotericin B for four weeks. As his renal parameters were deranged, the treatment was changed to oral itraconazole for another two weeks. The subsequent follow-up was uneventful, and the follow-up CT (Fig. 1b) showed a resolution of the left apical lesion with fibrotic scarring. The patient has been asymptomatic for the past 24 months, and has quit smoking since the diagnosis.

## DISCUSSION

Members of the genus *Scopulariopsis* are common soil fungi. Most commonly, they are implicated in onychomycosis.<sup>(1)</sup> There have also been reports of otomycosis, keratitis, prosthetic valve endocarditis, sinusitis, brain abscess, and cutaneous, subcutaneous and bone invasions by these pathogens in both immunocompetent as well as immunosuppressed individuals.<sup>(2)</sup>

*Scopulariopsis* has recently emerged as one of the fungal pathogens in pulmonary diseases.<sup>(3)</sup> Pulmonary *Scopulariopsis* has been reported in lung transplant<sup>(4)</sup> and in orthotopic heart-lung transplant patients.<sup>(5)</sup> *Scopulariopsis* fungal ball from the right middle lung lobe has been resected in a 67-year-old woman.<sup>(6)</sup> Invasive infection due to *Scopulariopsis brevicaulis* has been diagnosed in a stem cell transplant patient as well.<sup>(7)</sup> Pulmonary infections could be caused by inhalation of the mould, leading to the lodging of the organism, which results in granulomatous reaction in an immunocompromised patient. *Scopulariopsis* rarely causes pulmonary disease in immunocompetent patients.

In the present case, we speculated that the tobacco that the immunocompetent patient used to smoke for the past



**Fig. 2** Photomicrograph of the culture shows chains of thick-walled conidia, characteristic of *Scopulariopsis* spp. (Lactophenol cotton blue,  $\times 10$ ).

50 years could have been responsible for the lesion. The tobacco moulds used for making the bidis, a local form of cigarettes in the Indian subcontinent, contain *Aspergillus* or *Scopulariopsis*, which can lead to the formation of non-necrotising granulomas.<sup>(8)</sup> However, our patient did not have any occupational exposure. The fungal cultures from his home walls and his car air-conditioning vents did not yield any fungal growth. Thus, it was unusual that pulmonary *Scopulariopsis* was found in an immunocompetent patient with no occupational exposure or agricultural hobbies.

Amphotericin B is the drug of choice for such infections; however, due to renal impairment in our patient, the treatment was discontinued after four weeks and replaced with oral itraconazole. Although some *in vitro* anti-fungal susceptibility studies for *Scopulariopsis* isolates have shown its resistance to itraconazole,<sup>(9-11)</sup> in this case, the patient showed a good response and no resistance was observed, as was also reported by Patel et al.<sup>(5)</sup> The identification of *Scopulariopsis* would have been missed had the microbiological analysis not been performed. Hence, with the advent of emerging pathogens in pulmonary diseases, clinicians must resort to microbiological diagnosis for lung lesions, especially in chronic tobacco smokers.

## REFERENCES

1. Sigler L, Verweij PE. Aspergillus, fusarium and other opportunistic moniliaceous fungi. In: Murray PR, Baron EJ, Jorgensen JH, Pfaller MA, Tenover FC, Tenover FC, eds. *Manual of Clinical Microbiology*. 8th ed. Washington: ASM Press, 2003: 1727-60.
2. Larone DH. *Medically Important Fungi: A Guide to Identification*. 3rd ed. Washington: ASM Press, 1995: 195.
3. Sanchez A, Larson R. Emerging fungal pathogens in pulmonary disease. *Curr Opin Pulm Med* 2007; 13:199-204.
4. Wuyts WA, Molzahn H, Maertens J, et al. Fatal Scopulariopsis infection in a lung transplant recipient: a case report. *J Heart Lung Transplant* 2005; 24:2301-4.
5. Patel R, Gustaferra CA, Krom RA, et al. Phaeohiphomycosis due to Scopulariopsis brumptii in a liver transplant recipient. *Clin Infect Dis* 1994;19:198-200.
6. Endo S, Hironaka M, Murayama F, et al. Scopulariopsis fungus ball. *Ann Thorac Surg* 2002; 74:926-7.
7. Wagner D, Sander A, Bertz H, Finke J, Kern WV. Breakthrough invasive infection due to Debaryomyces hansenii (teleomorph Candida famata) and Scopulariopsis brevicaulis in a stem cell transplant patient receiving liposomal amphotericin B and caspofungin for suspected aspergillosis. *Infection* 2005; 33:397-400.
8. Bhisey RA, Bagwe AN, Mahimkar MB, Buch SC. Biological monitoring of bidi industry workers occupationally exposed to tobacco. *Toxicol Lett* 1999; 108:259-65.
9. Cuenca-Estrella M, Gomez-Lopez A, Buitrago MJ, et al. In vitro activities of 10 combinations of anti-fungal agents against the multiresistant pathogen Scopulariopsis brevicaulis. *Antimicrob Agents Chemother* 2006; 50:2248-50.
10. Cuenca-Estrella M, Gomez-Lopez A, Mellado E, et al. Scopulariopsis brevicaulis, a fungal pathogen resistant to broad-spectrum antifungal agents. *Antimicrob Agents Chemother* 2003; 47:2339-41.
11. Aguilar C, Pujol I, Guarro J. In vitro antifungal susceptibilities of Scopulariopsis isolates. *Antimicrob Agents Chemother* 1999; 43:1520-2.