

Thyroglossal duct carcinoma

Kahairi A, Ahmad R L, Wan Islah L, Hasmah H

ABSTRACT

We report a 56-year-old Malay woman with a tumour that involved the skin and caused hyoid bone erosion. There was no clinical or radiological evidence of regional lymph node involvement. A modified radical neck dissection with preservation of the accessory nerve and internal jugular vein was performed, followed by an “extended” Sistrunk operation. The surgical defect was reconstructed with a pectoralis major myocutaneous flap. Our literature review showed that this is the first reported thyroglossal duct carcinoma which involved the skin and required a pedicle flap reconstruction.

Keywords: hyoid bone lesion, thyroglossal duct carcinoma, thyroid gland carcinoma, thyroidectomy

Singapore Med J 2009; 50(12):e404-e406

INTRODUCTION

Thyroglossal duct carcinoma (TGD Ca) is a rare tumour with only about 274 cases reported in the literature so far. The median age for TGD Ca is 40 years, with a few cases presenting before the age of 15 years, and women are affected more often than men. In the majority of the cases, the diagnosis was made after the surgical removal of a presumed benign thyroglossal duct cyst. The usual recommended treatment is a Sistrunk procedure, but controversies remain regarding the need for total thyroidectomy.

CASE REPORT

A 56-year-old Malay woman presented with a painless midline neck swelling of one year's duration, and reported that it was progressively increasing in size (Fig. 1). She started to have recurrent bleeding with ulceration of the swelling four months prior to her visit to the Ear, Nose and Throat (ENT) clinic. Apart from that, there was no history of loss of appetite, loss of weight, dysphagia and odynophagia, difficulty in breathing or voice change. On examination, there was an oval-shaped mass located at the upper part of the anterior neck, and it moved with swallowing as well as on tongue protrusion. There was an ulcerative lesion with some necrotic tissues over the mass, which was surrounded by an area

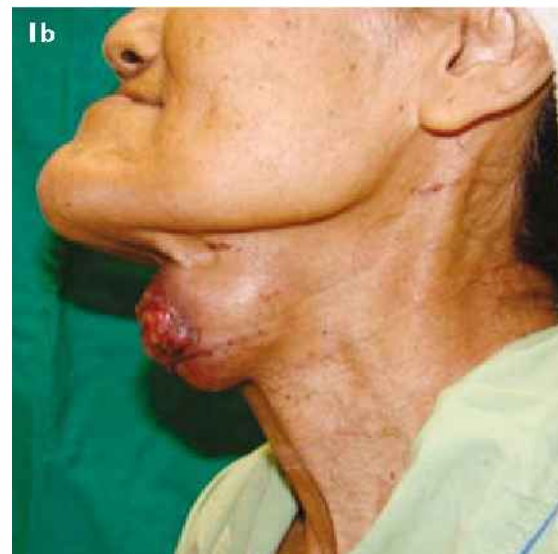
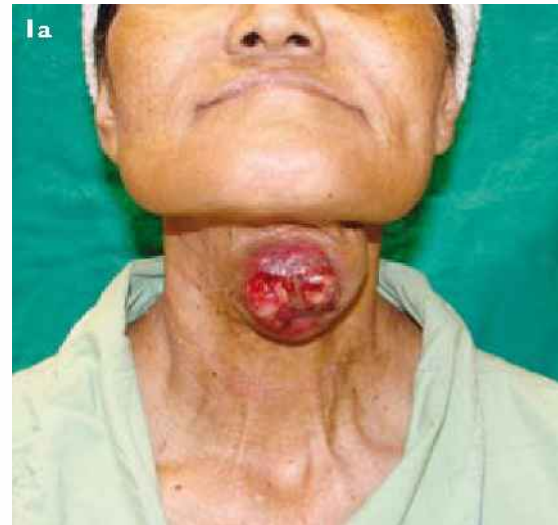
Fig. 1 Photographs taken in the (a) anterior and (b) lateral projections show an oval-shaped mass located at the upper part of the anterior neck, at the level of the hyoid bone. There was an area of ulceration with inflammation of the overlying skin.

of inflammation. Intraorally, tongue mobility was intact and no abnormality was observed at the base of tongue. Flexible nasopharyngolaryngoscopy revealed a mobile vocal cord, and no suspicious mass was seen.

As fine needle aspiration cytology was inconclusive, an incision biopsy was performed in the ulcerated area of the mass, and the diagnosis of papillary adenocarcinoma (Fig. 2) was confirmed. Her thyroid function test was within normal range, and other baseline blood investigations were also normal. Ultrasonography of the neck revealed a heterogeneous echogenic mass at

Department of
Otolaryngology –
Head & Neck
Surgery,
Faculty of
Medicine,
International
Islamic University
Malaysia,
Jalan Hospital,
Kuantan 25100,
Malaysia

Kahairi A, MBBS,
MMed
Assistant Professor

Ahmad RL, MD, MS
Associate Professor

Wan Islah L, MD, MS
Associate Professor

Department of
Pathology,
Hospital Tengku
Ampuan Afzan,
Kuantan,
Pahang 25100,
Malaysia

Hasmah H, MD,
MPath
Clinical Specialist

Correspondence to:
Dr Kahairi Abdullah
Tel: (60) 9 513 2797
Fax: (60) 9 513 3615
Email: kahairiabd@
yahoo.com.my

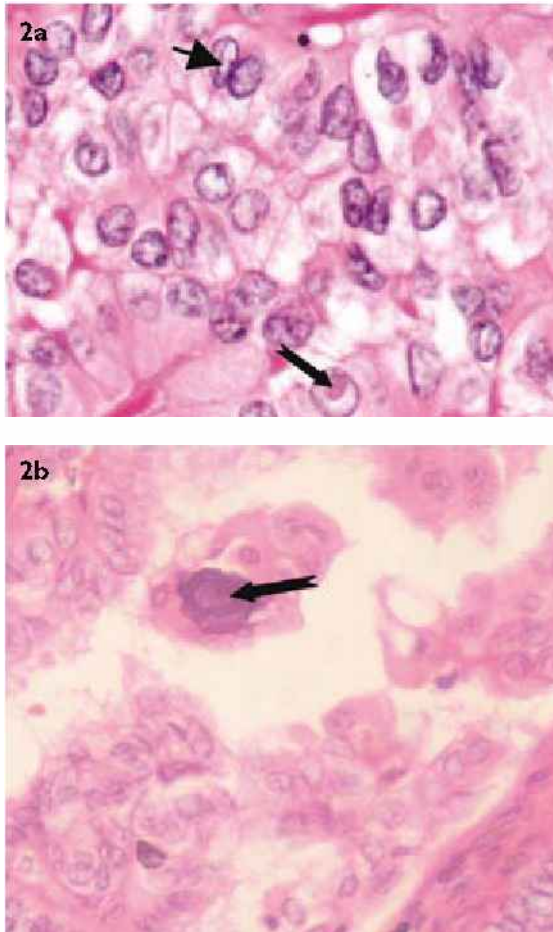


Fig. 2 Histological photomicrographs show (a) an intranuclear grooving (thin arrow) and intranuclear inclusion (notch arrow), and (b) a psammoma body (arrow) (Haematoxylin and eosin, $\times 40$).

the midline just above the thyroid region, measuring 2.7 cm \times 4.2 cm \times 3 cm, and it did not communicate with the thyroid gland. Computed tomography (CT) showed a heterogeneous mass at the submental region with local infiltration and hyoid bone erosion. However, a clear demarcation was seen between the mass and the thyroid gland, and there was no regional lymphadenopathy identified. On the sagittal view, a small portion of the mass extended into the tongue base.

Left modified radical neck dissection with preservation of the accessory nerve and internal jugular vein, "extended" sistrunk operation and pectoralis major myocutaneous flap reconstruction were performed. Intraoperatively, the tumour was not in contact with either lobe of the normal-looking thyroid gland, and palpation of the thyroid gland did not reveal any suspicious nodular mass. The postoperative recovery was uneventful, and follow-up at six and 12 months after surgery did not reveal any clinical evidence of tumour recurrence, and the serum thyroglobulin level was within normal range.

DISCUSSION

Embryologically, the analogue of the thyroid arises from the floor of the pharyngeal gut (foramen caecum) and descends as a bilobed diverticulum, which remains connected to the gut by a narrow canal, the thyroglossal duct. In the seventh to eighth week of development, the gland reaches its final position in front of the upper trachea, and the duct becomes obliterated.⁽¹⁾ However, in some circumstances, it fails to regress and resorb, and forms a thyroglossal duct cyst. This cyst may contain thyroid tissues and epithelial cells, and therefore, a tumour can arise from any of these cells. The risk factor for the development of carcinoma within this cyst is not well known.

The frequency of TGD Ca among surgically-removed TGD cysts is 0.7%.⁽²⁾ In 80% of the cases, the histological diagnosis is a papillary-type of carcinoma, followed by mixed papillary/follicular carcinoma (8%) and squamous cell carcinoma (6%). The other 6% include Hürthle cell, follicular and anaplastic carcinomas. In the majority of the cases, the diagnosis was made after the surgical removal of the presumed benign thyroglossal duct cysts. However, in this case, an incision biopsy was done from the ulcerated area of the mass, and the diagnosis of papillary adenocarcinoma was then confirmed.

Carcinoma arising in the thyroglossal duct cyst is extremely rare, based on a relatively small number of reported cases in the literature. Heshmati et al reported 187 cases from the literature, which were mainly contributed by Van Vuuren et al, who collected 158 cases.^(2,3) With the addition of 12 cases by Heshmati et al from their institution, a total of 199 cases had been reported up till April 1997. In a PubMed and Medscape search of reported cases between May 1997 and February 2008, we found 75 cases. Thus, with the addition of our current case, 275 cases of TGD carcinoma have been reported so far.

Our case gives a unique presentation of this rare tumour. Apart from the ulceration and recurrent bleeding of the mass four months prior to her visit to the ENT clinic, she did not complain of hoarseness, dysphagia or difficulty in breathing. The ulcerative lesion of the mass indicated skin involvement, and this, together with the erosion of the hyoid bone, indicated an advanced-stage tumour (T4). However, clinical and radiological examinations revealed no regional lymph node involvement, and this was confirmed by histopathological specimens that were taken from the left modified radical neck dissection, which included the lymph nodes from the submental region (Level I), Levels II, III and IV,

which were all tumour free. Van Vuuren et al reported that cervical nodal metastasis from papillary carcinoma in TGD occurred in 14.6% of the cases.⁽³⁾ Therefore, this case is rare as it involved a locally advanced and aggressive tumour without the involvement of regional lymph nodes. The usual Sistrunk procedure includes excision of the cyst in continuity with the midportion of the body of the hyoid bone, and a block of muscle that includes the thyroglossal duct remnant dissected up to the foramen caecum. However, in this case, a substantial amount of skin overlying the tumour with a 1–2 cm margin, the entire part of the hyoid bone and also a significant amount of muscle at the tongue base, were removed. Therefore, “extended” Sistrunk procedure was used in this case.

Controversies remain regarding the need to include the thyroid gland in the specimen. Because of the small case series, a majority of the studies found in the literature could not significantly highlight the importance of thyroid gland removal to improve the prognosis. The largest experience from a single institution was by Miccoli et al, involving 18 cases that were retrospectively studied, and the authors recommended total thyroidectomy in TGD Ca cases.⁽⁴⁾ Doshi et al reported 14 cases from their institution, and concluded that an evaluation of the thyroid gland and the neck intraoperatively was crucial to detect any potential abnormality that would necessitate thyroidectomy and lymph node dissection.⁽⁵⁾ However, Patel et al, in his retrospective study of 57 cases reported in the literature and five cases from his institution, concluded that the addition of total thyroidectomy to the Sistrunk operation did not have a significant impact on the outcome.⁽⁶⁾ Apart from that, total thyroidectomy was also known to be associated with morbidity, such as hypocalcaemia, as well as hypothyroidism and hypoparathyroidism. In this case, the thyroid gland was preserved, as the intraoperative finding of the gland did not indicate any suspicious mass. The pectoralis major myocutaneous flap is a good choice for reconstruction of the defect. However, care should be taken not to take a lot of tissue bulk (skin and muscle), as it can hide any thyroid recurrence.

The patient’s recovery was uneventful, and follow-up at six and 12 months showed that the patient was well and did not have any evidence of recurrence, clinically and radiologically. The serum thyroglobulin level for the tumour marker, taken at six months after surgery, was within the normal range. The recommended oncological follow-up should include clinical and ultrasonographical examinations three times during the first year, twice in the second year, and once yearly thereafter. Tumour marker evaluation and/or scintigraphy were performed six, 12 and/or 24 months following surgery.⁽⁷⁾

In conclusion, due of its rarity, a diagnosis of TGD Ca may be missed, and the treatment plan could have been different if the diagnosis was confirmed preoperatively. The tumour may behave in an aggressive manner locally, as in our case, and requires an extensive surgical procedure, including a pedicle flap reconstruction. Staging technique may be useful for this rare tumour, and guidelines can be drawn up so that the issues of whether or not to remove the thyroid gland can be established. Regular follow-up to detect any recurrence in the thyroid gland is mandatory, particularly in cases where the thyroid gland is preserved.

REFERENCES

1. Allard RH. The thyroglossal cyst. *Head Neck Surg* 1982; 5:134-46.
2. Heshmati HM, Fatourechi V, van Heerden JA, Hay ID, Goellner JR. Thyroglossal duct carcinoma: report of 12 cases. *Mayo Clin Proc* 1997; 72:315-9.
3. Van Vuuren PA, Balm AJ, Gregor RT, et al. Carcinoma arising in thyroglossal remnants. *Clin Otolaryngol Allied Sci* 1994; 19:509-15.
4. Miccoli P, Minuto MN, Galleri D, Puccini M, Berti P. Extent of surgery in thyroglossal duct carcinoma: reflections on a series of eighteen cases. *Thyroid* 2004; 14:121-3.
5. Doshi SV, Cruz RM, Hilsinger RL Jr. Thyroglossal duct carcinoma: a large case series. *Ann Otol Rhinol Laryngol* 2001; 110:734-8.
6. Patel SG, Escrig M, Shaha AR, Singh B, Shah JP. Management of well-differentiated thyroid carcinoma presenting within a thyroglossal duct cyst. *J Surg Oncol* 2002; 79:134-9.
7. Astl J, Dusková J, Kraus J, et al. Coincidence of thyroid tumor and thyroglossal duct remnants. Review of the literature and presentation of three cases. *Tumori* 2003; 89:314-20.