

Frontal mucocoele secondary to nasal polyposis: an unusual complication

Chew Y K, Noorizan Y, Khir A, Brito-Mutunayagam S, Prepageran N

ABSTRACT

The incidence of mucocoeles associated with a non-surgically treated nasal polyposis is rare. We report a rare case of nasal polyposis with asymptomatic frontal mucocoeles in a 28-year-old Malay man who presented with bilateral nasal obstruction with anosmia. Physical examination revealed bilateral grade III nasal polyps causing obstruction. Computed tomography revealed paranasal polyposis with a large polyp extending and expanding the posterior table of the frontal sinus causing erosion and thinning of its wall. Marsupialisation of the mucocoele and nasal polypectomy were done. Endoscopic sinus surgery and marsupialisation should be the treatment of choice for asymptomatic frontal mucocoele.

Keywords: frontal mucocoele, mucocoele marsupialisation, nasal polyposis

Singapore Med J 2009; 50(11): e374-e375

INTRODUCTION

Mucocoeles are defined as mucus-filled pseudocystic formations that are initially limited by bony walls which are expanded progressively. Mucocoeles of the frontal sinus are relatively uncommon lesions of a benign entity with equal frequencies for both genders. The incidence of mucocoeles associated with a non-surgically-treated nasal polyposis is rare (0.6%).⁽¹⁾ However, the mucocoeles usually behave like real space-occupying lesions that cause bone erosion and the displacement of surrounding structures. The proximity of mucocoeles to the brain may cause morbidity and potential mortality, if left without intervention.⁽²⁾ The aetiology of mucocoeles is multifactorial, which involve inflammation, allergy, trauma, anatomic abnormality, previous surgery, fibrous dysplasia, osteoma or ossifying fibroma. Nasal polyposis is associated with chronic inflammation and causes obstruction, and hence, is related to the occurrence of spontaneous or non-surgical-related mucocoeles.⁽¹⁾

The diagnosis of mucocoele and nasal polyposis is based on a clinical investigation conducted with the aid of computed tomography (CT) and magnetic resonance (MR) imaging. CT is used in determining the regional

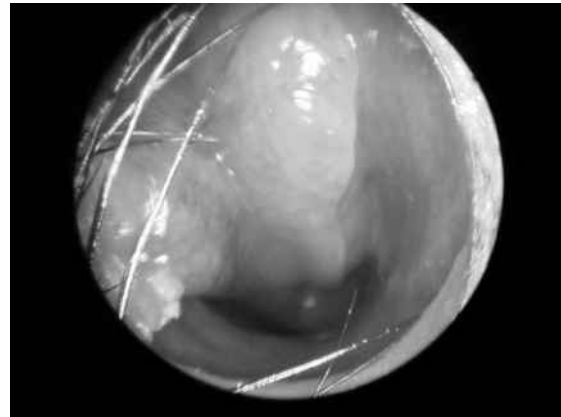


Fig. 1 Nasal endoscopic photograph shows the nasal polyposis.

anatomy and extent of the lesion, specifically the intracranial extension and the bony erosion. MR imaging is useful in differentiating mucocoeles from neoplasms via contrast enhancement.⁽³⁾ The mainstay of management of nasal polyposis with mucocoeles is surgery, which ranges from functional endoscopic sinus surgery to craniotomy, and craniofacial exposure, with or without obliteration of the sinus.⁽³⁾

CASE REPORT

A 28-year-old Malay man presented with bilateral nasal obstruction with anosmia to the Department of Otorhinolaryngology of Hospital Pakar Sultanah Fatimah, Malaysia. The symptoms progressively worsened during the past two years. He had a history of allergy to seafood. Physical examination revealed bilateral grade III nasal polyps causing obstruction (Fig. 1). There was no facial asymmetry or facial swelling. He was planned for bilateral polypectomy and functional endoscopic sinus surgery. CT and MR imaging which were done to assess the paranasal sinuses involvement prior to the surgery, revealed paranasal polyposis with a large polyp extending and expanding the posterior table frontal sinus, causing erosion and thinning of its wall (Figs. 2 & 3). In view of the cranial involvement, the patient was referred to University Malaya Medical Centre for surgery. Marsupialisation of the mucocoele and nasal polypectomy were done. Postoperatively, the patient was well and there was no recurrence of the mucocoeles and nasal polyps during the follow-up at one year.

Department of
Otorhinolaryngology,
Hospital Pakar
Sultanah Fatimah,
Jalan Salleh,
Muar 84000,
Malaysia

Chew Y K, MBBS
Master Trainee

Noorizan Y, MBBCh
Registrar

Khir A, MD, MS
Consultant

Brito-Mutunayagam S,
MBBS, MS
Consultant

Department of
Otorhinolaryngology,
University of Malaya,
Lembah Pantai,
Kuala Lumpur 59100,
Malaysia

Prepageran N, MBBS,
FRCS
Senior Consultant

Correspondence to:
Dr Chew Yok Kuan
Tel: (60) 6 952 1901
ext 119
Fax: (60) 6 952 3642
Email: chewyokkuan@
gmail.com

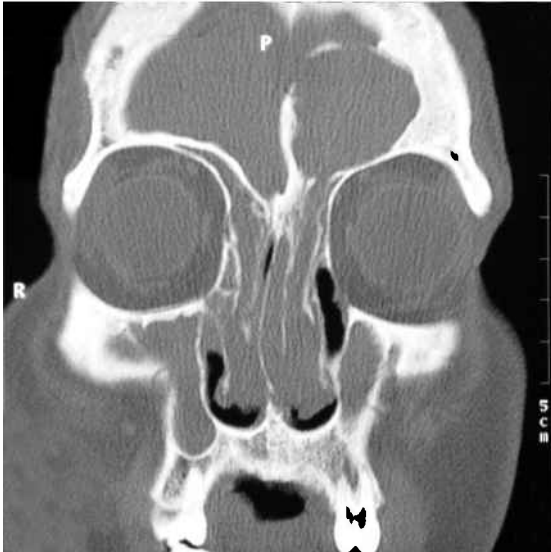


Fig. 2 Coronal CT shows the left frontal mucocoele.

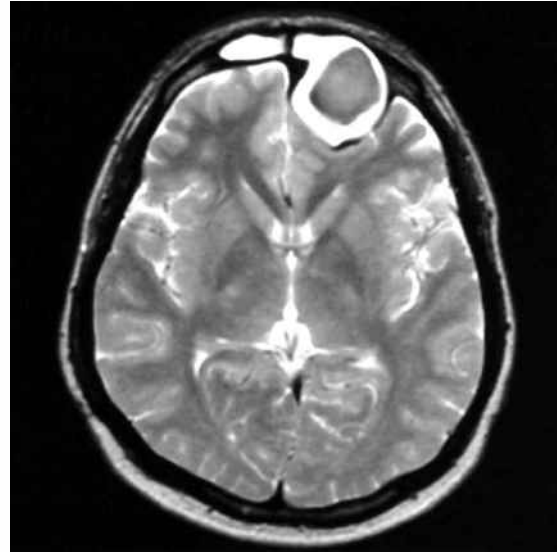


Fig. 3 Axial T2-W MR image shows the left frontal mucocoele

DISCUSSION

Mucocoeles are benign, slow-growing lesions that occur most commonly in the frontal and ethmoid sinuses. Mucocoeles usually arise due to sinus ostium obstruction, preceded by infection, fibrosis, inflammation, trauma, surgery or tumours such as osteomas. The risk of developing spontaneous mucocoele in association with a nasal polyposis is 0.6%.⁽¹⁾ Nasal polyposis is an inflammatory condition, and hence its role in mucocoele formation has to be considered. Polyps can cause obstruction, and the diseased mucosa which gets inflamed repeatedly favours the formation of mucocoeles. Studies have found high levels of prostaglandin E₂, which appears to play a major role in the osteolytic process in mucocoeles and explains the locally-aggressive behaviour of these expanding masses.⁽¹⁾ As in this case, the patient developed a left frontal mucocoele with bony erosion and bilateral nasal polyposis.

The clinical presentation of mucocoeles varies with their anatomical site. The onset of symptoms is usually insidious. Patients with frontoethmoidal mucocoeles may develop frontal headache, facial asymmetry or swelling, as well as ophthalmological manifestations, such as impaired visual acuity, reduced ocular mobility or proptosis. The mucocoele was an incidental finding during CT imaging in this case, and a diagnosis of mucocoele at an early stage helped to reduce the morbidity to the patient. CT of the paranasal sinuses is a valuable tool for the diagnosis of mucocoeles and the evaluation of their intracranial expansion. On CT images, the mucocoeles

were shown as homogeneous isodense lesions that do not enhance, as in this case. MR imaging is useful in differentiating mucocoeles from neoplasms by using contrast enhancement.⁽⁴⁾ MR imaging was done for this patient to further confirm the diagnosis.

The aim of treatment of mucocoeles is to marsupialise them effectively.⁽⁴⁾ With the advent and development of endoscopic sinus surgery, the radical procedure has given way to a more functional intervention which is minimally invasive, preserves sinus architecture and notably, leaves no facial scarring. As in this case, the patient underwent marsupialisation of the mucocoele and nasal polypectomy via nasal endoscopy.

In conclusion, the risk of mucocoeles in non-surgically treated polyposis is low; however, it is still a predisposing factor for the development of mucocoeles, as it is characterised by a degranulation and phagocytic process in inflammatory processes and polyps that could cause drainage obstruction. Endoscopic sinus surgery and marsupialisation should be the treatment of choice for asymptomatic frontal mucocoele.

REFERENCES

1. Chobillion MA, Jankowski R. Relationship between mucocoeles, nasal polyposis and nasalisation. *Rhinology* 2004; 43:219-24.
2. Weitzel EK, Hollier LH, Calzada G, Manolidis S. Single stage management of complex fronto-orbital mucocoeles. *J Craniofac Surg* 2002; 13:739-45.
3. Galiè M, Mandrioli S, Tieghi R, Clauser L. Giant mucocoele of the frontal sinus. *J Craniofac Surg* 2005; 16:933-5.
4. Kawaguchi S, Sakaki T, Okuno S, Ida Y, Nishi N. Giant frontal mucocoele extending into the anterior cranial fossa. *J Clin Neurosci* 2002; 9:86-8.