

# <sup>123</sup>I-BMIPP fatty acid analogue imaging is a novel diagnostic and prognostic approach following acute myocardial infarction

Biswas S K, Sarai M, Hishida H, Ozaki Y

## ABSTRACT

Fatty acid oxidation is the most efficient mode of myocardial energy production which requires a large amount of oxygen. Thus, alteration of fatty acid oxidation is considered to be a sensitive marker of ischaemia and myocardial damage. <sup>123</sup>I-BMIPP (<sup>123</sup>I-β-methyl-p-iodophenylpentadecanoic acid) is a newly-investigated single-photon branching free fatty acid radiopharmaceutical with slow metabolism; thus, it is well-suited for single-photon emission computed tomography (SPECT). Assessment of fatty acid metabolism by radionuclide techniques has a potential role for the early detection of myocardial ischaemia and the assessment of the severity of ischaemic heart disease. Although stable patients with a healed myocardial infarction may have a relatively good prognosis, risk stratification in the predischARGE period should be valuable for deciding upon appropriate management. In this respect, the presence of discordant BMIPP uptake relative to <sup>201</sup>Tl perfusion appears to be the best predictor of future cardiac events among all other cardiovascular imaging modalities. Since discordant BMIPP uptake correlates well with redistribution on stress <sup>201</sup>Tl imaging and perfusion-metabolism mismatch on positron emission tomography, it is considered that such BMIPP and <sup>201</sup>Tl discordance may identify a high-risk subgroup among patients with acute myocardial infarction. A BMIPP scan may reflect prior severe ischaemia after recovery of perfusion, the so-called "ischaemic memory". Gated BMIPP SPECT has been recently introduced for simultaneous assessment of myocardial metabolism and ventricular function. Such a new technique seems to be valuable for a better understanding of the pathophysiological state of heart failure and cardiomyopathy.

**Keywords:** acute myocardial infarction, β-methyl-p-iodophenylpentadecanoic acid scan, fatty acid metabolism, ischaemic memory

*Singapore Med J 2009; 50(10): 943-948*

## INTRODUCTION

Glucose and free fatty acids (FFA) are major energy sources of the myocardium. Long-chain fatty acids are the principal energy source for the normally-oxidised myocardium and are rapidly metabolised by β-oxidation. Approximately 60%–80% of the adenosine triphosphate produced in aerobic myocardium is derived from fatty acid oxidation.<sup>(1)</sup> With ischaemia, energy metabolism shifts to anaerobic metabolism, and the main energy substrate changes from FFAs to glucose metabolism. Radiolabelled fatty acids can be used to image myocardial aerobic metabolism.<sup>(2)</sup> For single-photon emission computed tomography (SPECT), several iodinated fatty acid tracers have been introduced and studied. Of these, <sup>123</sup>I-β-methyl-p-iodophenylpentadecanoic acid (BMIPP) has been the most commonly-used tracer in clinical studies, especially in some European countries as well as Japan.<sup>(3)</sup> This imaging modality provides invaluable information of ischaemic heart disease, cardiomyopathy and heart failure. The BMIPP scan is preferable because it can provide suitable information for risk stratification just after an acute myocardial infarction (AMI) without requiring the patient to exercise; it can also detect previous ischaemic insult even after recovery of myocardial perfusion, the so-called "ischaemic memory". The aim of this review was to highlight the uniqueness and feasibility of this sophisticated myocardial imaging technique for the evaluation of fatty acid metabolism following AMI.

## EVOLUTION OF FATTY ACID RADIO-PHARMACEUTICALS

Numerous radiolabelled pharmaceuticals have been used to evaluate myocardial metabolism *in vivo* either by positron emission tomography (PET) or SPECT. Iodine-123 (<sup>123</sup>I) is an appropriate isotope, because it is suitable

Cardiology Division,  
Department of  
Internal Medicine,  
Fujita Health  
University Hospital,  
1-98 Dengakugakubo,  
Kutsukake-cho,  
Toyoake,  
Aichi 470-1192,  
Japan

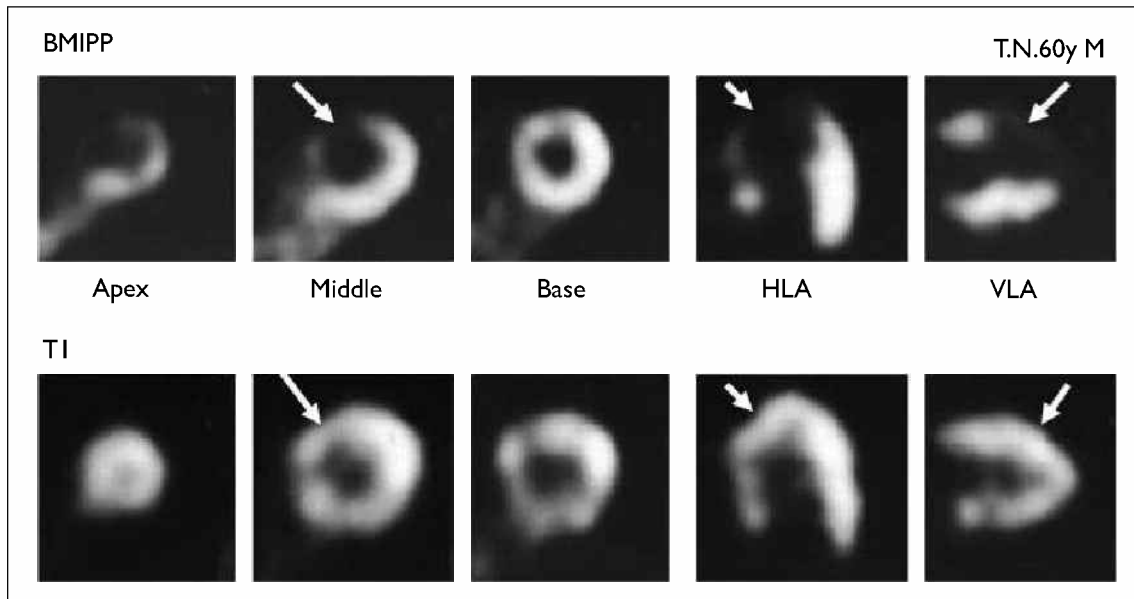
Biswas SK, MBBS,  
MPhil, PhD  
Clinical Research  
Fellow

Sarai M, MD, PhD  
Assistant Professor

Hishida H, MD, PhD  
Professor

Ozaki Y, MD, PhD  
Professor and Head

**Correspondence to:**  
Dr Shankar Kumar  
Biswas  
Tel: (81) 562 932 312  
Fax: (81) 562 932 315  
Email: biswas\_70@  
yahoo.com



**Fig. 1** A 60-year-old patient presented with an anteroseptal acute myocardial infarction. BMIPP and thallium imaging at seven days after PCI show a decreased BMIPP uptake in the anteroseptal and apical regions, but thallium uptake was almost normal.

for labelling with metabolic substrates and relatively easy to use with a conventional gamma camera.<sup>(4-6)</sup> There are two groups of iodinated fatty acid compounds, viz. straight-chain fatty acids and modified branched-chain fatty acids. The straight-chain fatty acids are generally metabolised via  $\beta$ -oxidation and released from the myocardium, e.g.  $^{123}\text{I}$ -15-(iodophenyl)pentadecanoic acid (IPPA). Conversely, modified fatty acids are used, based on the concept of myocardial retention due to metabolite trapping, eg. BMIPP. Uses of these agents allow excellent myocardial images to be obtained with a longer acquisition time.<sup>(1)</sup> 3-methyl-branched fatty acids are metabolised in the peroxisomes by an initial  $\alpha$ -oxidation followed by paroxysmal  $\beta$ -oxidation, a process that is slower than the mitochondrial  $\beta$ -oxidation.<sup>(7)</sup> This principle was first utilised by Knapp et al by the introduction of  $^{123}\text{I}$ -BMIPP.<sup>(8)</sup> The uniqueness of this radiopharmaceutical is that it can demonstrate a persistent disturbance of fatty acid metabolism, even when blood flow has been reestablished, such as with unstable angina and stunned myocardium.<sup>(2)</sup>

#### IMAGING TECHNIQUE

BMIPP shows rapid and high myocardial uptake with a long retention and low background. Low uptake is noted in the liver and lungs, even at 60 minutes after the injection. High-quality myocardial SPECT images can be obtained approximately within 20 minutes. Generally, BMIPP is injected in the fasting state and uptake is similar to thallium perfusion. Regional BMIPP uptake is also compared with regional perfusion to detect the presence of a perfusion-metabolism mismatch. Less BMIPP uptake than perfusion

(discordant BMIPP uptake) is often observed in ischaemic myocardium.<sup>(1)</sup> In sequential dynamic SPECT imaging with a triple-headed gamma camera, it was found that the initial distribution was similar to perfusion and the 20–30-minute images may reflect more metabolic function. Therefore, an early image of the BMIPP scan (at 20 minutes) might provide both perfusion and metabolism of the myocardium, and ameliorate the use of an extra perfusion tracer, e.g. thallium ( $^{201}\text{Tl}$ ) or tetrofosmin.<sup>(9,10)</sup> Greater BMIPP uptake than thallium perfusion is occasionally observed in septal and inferior regions in normal subjects, probably due to the greater photon attenuation of  $^{201}\text{Tl}$  in these areas. The importance of scatter correction is noted for accurate estimation of such areas on the BMIPP scan.<sup>(11)</sup>

#### UNIQUE ROLE FOR THE EVALUATION OF MYOCARDIAL INFARCTION

Several studies have focused on assessing perfusion and metabolic changes in patients with AMI after successful coronary intervention. The defect size on BMIPP SPECT myocardial scintigraphy may stratify the area at risk, even if it is performed several days after myocardial infarction (MI).<sup>(12-14)</sup> This imaging can provide unique intracellular information which cannot be obtained by angiographical, perfusional or other functional analysis. BMIPP and perfusion imaging in patients with AMI have demonstrated three different correlations between myocardial perfusion and fatty acid metabolism: (1) Concordant defects in perfusion and BMIPP scan represent a scar or non-viable tissue. (2) Lower BMIPP uptake relative to perfusion (perfusion-metabolism mismatch) implicates

a metabolically-damaged, often dysnergic, but viable myocardium (Fig. 1). (3) Equivalently-normal uptake of the radiotracer in perfusion and BMIPP scan represent a completely salvaged myocardium. Identification of these perfusion-metabolism correlations contribute to the prediction of an ischaemia-related myocardial injury, post-interventional functional recovery of the myocardium, and patients who have myocardium at ischaemic risk.<sup>(15)</sup>

In patients with AMI, less BMIPP uptake than <sup>201</sup>Tl is often seen in those patients who have myocardial wall motion abnormalities relative to perfusion abnormality.<sup>(16)</sup> Less BMIPP uptake than <sup>99m</sup>Tc-sestamibi in subacute MI was also reported in a European group.<sup>(17,18)</sup> The areas of difference between the perfusion and fatty acid metabolic abnormalities in the subacute phase of MI after revascularisation correlated with the amount of salvaged myocardium.<sup>(19)</sup> Many other investigators observed that the areas of less BMIPP uptake, compared to perfusion in the acute and subacute phases of MI, had improvement in wall motion abnormalities in the follow-up study.<sup>(20-25)</sup> BMIPP abnormalities may persist even after recovery of the regional wall motion. Such persistent abnormalities may be associated with a persistent increase in the fluorodeoxyglucose (FDG) uptake, supporting the theory that the abnormal BMIPP uptake after revascularisation may be the result of metabolic alterations.<sup>(26)</sup> The delayed recovery of metabolic function is often seen after recovery of perfusion.<sup>(21,27)</sup>

Transient left ventricular (LV) dysfunction, mimicking AMI with normal coronary arteries, has recently been documented in Japan; this disease has been named Tako-tsubo-like LV dysfunction.<sup>(28)</sup> Angiographical studies show LV asynergy in the apical region, but this asynergy dramatically resolved in a short time. This disease often showed a reduced BMIPP uptake but an almost normal perfusion in the regions of asynergy, and a slow recovery of BMIPP uptake with recovery from asynergy in the apical regions.<sup>(29)</sup> These findings may suggest that the transient LV dysfunction in this peculiar disease may essentially be a stunned myocardium.<sup>(1)</sup>

#### **TIME INTERVAL AFTER MI AND CARDIAC SCAN FOR BETTER INTERPRETATION OF DISCORDANT FATTY ACID METABOLISM AND PERFUSION**

Higuchi et al investigated the impact of brief intervals of total coronary artery occlusion and reperfusion on the myocardial uptake of BMIPP for the precise interpretation of scintigraphic findings involving BMIPP and its comparison with <sup>201</sup>Tl uptake. They observed that BMIPP uptake in the area at risk transiently increased in the acute

phase (20 min and 1 d), decreased in the subacute phase (3 d and 7 d), and recovered in the chronic phase (30 d). In contrast, changes in perfusion were minimal from the acute phase to the chronic phase.<sup>(30)</sup> Therefore, distinct mismatches between perfusion and metabolism were observed in the area at risk in the acute and subacute phases. Discordance between BMIPP uptake and perfusion tracer uptake is associated with revascularisation after AMI.<sup>(31,32)</sup> However, higher BMIPP uptake is occasionally observed. In a chronically hypoperfused myocardium, an increased BMIPP uptake relative to perfusion was detected, which is different from the depressed BMIPP uptake often reported in sub-AMI.<sup>(33)</sup> Therefore, the interval from MI might be an important factor for the interpretation of BMIPP cardiac scintigraphic data.

#### **PROGNOSTIC VALUES OF THE BMIPP SCAN**

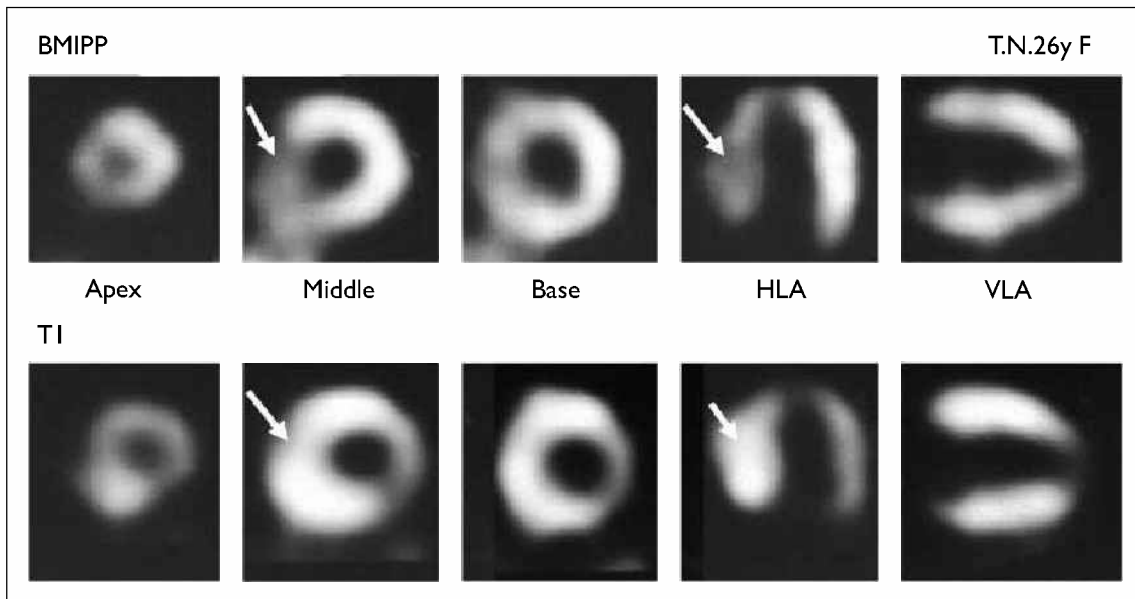
When treating patients with MI, it is well-established that those with LV dysfunction face a worse prognosis, compared to those with a preserved ventricular function.<sup>(34,35)</sup> For the prediction of prognosis, previous studies have suggested that the BMIPP scan is useful for the evaluation of a functional recovery of the myocardium.<sup>(36,37)</sup> Since discordant BMIPP and <sup>201</sup>Tl uptake correlate well with redistribution of <sup>201</sup>Tl on stress imaging and perfusion-metabolism mismatch on PET, it is considered that such a discordant uptake of these two tracers on myocardial SPECT scintigraphy might identify a high-risk subgroup among the patients with AMI.<sup>(38-40)</sup>

#### **RISK STRATIFICATION**

BMIPP imaging as a means of risk stratification has several advantages. First, it is usually performed at rest without requiring the patient to exercise. Thus, BMIPP imaging can be applied even in the acute stage of MI and in patients with stable angina.<sup>(40)</sup> Second, discordant BMIPP uptake seems to be observed more often than redistribution on stress <sup>201</sup>Tl images.<sup>(38)</sup> It has been observed that the discordant BMIPP uptake is a better predictor of cardiac events than <sup>201</sup>Tl reversibility, and Cox regression analysis showed the presence of discordant BMIPP uptake to be the best (and an independent) predictor of future cardiac events. Third, BMIPP imaging provides metabolic information in a routine clinical setting without requiring the use of an expensive positron camera.<sup>(40)</sup>

#### **LIMITATION FOR THE ASSESSMENT OF MYOCARDIAL VIABILITY**

PET is considered to be the gold standard for the noninvasive detection of viability with nuclear cardiology techniques,<sup>(41)</sup> and it is noteworthy that a metabolic



**Fig. 2** A 26-year-old female patient presented with hypertrophic cardiomyopathy (HCM). On BMIPP and thallium scans, there is a strikingly decreased uptake of BMIPP but almost normal uptake of thallium in the septum. This is the typical finding of HCM.

mismatch (glucose/fatty acid mismatch) is superior to a metabolic/perfusion mismatch (FDG/MIBI or BMIPP/MIBI) for an accurate prediction of the regional and global functional recovery after revascularisation. Therefore, revascularisation of the myocardium with a higher metabolic mismatch will be expected to have a more beneficial effect.<sup>(42)</sup>

#### ASSESSMENT OF MYOCARDIAL ISCHAEMIA

The supply and demand for myocardial blood flow are balanced through the myocardial flow reserve (MFR) in chronic stable angina. The increased demand beyond the adjustable range of MFR results in myocardial ischaemia. In the ischaemic condition, both substrate and oxygen are insufficient; in such circumstances, oxygen insufficiency preceded substrate insufficiency in all tissues, including the myocardium. In other words, myocardial ischaemia is regarded as a relative hypoxia.<sup>(43)</sup> Hypoxia inhibits the activity of peroxisome proliferator-activated receptor- $\alpha$  (PPAR $\alpha$ ). Carnitine palmitoyltransferase-1 (CPT1), the rate-limiting enzyme for long-chain fatty acid oxidation in the mitochondria, and mitochondrial fatty acid  $\beta$ -oxidation (FAO) are regulated by PPAR $\alpha$ .<sup>(44)</sup> Repetitive hypoxia due to reduced MFR possibly decreases the activity of PPAR $\alpha$ , thus fatty acid metabolism shifts to glucose metabolism.<sup>(45)</sup>

Less BMIPP uptake than perfusion may be the result of a delayed recovery of metabolism after recovery of perfusion, or stunning. Thus, BMIPP may reflect prior severe ischaemia after recovery of perfusion, i.e. so-called "ischaemic memory".<sup>(6,13)</sup> This phenomenon can

be better explained with Fig. 1. Occlusion-reperfusion canine studies with chronic ischaemia suggest prolonged metabolic alteration over four weeks after 30 minutes of coronary occlusion, which is associated with sustained myocardial dysfunction.<sup>(46)</sup> One meta-analysis indicated that BMIPP SPECT imaging at rest may provide quite acceptable sensitivity (74%) and high specificity (87%) for identifying coronary patients. Furthermore, the BMIPP abnormalities seem to be associated with unstable angina, regional wall motion abnormalities, and electrocardiographical abnormalities.<sup>(47-50)</sup> Recently, one study applied both BMIPP and tetrofosmin perfusion SPECT imaging to patients with acute chest pain without evidence of AMI. It was revealed that BMIPP imaging was more sensitive for detecting organic stenosis and coronary spasm (74%) than tetrofosmin imaging (38%) ( $p < 0.001$ ) and the specificity of BMIPP was greater than 90% in patients with acute chest pain with normal coronary angiography.<sup>(19)</sup>

#### POTENTIAL LIMITATIONS

BMIPP imaging generally requires <sup>201</sup>Tl imaging for the precise evaluation of differences in perfusion and fatty acid metabolism. A decrease in BMIPP uptake suggests changes in the fatty acid metabolism. However, it may not differentiate an ischaemic myocardium from a myocardial scar.<sup>(40)</sup> No method has yet been established for the quantification of BMIPP uptake. However, visual assessment is unavoidable because attenuation correction is not available for SPECT and it provides only a relative display of tracer uptake. Thus, breast attenuation and

diaphragmatic attenuation cause an underestimation of BMIPP uptake.<sup>(43)</sup>

### PROMISING ROLE OF THE BMIPP SCAN

BMIPP imaging may play a promising role for assessing the pathophysiology, development and worsening of heart failure.<sup>(41)</sup> In the canine model of heart failure produced by rapid heart pacing, a significant reduction of BMIPP uptake was observed in relation to the reduction of cardiac output and ejection fraction (EF).<sup>(50)</sup> Gated BMIPP SPECT has been introduced for the simultaneous assessment of myocardial metabolism and contractile reserve, viz. wall motion, EF, end-diastolic and end-systolic volumes.<sup>(51,52)</sup> Such a new technique seems to be valuable for the better understanding of the pathophysiological state in patients with heart failure. One of the clinical potentials of metabolic imaging is the differentiation of ischaemic cardiomyopathy from primary dilated cardiomyopathy as both diseases share similar features, such as chronic heart failure, diffuse hypokinesis, and markedly-decreased LV EF.<sup>(41)</sup>

Another important feature of metabolic imaging is to provide a treatment strategy for patients with chronic heart failure. The decrease in the BMIPP uptake in patients with dilated cardiomyopathy may be a poor responder for beta-blocker therapy, whereas those with a relatively-preserved BMIPP uptake may respond well to the therapy on the basis that a severely-injured myocardium may be least likely to respond to the medical treatment.<sup>(53)</sup> BMIPP has been extensively studied in patients with hypertrophic cardiomyopathy in Japan, including at this institute. A heterogeneous distribution of BMIPP is commonly observed in hypertrophied myocardium, independent of <sup>201</sup>Tl perfusion. Although the <sup>201</sup>Tl uptake is rather heterogeneous in a hypertrophied septal region, BMIPP uptake is strikingly decreased, indicating a perfusion-metabolism mismatch<sup>(54-56)</sup> (Fig. 2). Such a decrease in the BMIPP uptake is particularly prominent in the anteroseptal and posteroseptal junctions and the apical regions.<sup>(55)</sup>

### CONCLUSION

BMIPP imaging combined with perfusion imaging permits the detection of ischaemic and viable myocardium on the basis of alteration of myocardial fatty acid metabolism. The study of metabolic imaging has recently been focused on identifying post-ischaemic insult as "ischaemic memory imaging". Gated BMIPP SPECT is now also available, which can provide LV metabolic function as well as contractile functional reserve simultaneously. More research on this unique imaging technology that will expand the utilisation of fatty acid metabolic imaging

for the proper diagnosis and prognosis of ischaemic heart disease is required.

### REFERENCES

1. Tamaki N, Morita K, Kuge Y. Fatty acid imaging. In: Zaret BL, Beller GA, eds. *Clinical Nuclear Cardiology, State of Art and Future Directions*. 3rd ed. Philadelphia: Elsevier Mosby 2005: 559-72.
2. Ziessman HA, O'Malley JP, Thrall JH. Cardiac system. In: *Nuclear Medicine-The Requisites in Radiology*. 3rd ed. Philadelphia: Elsevier Mosby, 2006: 450-507.
3. Taki J, Matsunari I. Metabolic imaging using SPECT. *Eur J Nucl Med Mol Imaging* 2007; 34 Suppl 1:S34-48.
4. Knapp FF Jr, Kropp J. Iodine-123-labelled fatty acids for myocardial single photon emission tomography. Current status and future perspectives. *Eur J Nucl Med* 1995; 22:361-81.
5. Tamaki N, Fujibayashi Y, Magata Y, Yonekura Y, Konishi J. Radioisotope assessment of myocardial fatty acid metabolism by PET and SPECT. *J Nucl Cardiol* 1995; 2:256-66.
6. Tamaki N, Morita K, Kuge Y, Tsukamoto E. The role of fatty acids in cardiac imaging. *J Nucl Med* 2000; 41:1525-34.
7. Casteels M, Foulon V, Mannaerts GP, Van Veldhoven P. Alpha-oxidation of 3-methyl-substituted fatty acids and its thiamine dependence. *Eur J Biochem* 2003; 270:1619-27.
8. Knapp FF Jr, Ambrose KR, Goodman MM. New radioiodinated methyl branched fatty acids for cardiac studies. *Eur J Nucl Med* 1986; 12 Suppl:S39-44.
9. Kobayashi H, Kusakabe K, Momose M, et al. Evaluation of myocardial perfusion and fatty acid uptake using a single injection of iodine-123-BMIPP in patients with acute coronary syndromes. *J Nucl Med* 1998; 39:1117-22.
10. Matsunari I, Saga T, Taki J, et al. Kinetics of iodine-123-BMIPP in patients with prior myocardial infarction: assessment with dynamic rest and stress images compared with stress thallium-201 SPECT. *J Nucl Med* 1994; 35:1279-85.
11. Dobbeleir AA, Hambye ASE, Franken PR. Influence of methodology on the presence and extent of mismatching between <sup>99m</sup>Tc-MIBI and <sup>123</sup>I-BMIPP in myocardial viability studies. *J Nucl Med* 1999; 40:707-14.
12. Furutani Y, Shiigi T, Nakamura Y, et al. Quantification of area at risk in acute myocardial infarction by tomographic imaging. *J Nucl Med* 1997; 38:1875-82.
13. Kawai Y, Tsukamoto E, Nozaki Y, et al. Use of <sup>123</sup>I-BMIPP single-photon emission tomography to estimate areas at risk following successful revascularization in patients with acute myocardial infarction. *Eur J Nucl Med* 1998; 25:1390-5.
14. Tanaka R, Nakamura T. Time course evaluation of myocardial perfusion after reperfusion therapy by <sup>99m</sup>Tc-tetrofosmin SPECT in patients with acute myocardial infarction. *J Nucl Med* 2001; 42:1351-8.
15. Nakata T, Hashimoto A, Eguchi M. Cardiac BMIPP imaging in acute myocardial infarction. *Int J Card Imaging* 1999; 15:21-6.
16. Tamaki N, Kawamoto M, Yonekura Y, et al. Regional metabolic abnormality in relation to perfusion and wall motion in patients with myocardial infarction: assessment with emission tomography using an iodinated branched fatty acid. *J Nucl Med* 1992; 33:659-67.
17. De Geeter F, Franken P, Knapp FF Jr, Borruyt A. Relationship between blood flow and fatty acid metabolism in subacute myocardial infarction: a study by means of <sup>99m</sup>Tc-Sestamibi and <sup>123</sup>I-beta-methyl-iodo-phenyl pentadecanoic acid. *Eur J Nucl Med* 1994; 21:283-91.
18. Franken P, De Geeter F, Dendale P, et al. Abnormal free fatty acid uptake in subacute myocardial infarction after coronary thrombolysis: correlation with wall motion and inotropic reserve. *J Nucl Med* 1994; 35:1758-65.
19. Kawai Y, Tsukamoto E, Nozaki Y, et al. Significance of reduced uptake of iodinated fatty acid analogue for the evaluation

- of patients with acute chest pain. *J Am Coll Cardiol* 2001; 38:1888-94.
20. Franken PR, Dendale P, De Geeter F, et al. Prediction of functional outcome after myocardial infarction using BMIPP and sestamibi scintigraphy. *J Nucl Med* 1996; 37:718-22.
  21. Hambÿe AS, Vervaet A, Dobbeleir A, Dendale P, Franken P. Prediction of functional outcome by quantification of sestamibi and BMIPP after acute myocardial infarction. *Eur J Nucl Med* 2000; 27:1494-500.
  22. Hashimoto A, Nakata T, Tsuchihashi K, et al. Postischemic functional recovery and BMIPP uptake after primary percutaneous transluminal coronary angioplasty in acute myocardial infarction. *Am J Cardiol* 1996; 77:25-30.
  23. Ito T, Tanouchi J, Kato J, et al. Recovery of impaired left ventricular function in patients with acute myocardial infarction is predicted by the discordance in defect size on 123I-BMIPP and 201-Tl SPECT images. *Eur J Nucl Med* 1996; 23:917-23.
  24. Taki J, Kanajima K, Matsunari I, et al. Assessment of improvement of myocardial fatty acid uptake and function after revascularization using iodine-123-BMIPP. *J Nucl Med* 1997; 38:1503-10.
  25. Yoshida S, Ito M, Mitsunami K, Kinoshita M. Improved myocardial fatty acid metabolism after coronary angioplasty in chronic coronary artery disease. *J Nucl Med* 1998; 39:933-8.
  26. Murray G, Schad N, Ladd W, et al. Metabolic cardiac imaging in severe coronary disease: assessment of viability with iodine-123-iodophenylpentadecanoic acid and multicrystal gamma camera, and correlation with biopsy. *J Nucl Med* 1992; 33:1269-77.
  27. Tsubokawa A, Lee JD, Shimizu H, et al. Recovery of perfusion, glucose utilization and fatty acid utilization in stunned myocardium. *J Nucl Med* 1997; 38:1835-7.
  28. Tsuchihashi E, Ueshima K, Uchida T, et al. Transient left ventricular apical ballooning without coronary artery stenosis: a novel heart syndrome mimicking acute myocardial infarction. *Angina Pectoris-Myocardial Infarction Investigations in Japan. J Am Coll Cardiol* 2001; 38:11-8.
  29. Kurisu S, Inoue I, Kawagoe T, et al. Myocardial perfusion and fatty acid metabolism in patients with tako-tsubo-like left ventricular dysfunction. *J Am Coll Cardiol* 2003; 41:743-8.
  30. Higuchi T, Taki J, Nakajima K, et al. Time course of discordant BMIPP and thallium uptake after ischemia and reperfusion in a rat model. *J Nucl Med* 2005; 46:172-5.
  31. Mochizuki T, Murase K, Higashino H, et al. Ischemic "memory image" in acute myocardial infarction of 123I-BMIPP after reperfusion therapy: a comparison with 99mTc-pyrophosphate and 201Tl dual-isotope SPECT. *Ann Nucl Med* 2002; 16:563-8.
  32. Hashimoto A, Nakata T, Tsuchihashi K, et al. Postischemic functional recovery and BMIPP uptake after primary percutaneous transluminal coronary angioplasty in acute myocardial infarction. *Am J Cardiol* 1996; 77:25-30.
  33. Sloof GW, Visser FC, Bax JJ, et al. Increased uptake of iodine-123-BMIPP in chronic ischemic heart disease: comparison with fluorine-18-FDG SPECT. *J Nucl Med* 1998; 39:255-60.
  34. Hammermeister KE, DeRouen TA, Dodge HT. Variables predictive of survival in patients with coronary artery disease. Selection by univariate and multivariate analyses from the clinical, electrocardiographic, exercise, arteriographic, and quantitative angiographic evaluations. *Circulation* 1979; 59:421-30.
  35. Becker LC, Silverman KJ, Buckley BH, et al. Comparison of early thallium-201 scintigraphy and gated blood pool imaging for predicting mortality in patients with acute myocardial infarction. *Circulation* 1983; 67:1272-82.
  36. Hambye AS, Dobbeleir AA, Vervaet AM, Van den Heuvel PA, Franken PR. BMIPP imaging to improve the value of sestamibi scintigraphy for predicting functional outcome in severe chronic ischemic left ventricular dysfunction. *J Nucl Med* 1999; 40:1468-76.
  37. Hambye AS, Vervaet A, Dobbeleir A. Quantification of 99Tcm-sestamibi and 123I-BMIPP uptake for predicting functional outcome in chronically ischaemic dysfunctional myocardium. *Nucl Med Commun* 1999; 20:737-45.
  38. Kawamoto M, Tamaki N, Yonekura Y, et al. Combined study of I-123 fatty acid and thallium-201 to assess ischemic myocardium: comparison with thallium redistribution and glucose metabolism. *Ann Nucl Med* 1994; 8:47-54.
  39. Tamaki N, Kawamoto M. The use of iodinated free fatty acids for assessing fatty acid metabolism. *J Nucl Cardiol* 1994; 1(2 Pt 2): S72-8.
  40. Tamaki N, Tadamura E, Kudoh T, et al. Prognostic value of iodine-123 labelled BMIPP fatty acid analogue imaging in patients with myocardial infarction. *Eur J Nucl Med* 1996; 23:272-9.
  41. Schelbert HR. The usefulness of positron emission tomography. *Curr Probl Cardiol* 1998; 23:69-120.
  42. Sato H, Iwasaki T, Toyama T, Kaneko Y, Inoue T, Endo K. Prediction of functional recovery revascularization in coronary artery disease using (18)F-FDG and (123)I-BMIPP SPECT. *Chest* 2000; 117:65-72.
  43. Kageyama H, Morita K, Katoh C, et al. Reduced 123I-BMIPP uptake implies decreased myocardial flow reserve in patients with chronic stable angina. *Eur J Nucl Med Mol Imaging* 2006; 33:6-12.
  44. Huss JM, Levy FH, Kelly DP. Hypoxia inhibits the peroxisome proliferator-activated receptor alpha/retinoid X receptor gene regulatory pathway in cardiac myocytes: a mechanism for O<sub>2</sub>-dependent modulation of mitochondrial fatty acid oxidation. *J Biol Chem* 2001; 276:27605-12.
  45. Kim SJ, Peppas A, Hong SK et al. Persistent stunning induces myocardial hibernation and protection: flow/function and metabolic mechanisms. *Cir Res* 2003; 92:1233-39.
  46. Schwaiger M, Schelbert HR, Ellison D, et al. Sustained regional abnormalities in cardiac metabolism after transient ischemia in chronic dog model. *J Am Coll Cardiol* 1985; 6:336-47.
  47. Hambÿe AS, Vaerenberg MM, Dobbeleir AA, et al. Abnormal BMIPP uptake in chronically dysfunctional myocardial segments: correlation with contractile response to low-dose dobutamine. *J Nucl Med* 1998; 39:1845-50.
  48. Suzuki A, Takada Y, Nagasaka M, et al. Comparison of resting beta-methyl-iodophenyl pentadecanoic acid (BMIPP) and thallium-201 tomography using quantitative polar maps in patients with unstable angina. *Japan Circ J* 1997; 61:133-8.
  49. Yamabe H, Fujiwara S, Rin K, et al. Resting 123I-BMIPP scintigraphy for detection of organic coronary stenosis and therapeutic outcome in patients with chest pain. *Ann Nucl Med* 2000; 14:187-92.
  50. Kataoka K, Nohara R, Hosokawa R, et al. Myocardial lipid metabolism in compensated and advanced stages of heart failure: evaluation by canine pacing model with BMIPP. *J Nucl Med* 2001; 42:124-9.
  51. Inubushi M, Tadamura E, Kudoh T, et al. Simultaneous assessment of myocardial free fatty acid utilization and left ventricular function using 123I-BMIPP-gated SPECT. *J Nucl Med* 1999; 40:1840-7.
  52. Nanasato M, Ando A, Isobe S, et al. Evaluation of left ventricular function using electrocardiographically gated myocardial SPECT with (123)I-labeled fatty acid analog. *J Nucl Med* 2001; 42:1747-56.
  53. Yoshinaga K, Tahara M, Torii H, Kihara K. Predicting the effects on patients with dilated cardiomyopathy of beta-blocker therapy, by using iodine-123 15-(p-iodophenyl)-3-R,S-methylpentadecanoic acid (BMIPP) myocardial scintigraphy. *Ann Nucl Med* 1998; 12:341-7.
  54. Kurata C, Tawarahara K, Taguchi T, et al. Myocardial emission computed tomography with iodine-123-labeled beta-methyl-branched fatty acid in patients with hypertrophic cardiomyopathy. *J Nucl Med* 1992; 33:6-13.
  55. Ohtsuki K, Sugihara H, Kuribayashi T, Nakagawa M. Impairment of BMIPP accumulation at junction of ventricular septum and left and right ventricular free walls in hypertrophic cardiomyopathy. *J Nucl Med* 1999; 40:2007-13.
  56. Tadamura E, Kudoh T, Hattori N, et al. Impairment of BMIPP uptake precedes abnormalities in oxygen and glucose metabolism in hypertrophic cardiomyopathy. *J Nucl Med* 1998; 39:390-6.