

Use of a large Rusch hydrostatic catheter balloon to control postpartum haemorrhage resulting from a low placental implantation

Lau M S K, Tee J C S

ABSTRACT

We describe the successful use of a balloon catheter in primary postpartum haemorrhage secondary to placenta praevia. A 29-year-old woman was admitted for cervical priming at 37 weeks. Antenatal screening ultrasonography showed a normally-sited placenta. During the surgical induction of labour, bleeding per vaginum was noted, and a mass was felt at the cervical os. Emergency caesarean section was performed, and a placenta praevia was confirmed. Upon reversal of general anaesthesia, vaginal bleeding was noted despite a well-contracted uterus. The estimated blood loss was 1,200 ml. A hydrostatic catheter was inserted vaginally into the uterine cavity. After 17 hours, it was removed with no vaginal bleeding. The insertion for the balloon catheter was easy and simple, requiring minimal analgesia, and it was without significant complication. As obstetricians become more confident in this technique, surgical intervention may be avoided. This may subsequently lead to a reduction in maternal morbidity and mortality.

Keywords: low placental implantation, placental praevia, postpartum haemorrhage, pregnancy complication, Rusch hydrostatic catheter

Singapore Med J 2009;50(9):e321-e323

INTRODUCTION

Primary postpartum haemorrhage (PPH) is defined as blood loss > 500 ml within 24 hours after delivery. Massive PPH (> 1,000 ml) remains one of the most important causes of maternal mortality and accounts for 11% of all maternal deaths during the last triennium confidential enquiries into maternal deaths in the United Kingdom.⁽¹⁾ Locally, 3% of parturients in our hospital experienced massive PPH requiring massive allogeneic blood transfusion during the period, 2004–2008. The management of PPH depends on the aetiology of the

PPH. Common causes include the four Ts: tone (uterine atony), trauma (cervical or vaginal laceration), tissue (retained placental tissues) and thrombin (coagulopathy). The most common cause is uterine atony, and therefore the initial management is to ensure adequate resuscitation and optimal uterine contraction with the use of oxytocics or prostaglandin. In the event of ongoing bleeding refractory to all measures, hysterectomy is done as a life-saving measure. In order to preserve the uterus, and therefore fertility, other modalities on the management of PPH have been advocated.

Uterine packing is discouraged due to concerns about concealed bleeding.⁽²⁾ Balloon tamponade, without the former concern, has been used in recent years. Bilateral ligation of the uterine arteries or internal iliac arteries is technically challenging and has a failure rate of greater than 50% in some series.^(3–5) On the other hand, Hebisch and Huch described uterine arteries ligation via the vaginal approach, which was successful in 12 out of 13 cases.⁽⁶⁾ It has been claimed to be easily learnt and can be performed immediately in any delivery room, without general anaesthesia or operating theatre facilities. Christopher B-Lynch described the B-Lynch suture in 1997.⁽⁷⁾ It provides compression to the uterus and has been used with a good success rate in treating PPH secondary to uterine atony. Selective arterial embolisation has been reported to have a high success rate (up to 97%).⁽⁸⁾ Nonetheless, there is limited data on the implications for subsequent fertility. Moreover, it is associated with complications, such as fever, haematoma, vascular perforation, uterine necrosis, sepsis, improper catheter position and non-target embolisation of other pelvic structures, in 6%–7% of cases.^(8,9) We report a case of primary PPH after a lower segment Caesarean section secondary to an undiagnosed placenta praevia, and it was successfully managed with a balloon tamponade.

CASE REPORT

A 29-year-old multiparous woman was referred to our institution at 31 weeks. Her two previous pregnancies were

Department of
Obstetrics and
Gynaecology,
KK Women's and
Children's Hospital,
100 Bukit Timah
Road,
Singapore 229899

Lau MSK, MBBS,
MMed, MRCOG
Registrar

Tee JCS, MBBS,
MMed, FAMS
Associate Professor
and Senior
Consultant

Correspondence to:
Dr Matthew Lau
Tel: (65) 6394 1062
Fax: (65) 6298 6343
Email: mattlau@
hotmail.com

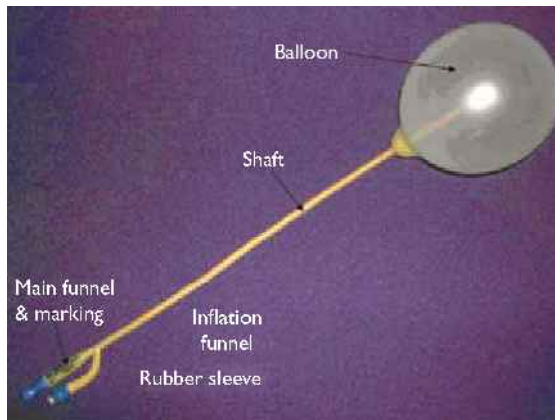


Fig. 1 Photograph shows a Rusch hydrostatic catheter (courtesy of Medquest).

uncomplicated, full-term, normal vaginal deliveries. Prior to the referral, her antenatal care at a private clinic was uneventful, with an ultrasonography at 24 weeks showing a normally-sited placenta. She progressed uneventfully to term. In particular, there was no history of antepartum haemorrhage. She was admitted for cervical priming at 37 weeks' gestation. A 3-mg prostaglandin tablet, PROSTIN E2 (Pfizer, Sanico NV, Turnhout, Belgium), was inserted per vaginam by a midwife after a vaginal examination revealed a cervical os dilatation of 2.5 cm. On the next day, the registrar of the ward examined the patient and assessed the cervical os to be 3 cm dilated. The decision for surgical induction by artificial rupture of the membrane was made to facilitate the labour process. On arrival at the labour ward, continuous cardiotocogram, as per institutional policy, was applied, and the trace was reactive, reflecting a satisfactory foetal condition. During the vaginal examination, fresh vaginal bleeding was noted, and a boggy mass was felt on the cervix. Cervical dilatation was 3 cm.

An emergency caesarean section under general anaesthesia was performed immediately, in view of the active brisk vaginal bleeding and clinical diagnosis of placenta praevia. The diagnosis was confirmed intraoperatively. The placenta was delivered with controlled cord traction. The placental bed over the posterior lower uterine segment bled briskly, requiring multiple haemostatic sutures. Haemostasis was achieved after an estimated blood loss of 700 ml, and a routine two-layer closure of the uterine incision ensued. A high-dose oxytocin, Syntocinon (Novartis Pharma AG, Basel, Switzerland), infusion was given to ensure uterine contractility and prevent uterine atony. At the end of the operation, the patient's vagina was swabbed for clots and checked for bleeding per vaginam. However, immediately after reversal of the general anaesthesia, the theatre staff

noted fresh bleeding per vaginam. On examination, the uterus was well contracted. However, the bleeding was both brisk and persistent. The impression was that the bleeding came from the placental bed at the lower uterine segment. The obstetrician consultant was informed, and a decision was made for a Rusch catheter insertion.

A presterilised Rusch hydrostatic catheter (Teleflex Medical Sdn Bhd, Kamunting, Malaysia) (Fig. 1) was inserted per vaginam, into the uterine cavity with the patient in a lithotomy position. Sponge forceps were placed on the anterior and posterior cervical lips, and the deflated catheter was passed into the uterine cavity. The balloon was then inflated with 750 ml of warm saline. The patient was monitored in the operating theatre for 30 minutes. She remained haemodynamically stable, and there was no evidence of ongoing haemorrhage. The total estimated blood loss was 1,200 ml. A total of 1,560 ml of plateletcrit and 500 ml of fresh frozen plasma were given. From the operating theatre, the patient was sent to the intensive care unit (ICU) where her abdominal girth, fundal height and vital signs were monitored. At three hours postoperation, the bedside ultrasonography showed no evidence of free fluid. After 17 hours, the hydrostatic catheter was deflated and removed uneventfully. The patient remained in the ICU for observation over the next two hours, prior to being discharged to a high dependency ward. The remainder of her postoperative recovery was uneventful, and the patient was discharged three days later.

DISCUSSION

The initial management of PPH is with the use of uterotonic drugs and uterine massage, as the most common cause of PPH is uterine atony. In most instances of placenta praevia, bleeding from a low-lying placental bed could persist despite a well-contracted uterus, due to the poor contractility of the lower uterine segment. Therefore, a balloon tamponade is a reasonable alternative to surgical intervention. The tamponade creates an intrauterine pressure that is greater than the systemic arterial pressure, using the balloon. The blood flow into the uterus should cease once the pressure in the balloon is greater than the systemic arterial pressure. Bakri et al described successful haemostasis in five cases of postpartum bleeding caused by low-lying placenta/placenta praevia, by using a 500-ml fluid-filled tamponade balloon.⁽¹⁰⁾ Condous et al demonstrated an 87.5% success rate in the use of balloon tamponades, using the Sengtaken-Blakemore oesophageal catheter, in 16 cases of PPH.⁽¹¹⁾ We used a Rusch catheter, which is significantly cheaper than the Sengtaken-Blakemore tube.

Uterine artery embolisation may have a high success rate in achieving haemostasis. However, the time between notification of the interventional radiology department and the beginning of the actual embolisation is approximately 45–60 minutes, while the interval between diagnosis and definitive haemostasis was reported to be 60–90 minutes in most institutions.⁽¹²⁾ This is not practical in most cases as it would have subjected the patients to massive blood loss and high morbidity, including the risk of developing disseminated vascular coagulopathy. Therefore, the role of uterine artery embolisation when PPH is not anticipated is yet to be justified.

Surgical intervention with internal iliac artery ligation is technically challenging, as the operating field is compromised by the bleeding. The success rate is about 42%.⁽¹³⁾ The low success rate is a result of the collateral blood supply of the uterus. Internal iliac artery ligation is also associated with high surgical risk. The dorsally-located common iliac vein is prone to injury by instrument, especially if the clamp is introduced laterally to medially. Other possible complications include central pelvic ischaemia, with resulting breakdown of the perineal skin, postischaemic lower motor neuron damage, and ureteric damage. If hysterectomy is performed, the consequence of infertility is often undesirable, and the psychological trauma of losing the uterus incomprehensible.

Balloon tamponade in this case stopped the bleeding and reduced maternal morbidity. Fertility, although not the main issue in this case, could also be preserved. The insertion for balloon tamponade is easy, simple and can be done with minimal analgesia. Its removal is painless and easy as well. The procedure was associated with no significant complications. Therefore, we believe that as obstetricians become more confident in this technique, there will be less surgical intervention. This may

subsequently lead to a reduction in maternal morbidity and mortality.

REFERENCES

1. Lewis G, ed. The Confidential Enquiry into Maternal and Child Health (CEMACH). Saving Mothers' Lives: reviewing maternal deaths to make motherhood safer – 2003-2005 report. The Seventh Report on Confidential Enquiries into Maternal Deaths in the United Kingdom. London: CEMACH, 2007.
2. Wittich AC, Salminen ER, Hardin EL, Desantis RA. Uterine packing in the combined management of obstetrical hemorrhage. *Mil Med* 1996; 161:180-2.
3. Clark SL, Phelan JP, Yeh SY, Bruce SR, Paul RH. Hypogastric artery ligation for obstetric hemorrhage. *Obstet Gynecol* 1985; 66:353-6.
4. Chattopadhyay SK, Deb Roy B, Edrees YB. Surgical control of obstetric hemorrhage: hypogastric artery ligation or hysterectomy? *Int J Gynaecol Obstet* 1990; 32:345-51.
5. Evans S, McShane P. The efficacy of internal iliac artery ligation in obstetric hemorrhage. *Surg Gynecol Obstet* 1985; 160:250-3.
6. Hebisch G, Huch A. Vaginal uterine artery ligation avoids high blood loss and puerperal hysterectomy in postpartum hemorrhage. *Obstet Gynecol* 2002; 100:574-8.
7. B-Lynch C, Coker A, Lawal AH, Abu J, Cowen MJ. The B-Lynch surgical technique for the control of massive postpartum haemorrhage: an alternative to hysterectomy? Five cases reported. *Br J Obstet Gynaecol* 1997; 104:372-5.
8. Vedantham S, Goodwin SC, McLucas B, Mohr G. Uterine artery embolization: an underused method of controlling pelvic hemorrhage. *Am J Obstet Gynecol* 1997; 176:938-48.
9. Greenwood LH, Glickman MG, Schwartz PE, Morse SS, Denny DF. Obstetric and nonmalignant gynecologic bleeding: treatment with angiographic embolization. *Radiology* 1987; 164:155-9.
10. Bakri YN, Amri A, Abdul Jabbar F. Tamponade-balloon for obstetrical bleeding. *Int J Gynaecol Obstet* 2001; 74:139-42.
11. Condous GS, Arulkumaran S, Symonds I, et al. The "tamponade test" in the management of massive postpartum hemorrhage. *Obstet Gynecol* 2003; 101:767-72.
12. Hansch E, Chitkara U, McAlpine J, et al. Pelvic arterial embolization for control of obstetric hemorrhage: a five-year experience. *Am J Obstet Gynecol* 1999; 180:1454-60.
13. Clark SL, Phelan JP, Yeh SY, Bruce SR, Paul RH. Hypogastric artery ligation for obstetric hemorrhage. *Obstet Gynecol* 1985; 66:353-6.