

Shoulder girdle lipomatosis

Sharma R, Priyadarshi R N, Seith A

ABSTRACT

Shoulder girdle lipomatosis is an extremely rare condition, with unique clinical and imaging features. We report shoulder girdle lipomatosis in a 46-year-old man who presented with a gradual soft tissue enlargement in his left shoulder. We discuss the magnetic resonance imaging features of this disease and the approach to accurate diagnosis. A review of the clinical and radiological features of shoulder girdle lipomatosis is also presented.

Keywords: fatty tumours, lipectomy, lipomatosis, shoulder girdle lipomatosis, shoulder mass, magnetic resonance imaging

Singapore Med J 2009;50(9):e315-e317

INTRODUCTION

Shoulder girdle lipomatosis is an extremely rare subtype of lipomatosis, and to the best of our knowledge, only seven cases have been previously described.^(1,2) This condition has different clinical, pathological and radiological findings. It is characterised by a unilateral gradual enlargement, and deformity of the shoulder and proximal part of the arm, due to the diffuse accumulation of fat within or between the involved muscles. Associated shoulder girdle muscle weakness, and motor and sensory neuropathy are not uncommon. The surgical removal of lipomatous tissue either by lipectomy or liposuction is unsatisfactory, and it is frequently followed by a recurrence.⁽¹⁾

CASE REPORT

A 46-year-old man presented with complaints of anxiety, insomnia and discomfort on the left side of his chest. He also noticed an increased girth of his left shoulder over a span of 15 years. There was no history of chest pain, orthopnoea, dyspnoea, cough or weakness of the limbs. The limb swelling neither increased in a dependent position nor was relieved with the arm in an upright position. He was a non-smoker and a non-alcoholic. The patient's past medication history and family history were unremarkable. The physical examination showed normal physical findings, except for an asymmetric diffuse enlargement of the left shoulder and arm. The neck and supraclavicular soft tissue were normal. The overlying skin was coarse with some skin tags over it.

There was no pitting oedema over the limbs. No soft tissue abnormalities were noted in the forearm and hand. Laryngoscopic examination was normal.

His electrocardiogram was normal. Routine biochemical investigations, including haematology, liver function tests, kidney function tests and hormonal parameters, were normal. His lipid profile did not show hyperlipidaemia. The tests for microfilaria were also negative. His absolute eosinophil count was 200/mm³. Magnetic resonance (MR) imaging showed homogeneous hyperintense signals on both T1- and T2-weighted images, identical to normal subcutaneous fat. The fat-suppressed images showed a suppression of signals consistent with that of lipomatous tissue. There were no oedematous areas or soft tissue components. The fat was diffusely present within and between the muscles. Ipsilateral chest wall deformity was present (Fig. 1). The MR imaging findings were typical for shoulder girdle lipomatosis, and no other differential was considered, and therefore, no subsequent biopsy was suggested. The treatment options and prognosis of the disease were presented to the patient. The patient refused surgical management, and follow-up MR imaging was recommended at one year.

DISCUSSION

Shoulder girdle lipomatosis was first described by Enzi et al in 1992, in a report of six patients.⁽¹⁾ McEachern et al subsequently reported this condition in a 45-year-old female patient with MR imaging features and histopathology.⁽²⁾ All prior reports of this disorder have been in women between the ages of 38 and 75 years.^(1,2) To the best of our knowledge, this is the first case report of this unique condition reported in a male patient. Several types of lipomatosis have been described in the literature, and they are characterised by diffuse, symmetrical overgrowth of mature adipose tissue. Asymmetrical lipomatosis is a very rare condition.⁽³⁾ Multiple symmetric lipomatosis, sometimes referred to as Madelung's disease, is a rare form of lipomatosis that is characterised by symmetrical deposits of adipose tissue in the head, neck and trunk. It has a strong association with alcohol consumption.^(4,5) Other relatively common types of lipomatosis are named according to the anatomical site of occurrence. Pelvic lipomatosis is characterised as diffuse fatty tissue deposition in the pelvic perivesicle area.⁽⁶⁾ Renal sinus and perirenal sinus lipomatosis involve fat deposition

Department of
Medicine,
All India Institute of
Medical Sciences,
Ansari Nagar,
New Delhi 110029,
India

Sharma R, MD
Senior Resident

Department of
Radiodiagnosis

Priyadarshi RN, MD
Senior Resident

Ashu S, MD
Associate Professor

Correspondence to:
Dr Ashu Seith
Tel: (91) 11 2659 4868
Fax: (91) 11 2686 2663
Email: ashubhallal@
yahoo.com

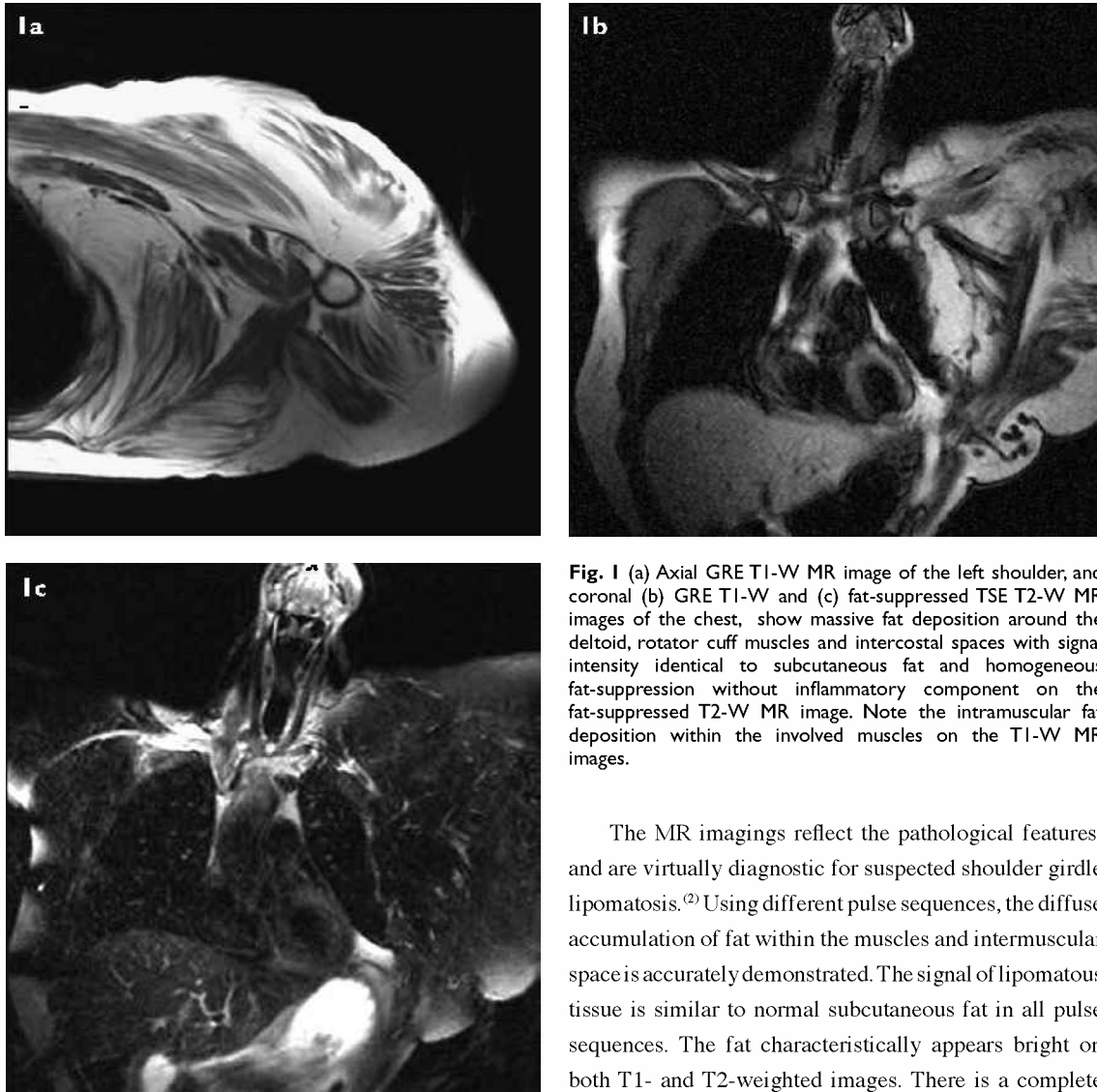


Fig. 1 (a) Axial GRE T1-W MR image of the left shoulder, and coronal (b) GRE T1-W and (c) fat-suppressed TSE T2-W MR images of the chest, show massive fat deposition around the deltoid, rotator cuff muscles and intercostal spaces with signal intensity identical to subcutaneous fat and homogeneous fat-suppression without inflammatory component on the fat-suppressed T2-W MR image. Note the intramuscular fat deposition within the involved muscles on the T1-W MR images.

in both the renal and perirenal spaces.⁽⁷⁾ Mediastino-abdominal lipomatosis is characterised as mediastinal and abdominal fat accumulation in non-obese patients.⁽⁸⁾

Shoulder girdle lipomatosis, however, is extremely rare. The unilateral and gradual enlargement of the shoulder with time is the primary clinical finding of this condition. Respiratory symptoms are commonly present due to either the compression of the upper airway or the infiltration of the laryngeal wall. Three (50%) of six patients reported by Enzi et al had respiratory problems. Neuromyopathy commonly occurs due to the fatty degeneration of the nerves, which leads to weakness of the involved muscle.^(1,2,9) Our patient did not have any respiratory symptom and nerve involvement. The aetiology of shoulder girdle lipomatosis is unclear. A pathogenesis postulated by Enzi et al describes that it is the result of a hyperplastic process, with *in vitro* studies demonstrating a defect in adrenergic-stimulated lipolysis of the lipomatosis tissue.⁽⁴⁾

The MR imagings reflect the pathological features, and are virtually diagnostic for suspected shoulder girdle lipomatosis.⁽²⁾ Using different pulse sequences, the diffuse accumulation of fat within the muscles and intermuscular space is accurately demonstrated. The signal of lipomatous tissue is similar to normal subcutaneous fat in all pulse sequences. The fat characteristically appears bright on both T1- and T2-weighted images. There is a complete suppression of signals from fatty tissue on fat-suppressed images without abnormal T2-hyperintense areas. The fatty deposition tends to be diffuse and homogeneous, unlike intramuscular lipoma or differentiated liposarcoma, where the lesion is focal and well-defined.⁽¹⁰⁾ Our observation was similar to previously-described cases, except that ipsilateral chest wall deformity was present. It may be due to the longstanding mass effect of the lipomatous tissue.

Pathologically, there is intramuscular fat infiltration. Mature adipocytes are deposited between the muscle fibres. Evidence of muscular degeneration is present in the majority of patients.^(1,4) The management of lipomatosis is not satisfactory. Surgical removal via either direct excision (lipectomy) or liposuction can give good cosmetic results, although recurrences often occur.^(11,12) Liposuction has been used as the first choice of treatment in selected patients, while combined surgery and liposuction have also been tried with moderate success.^(13,14)

REFERENCES

1. Enzi G, Carraro R, Alfieri P, et al. Shoulder girdle lipomatosis. *Ann Intern Med* 1992; 117:749-50.
2. McEachern A, Janzen DL, O'Connell JX. Shoulder girdle lipomatosis. *Skeletal Radiol* 1995; 24:471-3.
3. Enzi G, Digito M, Baldo Enzi G, Perin B, Fiore D. Asymmetrical lipomatosis: report of two cases. *Postgrad Med J* 1985; 61:797-800.
4. Enzi G, Biondetti PR, Fiore D, Mazzoleni F. Computed tomography of deep fat masses in multiple symmetrical lipomatosis. *Radiology* 1982; 144:121-4.
5. Enzi G, Busetto L, Ceschin E, et al. Multiple symmetric lipomatosis: clinical aspects and outcome in a long-term longitudinal study. *Int J Obes Relat Metab Disord* 2002; 26:253-61.
6. Fogg LB, Smyth JW. Pelvic lipomatosis: a condition simulating pelvic neoplasm. *Radiology* 1968; 90:558-64.
7. Faegenburg D, Bosniak MA, Evans JA. Renal sinus lipomatosis: its demonstration by nephrotomography. *Radiology* 1964; 83:987-98.
8. Enzi G, Digito M, Marin R, et al. Mediastino-abdominal lipomatosis: deep accumulation of fat mimicking a respiratory disease and ascites. Clinical aspects and metabolic studies in vitro. *Q J Med* 1984; 53:453-63.
9. Chalk CH, Mills KR, Jacobs JM, Donaghy M. Familial multiple symmetric lipomatosis with peripheral neuropathy. *Neurology* 1990; 40:1246-50.
10. Einarsdottir H, Soderlund V, Larson O, Jenner G, Bauer HCF. MR imaging of lipoma and liposarcoma. *Acta Radiol* 1999; 40:64-8.
11. Brackenbury ET, Morgan WE. Surgical management of Launois-Bensaude syndrome. *Thorax* 1997; 52:834-5.
12. Verhelle NA, Nizet JL, Van den Hof B, Guelinckx P, Heymans O. Liposuction in benign symmetric lipomatosis, sense or senseless? *Aesthetic Plast Surg* 2003; 27:319-21.
13. Carlin MC, Ratz JL. Multiple symmetric lipomatosis: treatment with liposuction. *J Am Acad Dermatol* 1988; 18:359-62.
14. Constantinidis J, Steinhart H, Zenk J, Gassner H, Iro H. Combined surgical lipectomy and liposuction in the treatment of benign symmetrical lipomatosis of the head and neck. *Scand J Plast Reconstr Surg Hand Surg* 2003; 37:90-6.