

# A new feeding tube which is secure and easy to change

Pang A S

## ABSTRACT

Loss of a normal swallowing reflex as in dysphagic stroke is the commonest indication for long-term tube feeding. For this, either the nasogastric tube or the percutaneous endoscopic gastrostomy tube is used, with the former being uncomfortable. The latter tube is neither secure nor easy to change. A new feeding tube invented in Singapore uses a loop and lock configuration to make it comfortable for the patient, impossible to pull out accidentally, and easy to change. This third-generation feeding tube has the potential to be the new global standard.

**Keywords:** aspiration, enteral nutrition, feeding tube, gastrostomy, pneumonia, stroke

*Singapore Med J 2009;50(7):740-742*

## INTRODUCTION

Strokes, dementias and other neurological conditions frequently leave their victims with a weak, absent or abnormal swallowing reflex. For these patients, oral feeding carries the risk of aspiration pneumonia and tube feeding may be necessary, sometimes for the long term. With its fast-ageing population, Singapore will see more of these cases. The nasogastric (NG) tube which passes through the nose is uncomfortable for most patients.<sup>(1)</sup> It may be tolerated for a week or two. Longer than this, the patient will pull it out at every opportunity. Some patients prefer to die rather than have the NG tube re-inserted, an indication of the great discomfort the NG tube can cause. Hand restrainers can be used to keep the NG tube in place but the resultant immobility creates additional problems, e.g. depression, osteoporosis, contractures and pressure sores.

Most medical and nursing societies recommend the gastrostomy (G) tube for long-term tube feeding.<sup>(2)</sup> The G tube passes directly to the stomach through the anterior abdominal wall. A mature gastrostoma is not painful. Until the stoma matures, about 2–4 weeks after creation, the patient might experience mild discomfort which can be controlled with simple analgesics. The G tube has been in existence for more than a century. There are many insertion methods, broadly classified as surgical, laparoscopic, radiological and endoscopic. The endoscopic method

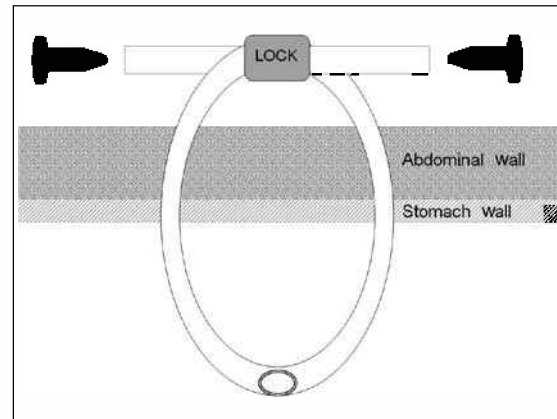


Fig. 1 Schematic diagram shows the anatomy of a third-generation feeding tube.

is the most popular today because it is simple, safe and requires only local anaesthesia.<sup>(3)</sup> A G tube inserted by the endoscopic method is commonly called a percutaneous endoscopic gastrostomy (PEG).

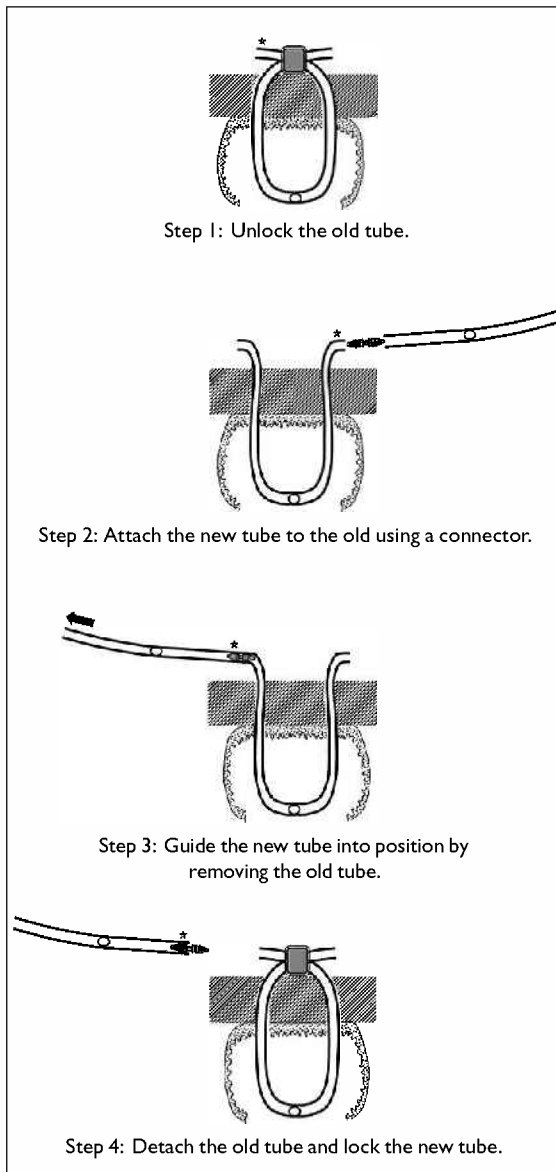
The PEG has been in routine use, worldwide, for about 30 years. Clinical experience has found the pull-method of PEG to be safe, producing a stoma that fits the tube snugly, with a low risk of leakage. This has been validated by the use of dual PEG to treat gastric volvulus.<sup>(4)</sup> It can also be deployed in a contaminated environment, as demonstrated by the use of percutaneous endoscopic colostomy to treat sigmoid volvulus.<sup>(5)</sup> However, the PEG has its own set of disadvantages. The tube can be pulled out accidentally, by the patient or caregiver, during bathing, dressing, turning, moving or exercising. A slipped PEG within two weeks of insertion can give rise to peritonitis, and hence, it is always a medical emergency which requires urgent attention. After the stoma has matured, a slipped PEG must also be attended to urgently because the stoma can close within several hours. Another major drawback is that the PEG cannot be changed easily. The change is sometimes quite difficult, requiring check endoscopy or radiography before the new PEG can be safely used. Hence, the change is usually done by a specialist in a hospital setting.

Although more comfortable than the NG tube, the PEG is the significantly riskier and costlier option. There is a tendency to compensate by changing the PEG every six months or longer. This is unhygienic, because the tube will become quite dirty after a month, especially its

LP Surgery,  
#02-05 Mount  
Alvernia Medical  
Centre A,  
820 Thomson Road,  
Singapore 574623

Pang AS, MBBS,  
FRCSE, FAMS  
General Surgeon

**Correspondence to:**  
Dr Pang Ah-San  
Tel: (65) 6356 3260  
Fax: (65) 6356 3261  
Email: pangahsan@gmail.com



**Fig. 2** Diagram shows the procedure for a percutaneous change of the 3G tube is simple and safe.

luminal surface.<sup>(6)</sup> The use of an opaque tube camouflages the problem, making the unhygienic situation more tolerable, but this approach is akin to sweeping dirt under the carpet.

### TECHNIQUE

The ideal feeding tube should have the following features:

- (1) It must be a gastrostomy tube which bypasses the nose.
- (2) It must be capable of insertion under local anaesthesia using the pull-method of PEG.
- (3) It must remain in position when tugged, accidentally or deliberately.
- (4) It must be simple, safe and easy to change.

A third-generation (3G) tube manufactured by

SGN Pte Ltd, Singapore, and marketed under the brand LOOPPEG™ is now available. The LOOPPEG™ 3G tube is a 15 Fr soft silicone gastrostomy tube with all the features of an ideal feeding tube. It is placed in a loop configuration with the limbs locked together (Fig. 1). Consequently, it cannot be pulled out even when tugged with a great force. There is a spigot at each end, and a pair of exit openings at the mid-segment which lies in the stomach. Any end may be used for feeding liquid food, reserving the other for medicines. It is inserted under local anaesthesia using the same pull-method of PEG. Uniquely, change of tube can be done safely at home. Four simple steps are required to change the tube (Fig. 2). No check endoscopy or radiograph is required.

### DISCUSSION

The LOOPPEG™ 3G tube has other advantages over the PEG (Table I). The size of the NG tube for a given patient is determined by the size of his nostril. The larger the NG tube, the easier for the caregiver to use, but the greater the discomfort for the patient. In Singapore, the size most commonly selected, the preferred compromise between function and discomfort, is 14 Fr. The LOOPPEG™ 3G tube at 15 Fr is more than adequate for use with all commercial formula feeds.

For the PEG, the available sizes are 20 Fr and 24 Fr. The 15 Fr of the LOOPPEG™ 3G tube is an advantage since the stoma required is smaller and more comfortable. However, two stomas are employed. The total surface area of the two stomas is 25% more than the single stoma of the 24 Fr PEG. If we assume that the risk is directly proportional to surface area, then the risk of LOOPPEG™ 3G tube is 25% more than 24 Fr PEG. This theoretical increase is offset by a real reduction in risk (no external bolster to irritate the stoma, no buried bumper syndrome, improved hygiene with frequent change of tube, and zero incidence of slipped tube). The actual complication rate of the LOOPPEG™ 3G tube may be lower than the PEG.

The rate of local complications for the PEG is well-documented.<sup>(7,8)</sup> The rate, at best, is low, and at worst, acceptable. A theoretical increase of 25% of a low rate may be a fair exchange for the tangible benefits of the LOOPPEG™ 3G tube, listed in Table I. As the LOOPPEG™ 3G tube has many advantages over the PEG, it should be recommended to new patients who require long-term tube feeding. A patient with an existing NG tube or PEG can be easily converted to the LOOPPEG™ 3G tube but this should be done after a careful benefit/cost analysis.

### DISCLOSURE

The author is the inventor of the tube. He is the director

**Table I. Percutaneous endoscopic gastrostomy vs. LOOPPEG™ 3G tube.**

Criteria	PEG	LOOPPEG™ 3G
1. Does it bypass the nose?	Yes	Yes
2. Is it inserted under LA?	Yes	Yes
3. Will it stay in position when pulled?	No	Yes
4. Can tube be changed by any caregiver?	No	Yes
5. Can tube be changed anytime?	No	Yes
6. Can tube be changed anywhere?	No	Yes
7. Is changing the tube painless and bloodless?	No	Yes
8. Is the external profile low?	No	Yes
9. Is the internal profile low?	No	Yes
10. Is the stoma free from irritation by bolster?	No	Yes
11. Is it free of buried bumper syndrome?	No	Yes
12. Are there separate channels for food and medicines?	No	Yes
13. Stress on the caregiver	High	Low
14. Tube design	Complex	Simple
15. Method to check tip position	Radiograph or endoscopy (expensive)	Visual check
16. Maintenance cost	High (emergency hospitalisation for slipped tube)	Low (zero incidence of slipped tube)

of SGN Pte Ltd, which was awarded a grant by Spring Singapore to commercialise it. The grant was awarded following clinical validation of the prototype on patients.

## REFERENCES

- Pearce CB, Duncan HD. Enteral feeding. Nasogastric, nasojejunal, percutaneous endoscopic gastrostomy, or jejunostomy: its indications and limitations. *Postgrad Med J* 2002; 78:198-204.
- NHS Scotland. Gastrostomy tube insertion and aftercare: (for adults being cared for in hospital or in the community). Best Practice Statement. Edinburgh: NHS Quality Improvement Scotland; 2008 May.
- Miller RE, Kummer BA, Tiszenkel HI, Kotler DP. Percutaneous endoscopic gastrostomy. Procedure of choice. *Ann Surg* 1986; 204:543-5.
- Eckhauser ML, Ferron JP. The use of dual percutaneous endoscopic gastrostomy (DPEG) in the management of chronic intermittent gastric volvulus. *Gastrointest Endosc* 1985; 31:340-2.
- Daniels IR, Lamparelli MJ, Chave H, Simson JN. Recurrent sigmoid volvulus treated by percutaneous endoscopic colostomy. *Br J Surg* 2000; 87:1419.
- Dautle MP, Ulrich RL, Hughes TA. Typing and subtyping of 83 clinical isolates purified from surgically implanted silicone feeding tubes by random amplified polymorphic DNA amplification. *J Clin Microbiol* 2002; 40:414-21.
- Schurink CA, Tuynman H, Scholten P, et al. Percutaneous endoscopic gastrostomy: complications and suggestions to avoid them. *Eur J Gastroenterol Hepatol* 2001; 13:819-23.
- Finocchiaro C, Galletti R, Rovera G, et al. Percutaneous endoscopic gastrostomy: a long-term follow-up. *Nutrition* 1997; 13:520-3.