

INTRACRANIAL NAIL INSERTION AS A MANOEUVRE OF WITCHCRAFT

Dear Sir,

Cranio-cerebral penetrating wounds caused by nails are rare and reported as curious experiences.⁽¹⁻⁵⁾ A 45-year-old female patient presented with a metal nail *in situ* in the middle of her head, very close to the right side of the midline. The patient had been unconscious since the time of injury. There was no history of vomiting or seizures. Neurologically, the eye opening and verbal response were nil, but she was localised to the pain and moved all four limbs equally. The pupils were bilaterally symmetrical and reactive to light. General and systemic examinations were unremarkable. The relatives revealed that she had been suffering from a headache (more on the right side) for the last ten years, with off and on exacerbation. They took the patient to a *Tantrik*, who hammered the nail into her head to get rid of the bad omen. Anteroposterior and lateral radiographs of the skull showed a foreign object inside the skull, very near to the midline (Fig. 1). As there were no facilities to perform computed tomography (CT) in the peripheral hospital, the nail was removed under local anaesthesia, based on the radiographical findings (Fig. 1). After the removal of the nail, she was managed conservatively and made a gradual recovery in her sensorium. The patient was doing well at follow-up.

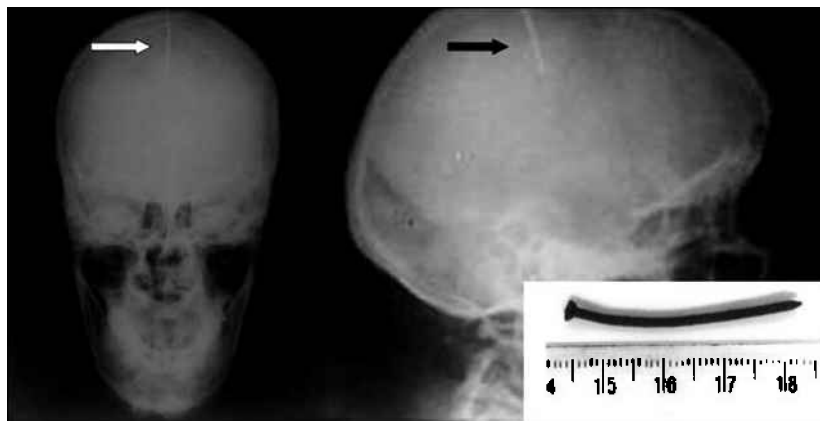


Fig. 1 Skull radiographs taken in the anteroposterior (left) and lateral (right) projections show the nail (arrow) very close to the right side of the midline. Inset photograph shows the removed nail.

Penetrating nail injuries of the skull can be accidental,⁽²⁻⁴⁾ suicidal^(1,6) or due to unexplained supernatural beliefs,⁽⁷⁾ as in the present case. The nail acts as a low velocity missile and usually results in non-fatal injuries.⁽²⁾ Patients are usually diagnosed at the time of injury, and work-up of these patients include CT and if necessary, angiography.⁽²⁾ The aim of management of these patients is like that of any other patient involved in a high velocity firearm injury, i.e. the removal of devitalised tissues, evacuation of haematomas, and removal of bone fragments and penetrating bodies.⁽⁵⁾ Blind extraction, craniectomy, and craniotomy with removal of the nail under direct vision have been described in the literature.⁽³⁾ Although the removal of a nail by an untrained first-aider can be surprisingly simple, with a good functional outcome,⁽⁶⁾ and though the blind removal of the nail in the present case resulted in patient survival, and could be attributed to luck, we would strongly recommend that for such cases, thorough preoperative investigations should be followed by craniotomy, and removal of the nail should be done under direct vision in an operating theatre.

Yours sincerely,

Vinay V Shahpurkar

Amit Agrawal

Avanish Deshmukh

Kaustubh Sarda

Ankur Grover

Division of Neurosurgery

Datta Meghe Institute of Medical Sciences

Sawangi (Meghe)

Wardha 442004

Maharashtra

India

Email: dramitagrawal@gmail.com

REFERENCES

1. Bock H, Neu M, Betz P, Seidl S. Unusual craniocerebral injury caused by a pneumatic nail gun. *Int J Legal Med* 2002; 116:279-81.
2. Lee AD, Oh YS. Unusual delayed presentation of a nail gun injury through the skull base. *Laryngoscope* 2007; 117:977-80.
3. Spennato P, Bocchetti A, Mirone G, et al. Double concentric craniotomy for a craniocerebral penetrating nail. Case report and technical note. *Surg Neurol* 2005; 64:368-71.
4. Richards TJ. The man with a 3-inch nail in his head. *Med Econ* 2000; 77:137, 140, 143.
5. Tancioni F, Gaetani P, Pugliese R, Rodriguez y Baena R. Intracranial nail. A case report. *J Neurosurg Sci* 1994; 38:239-43.
6. Spiers AS. Attempted suicide or hitting the nail on the head. Case report. *J Fla Med Assoc* 1994; 81:822-3.
7. Reichart PA, Creutz U, Scheifele C. Unusual foreign metallic object (nail) in the dentition of a skull from the anthropological collection of Rudolf Virchow (Berlin). *J Forensic Odontostomatol* 2006; 24:18-21.