

Idiopathic thrombocytopenic purpura with isolated tuberculous splenic abscess

Sinha N, Gupta N, Jhamb R

ABSTRACT

We present a 14-year-old boy, a known case of idiopathic thrombocytopenic purpura (ITP) for five years, and was treated with intermittent oral steroids. He presented with left upper abdominal pain of three months' duration. The pain was dull, aching and non-radiating. There were no other associated features. Before this presentation, he was receiving oral steroids for a month. The patient had been hospitalised in the past for ITP-related bleeding. The patient was managed with anti-tuberculous therapy alone, and after nine months, his splenic abscess regressed significantly in size. Tuberculous splenic abscesses are rare, and in particular, isolated tuberculous splenic abscesses are extremely rare with only three cases reported to date. This may be the first case report of tuberculous splenic abscess in ITP. It is noteworthy that this abscess was minimally symptomatic, with no fever or constitutional symptoms.

Keywords: idiopathic thrombocytopenic purpura, tuberculosis, tuberculous splenic abscess

Singapore Med J 2009; 50(1): e41-e43

INTRODUCTION

Splenic abscesses are rare in clinical practice, with a prevalence of 0.2%–0.7% on autopsy studies. Tuberculous splenic abscesses are very rare and are usually seen in immunocompromised patients. These may be part of more disseminated tuberculosis elsewhere in the body. Isolated tuberculous splenic abscess, when no other focus of tuberculosis is present within the body, is extremely rare. We present a case of idiopathic thrombocytopenic purpura (ITP) who developed an isolated tuberculous splenic abscess that responded well to anti-tuberculous therapy. This abscess was minimally symptomatic.

CASE REPORT

A 14-year-old boy was diagnosed to have ITP five years earlier when he presented with gum bleeding

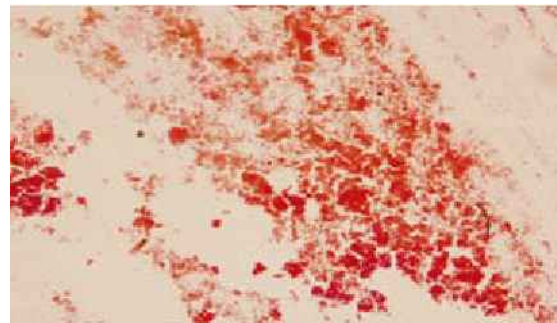


Fig. 1 Photomicrograph shows caseous necrosis in the FNAC of the splenic abscess.

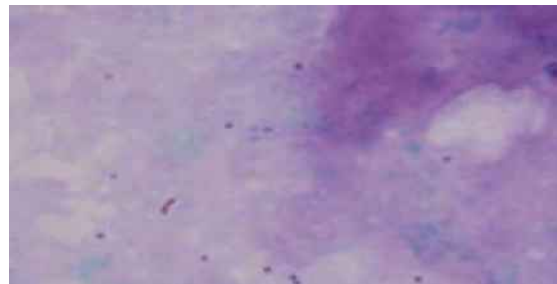


Fig. 2 Photomicrograph shows acid-fast bacilli in the FNAC of the splenic abscess.

and epistaxis. He responded to steroids, which were tapered based on the response. The patient required hospitalisation four times for ITP-related bleeding and required intermittent oral steroids, the last being one month prior to this presentation. This time, he presented with left upper abdominal pain for the past three months. He was on a tapering dose of oral prednisolone for the past one month with no overt bleeding manifestations. The pain was dull-aching, frequent and non-radiating. There were no other associated symptoms. There was no history of infection, tuberculosis, surgical interventions or any other significant illness in the past. He lived in a small family with no family history of tuberculosis. He had adequate immunisation during his childhood. Clinical examination including systemic review was essentially normal.

Investigations revealed haemoglobin of 12.8 g/dL, total leucocyte count of 8,900/mm³ with polymorphs 59%, lymphocytes 37%, monocytes 2% and eosinophils 2%. Platelet count was 150 × 10⁹/L. Erythrocyte sedimentation rate was 5 mm/first hour. Blood glucose,

Department of
Medicine,
Maulana Azad
Medical College,
Delhi 110002,
India

Sinha N, MBBS, MD
Senior Resident

Gupta N, MBBS,
MD
Professor

Jhamb R, MBBS, MD
Assistant Professor

Correspondence to:
Dr Nitin Sinha
Tel: (91) 11 2336 4844,
Fax: (91) 2 323 6437
Email: drnitinsinha26@
yahoo.co.in

kidney function tests and liver function tests were unremarkable. Urine routine and microscopy revealed no abnormality. Chest radiograph and electrocardiogram were normal. Ultrasonography of the abdomen revealed a 2.4 cm × 1.6 cm heterogeneous lesion in the mid-pole of the spleen, suggestive of either a splenic abscess or a splenic infarct. The spleen was normal in size and the rest of the abdomen was normal. Computed tomography (CT) of the abdomen revealed a 4.0 cm × 3.0 cm × 2.5 cm peripherally-enhancing lesion in the mid-pole of the spleen, suggestive of a splenic abscess. CT-guided aspiration of the splenic abscess revealed caseous material (Fig. 1) with acid-fast bacilli (Fig. 2) on Ziehl-Neelsen staining. Mantoux test produced an induration of 8 mm × 8 mm at 72 hours.

A diagnosis of ITP with isolated tuberculous splenic abscess was made. The patient was started on anti-tuberculous therapy consisting of isoniazid, rifampicin, ethambutol, pyrazinamide and pyridoxine in appropriate doses for the initial two months, followed by isoniazid, rifampicin and pyridoxine for the next seven months. The patient improved clinically and the splenic abscess size decreased to 0.5 cm × 0.5 cm. No side effects of anti-tuberculous drugs were encountered during the therapy.

DISCUSSION

Splenic abscesses are rare.⁽¹⁾ Autopsy series suggest a prevalence of 0.2%–0.7%. Splenic abscesses are either microbial or non-microbial in aetiology. The most common organisms causing splenic abscesses are Gram-positive organisms, such as *Streptococcus* (most common), *Staphylococcus* followed by Gram-negative bacilli, such as *Escherichia coli* and *Klebsiella pneumoniae*. Anaerobic organisms, such as *Peptostreptococcus*, *Bacteroides* and *Fusobacterium*, have also been isolated. Rare pathogens include *Burkholderia pseudomallei*, *Actinomycetes* and *Mycobacterium tuberculosis*. Polymicrobial aetiology has also been shown in 36%–50% of cases. Splenic abscess arises *de novo* in the spleen or in sepsis where the focus of infection is located elsewhere, e.g. the heart (infective endocarditis). The host is usually immunocompromised, but can be immunocompetent as well. Splenic abscesses are of two types:⁽¹⁾ (a) Primary splenic abscesses, which are usually solitary with disease being limited to the spleen only. These have a good prognosis. (b) Secondary splenic abscesses, which are seen in the immunodeficient state and in sepsis, and tend to be multiple and have a poorer prognosis.

The symptoms of splenic abscess include fever (95%), abdominal pain (60%), left upper abdominal pain (38%), chills (22%), left-sided chest pain

(17%), vomiting (16%), anorexia (15%), weight loss (11%), left shoulder pain (10%), change in bowel habits (9%) and right upper abdominal pain (6%).⁽²⁾ Examination may reveal abdominal tenderness (59%), splenomegaly (54%), left lower lobe dullness (33%), left basilar rales (21%), hepatomegaly (18%), left elevated hemidiaphragm (18%), abdominal distention (13%), ascites (7%), left pleural friction rub (5%) and costovertebral tenderness (5%). Symptoms and signs of splenic abscesses are rarely adequate to diagnose splenic abscess.

A high index of suspicion is required in high-risk patients with fever and abdominal pain. Investigations may reveal leucocytosis in 70% of cases but may remain normal in the immunocompromised host or in cases of fungal abscesses. Blood cultures are positive in 60% of patients. Chest radiographs may show an elevated left hemidiaphragm (33%) or left pleural effusion (28%). Abdominal ultrasonography is a noninvasive, cheap and easily-repeatable investigation that shows a splenic abscess as a hypoechoic to anechoic lesion with a variable amount of internal echogenicity. This may be mimicked by lymphomatous masses, fresh infarcts and haematomas. CT of the abdomen may help in cases of a dilemma. Its sensitivity approaches 100%. Radioisotope liver-spleen scans have little value in the diagnosis of splenic abscess. Ultrasonography- and CT-guided aspiration help in defining the aetiology.

Percutaneous drainage, splenectomy and medical management are the treatment options available, with the mode of treatment decided upon as warranted in an individual case. Medical management, which comprises broad spectrum antibiotics, is complementary to interventional procedure. There are very few case reports available which suggest that bacterial abscesses can be managed with antibiotics alone. Reports of splenic fungal abscesses in immunosuppressed non-critically ill patients being treated successfully by amphoterecin B alone are available.⁽³⁾ Surgical management is still the mainstay of treatment and completely removes the focus of infection. Recent results with ultrasonography- or CT-guided percutaneous drainage should make this option the first line of therapy with uncomplicated solitary lesions in critically-ill patients or in the paediatric environment, when splenic conservation is desired. There are no prospective, randomised studies to determine whether percutaneous drainage or splenectomy, along with appropriate antimicrobial therapy, is the more effective treatment.⁽⁴⁻⁷⁾

Tuberculous splenic abscesses are rare and are seen in immunocompromised hosts.⁽⁸⁻¹³⁾ Tuberculous splenic abscesses are usually associated with some

other focus of tuberculosis elsewhere in the body. More rare are the few case reports of isolated tuberculous splenic abscess,^(9,10,12) where there is no other discernable or detectable focus of tuberculosis. These present with fever and abdominal pain, with or without splenomegaly. Anti-tuberculous therapy with splenectomy is the treatment of choice.⁽⁸⁾ Our case was known to have ITP on intermittent steroids for five years and was therefore immunodeficient before developing an isolated tuberculous splenic abscess. He presented with abdominal pain but had no fever or any constitutional symptoms, nor any loss of weight. No other focus of tuberculosis was detected on detailed evaluation. All these features make our case a rare one and we are not aware of any other such report in the medical literature to date. It also emphasises that left upper quadrant abdominal pain could be the sole manifestation of tuberculous splenic abscess, especially in a high-risk setting. Accordingly, adequate investigations should be done for rapid detection of this illness which is curable if detected early.

REFERENCES

- Jacob DO. Splenic abscess. Available at: www.emedicine.com/med/topic2791.htm. Accessed September 6, 2006.
- Chun CH, Raff MJ, Contreras L, et al. Splenic abscess. *Medicine (Baltimore)* 1980; 59:50-65.
- Helton WS, Carrico CJ, Zaveruha PA, Schaller R. Diagnosis and treatment of splenic fungal abscesses in the immune-suppressed patient. *Arch Surg* 1986; 121:580-6.
- Scalfani SJ, Goldstein AS, Shaftan GW. Interventional radiology: an alternative to operative drainage of post-traumatic abscesses. *J Trauma* 1984; 24:299-306.
- Thanos L, Dailiana T, Papaioannou G, et al. Percutaneous CT-guided drainage of splenic abscess. *Am J Roentgenol* 2002; 179:629-32.
- Wernecke K, Heckemann R. Treatment of pyogenic splenic abscess by ultrasonically guided fine needle puncture. *Eur J Radiol* 1985; 5:216-7.
- Mohta A, Sharma SK, Sinha SK. Splenic abscess: successful treatment by percutaneous aspiration. *J Indian Assoc Pediatr Surg* 2003; 8:113-5.
- Sharma N, Sharma S. Tuberculous abscess of the abdominal wall and multiple splenic abscesses in an immunocompetent patient. *Indian J Chest Dis Allied Sci* 2004; 46:221-3.
- Chaudhuri, Ghosh G, Ghosh US, Banerjee P. Splenic tuberculosis-a case report. *J Indian Med Assoc* 1998; 96:317.
- Sharma S, Dey AB, Agarwal N, Nagarkar KM, Gujral S. Tuberculosis: a rare cause of splenic abscess. *J Assoc Physicians India* 1999; 47:740-1.
- Neki NS, Batra KS, Sharma RK, et al. Isolated tubercular splenic abscess. *J Assoc Physicians India* 2001; 49:759-60.
- Gotor MA, Mur M, Guerrero L, et al. [Tuberculous splenic abscess in an immunocompetent patient]. *Gastroenterol Hepatol* 1995; 18:15-7. Spanish.
- Anuradha S, Singh NP, Agarwal SK. Splenic abscess – a diversity within. *J Indian Acad Clin Med* 2000; 1:279-81.