

# Stevens-Johnson syndrome and toxic epidermal necrolysis: efficacy of intravenous immunoglobulin and a review of treatment options

Teo L, Tay Y K, Liu T T, Kwok C

## ABSTRACT

**Toxic epidermal necrolysis (TEN) is a rare, severe adverse drug reaction. Steven-Johnson syndrome (SJS) represents the milder end of the spectrum. The exact pathogenesis of TEN and SJS is still unknown and many drugs, including prednisolone, cyclosporin and intravenous immunoglobulin (IVIG), have been used in an attempt to halt the disease process. The use of IVIG in particular is controversial. We share our experience with the use of IVIG in six patients with TEN. We will also review the various proposed mechanisms underlying TEN, the mechanism of action of IVIG in TEN and summarise useful treatment options.**

**Keywords:** adverse drug reaction, corticosteroids, intravenous immunoglobulin, Stevens-Johnson syndrome, toxic epidermal necrolysis

*Singapore Med J 2009;50(1):29-33*

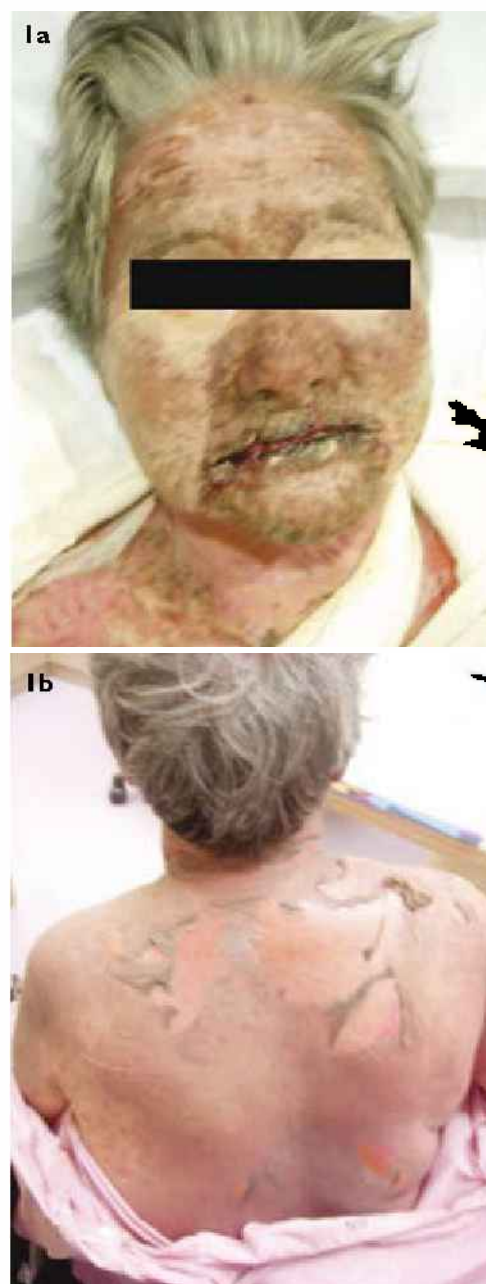## INTRODUCTION

Toxic epidermal necrolysis (TEN) is an acute idiosyncratic drug reaction associated with high mortality. Definitive treatment includes identification and stopping the ingestion of the possible culprit medication, as well as good supportive therapy. In this case review, we share our experience with the use of intravenous immunoglobulin (IVIG) in six patients with TEN.

## CASE SERIES

### Case 1

A 75-year-old Chinese woman with a history of non-insulin dependant diabetes mellitus, hypertension, hypercholesterolaemia and gout, presented with fever and generalised body rash of two days duration. She had bilateral purulent eye discharge and extensive maculopapular rash. Allopurinol and amoxicillin prescribed two weeks prior were promptly stopped and oral prednisolone at 0.5 mg/kg was started. By the next day, she developed lip and genitalia erosions and epidermal detachment of 6% total body surface area (TBSA) (Fig.1). She was diagnosed with Steven-Johnson syndrome (SJS). A skin histology



**Fig. 1** Clinical photographs show (a) erosions and crusting on face and oral mucosa; and (b) desloughing of the detached epidermis on the trunk.

revealed subepidermal bullae and apoptotic keratinocytes which were consistent with TEN. The severity-of-illness score for TEN (SCORTEN) on admission was one, based on her age (Table I). IVIG was administered over three days (total 3 g/kg) in the intensive care unit along with

Department of  
Dermatology,  
Changi General  
Hospital,  
2 Simei Street 3,  
Singapore 529889

Teo L, MD  
Registrar

Tay YK, MD  
Senior Consultant  
and Chief

Liu TT, MD  
Senior Consultant

Kwok C, MD  
Senior Consultant

**Correspondence to:**  
Dr Lynn Teo  
Tel: (65) 6850 3599  
Fax: (65) 6788 0933  
Email: lynnteohweeying  
@hotmail.com

**Table I. Seven independant variables for SCORTEN.**SCORTEN variables (weight of 1 for each)<sup>(25)</sup>

Age ( $\geq 40$  years)  
 Heart rate ( $\geq 120$  beats per minute)  
 Cancer/haematologic malignancy  
 TBSA involved at day 1 ( $> 10\%$ )  
 Serum urea level ( $>10$  mmol/L)  
 Serum bicarbonate level ( $< 20$  mmol/L)  
 Serum glucose level ( $>14$  mmol/L)

TBSA: total body surface area; SCORTEN: severity-of-illness score for toxic epidermal necrolysis.

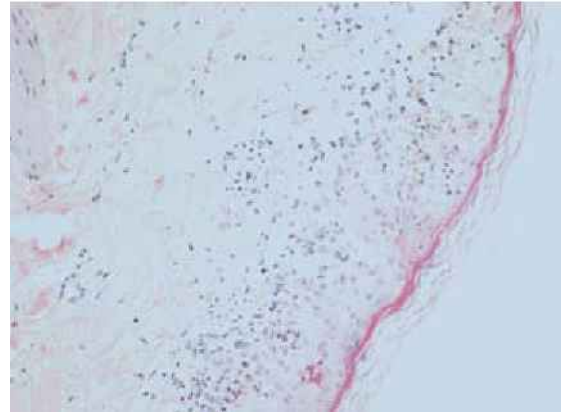
supportive therapy and close monitoring. By day three post-IVIG, her condition had stabilised with no new erosions. Maximal TBSA of detached and detachable skin was 15%. Her hospital stay was complicated by *Pseudomonas aeruginosa* and methicillin-resistant *Staphylococcus aureus* skin infection for which she was given amikacin and vancomycin. She also had a *Klebsiella* urinary tract infection that was resolved with teicoplanin and gentamycin. She was subsequently discharged well after a prolonged rehabilitation six weeks later.

**Case 2**

A 57-year-old Chinese woman with atrial fibrillation due to mitral stenosis presented with severe skin pain, generalised targetoid maculopapular rash, lip erosions and bilateral injected conjunctiva. This progressed over the next two days to involve the genitalia with epidermal detachment of 1% TBSA despite the administration of oral prednisolone at 0.5 mg/kg. She was diagnosed with SJS due to cloxacillin given a week prior for thrombophlebitis. This was confirmed on skin biopsy with subepidermal bullae and apoptotic keratinocytes. SCORTEN was three at presentation based on age, a raised serum urea level and a low bicarbonate level. A total of 3 g/kg of IVIG was administered in the intensive care unit with supportive therapy. Maximal epidermal involvement was 30% and her condition stabilised five days post-IVIG. She experienced severe skin tenderness which was relieved with morphine. Her stay was complicated by a *Klebsiella* urinary tract infection. She was well when discharged after four weeks.

**Case 3**

A 46-year-old Chinese woman with schizophrenia and epilepsy presented with fever, generalised body rash, bilateral red eyes and a sore throat. On examination, she had confluent maculopapular rash, erosions on her oral mucosa and genitalia, as well as injected conjunctiva. She was diagnosed of TEN due to carbamazepine prescribed two weeks earlier for seizures. A punch biopsy correlated with the diagnosis of subepidermal bullae (Fig. 2). SCORTEN



**Fig. 2** Photomicrograph shows the vacuolar change in the basal layer of epidermis with early separation of the basal layer from the papillary dermis. Apoptosis of individual keratinocytes is noted (arrows) (Haematoxylin & eosin,  $\times 20$ ).

was one at presentation based on age. IVIG at 3 g/kg was initiated in the intensive care unit with supportive treatment. New skin involvement stopped at six days post-IVIG. There were no complications and she was well when discharged three weeks later.

**Case 4**

A 30-year-old Malay woman who had defaulted treatment for scleroderma presented with fever, generalised maculopapular rash and lip erosions one week after being given cephalexin for an upper respiratory tract infection. Four days later, she developed flaccid bullae and the TBSA involved was 3%. Genitalia erosions developed at the same time. Maximal skin involvement was 5%. She was diagnosed with SJS, and IVIG (total 3 g/kg) was administered in the intensive care unit. A skin biopsy revealing subepidermal bullae and apoptotic keratinocytes confirmed the diagnosis. SCORTEN was one at the time of diagnosis based on a raised serum urea level. The rash stopped progressing by day seven post-IVIG. She developed a urinary tract infection that responded to ciprofloxacin. She also had severe pain in her fingers due to Raynaud's phenomenon and was given pentoxifylline. She was well when discharged two weeks after admission.

**Case 5**

A 84-year-old Chinese woman with ischaemic heart disease, depression and a previous cerebrovascular accident was admitted for fever and a pruritic rash. She had a generalised maculopapular rash with bilateral eye involvement. The next day, oral erosions appeared and she had epidermal detachment of 1% TBSA that went on to maximally involve 4% of the body. She had SJS due to allopurinol given for hyperuricaemia one week prior. A punch biopsy with subepidermal bullae and apoptotic keratinocytes was consistent with the diagnosis. SCORTEN

**Table II. Clinical data of the six patients.**

Age (years) / gender	Suspected drugs	% TBSA	Diagnosis, SCORTEN	Days from start of rash	Days in hospital to start of IVIG	Outcome
75/F	Allopurinol, amoxicillin	15	SJS/TEN, 1	4	61	Alive
57/F	Cloxacillin	30	TEN, 3	4	51	Alive
46/F	Carbamazepine	50	TEN, 1	2	20	Alive
30/F	Cephalexin	5	SJS, 1	5	18	Alive
84/F	Allopurinol	4	SJS, 3	2	13	Dead
41/M	Amoxicillin	70	TEN, 3	2	56	Alive

TBSA: total body surface area; SCORTEN: severity-of-illness score for toxic epidermal necrolysis.

was three at presentation based on age, raised serum urea and low bicarbonate levels. Allopurinol was immediately discontinued, and IVIG (total 3 g/kg) which was initiated in the intensive care unit, promptly halted the progression of her skin lesions. However, her hospitalisation was complicated by Gram-positive septicaemia, acute renal failure and acute cholecystitis, which eventually culminated in her death two weeks later.

#### Case 6

A 41-year-old Malay man with hypertension was admitted for an extensive rash and breathlessness. On arrival, he had epidermal detachment of 30% TBSA that rapidly progressed to a peak of 70% TBSA. He had injected conjunctivae, buccal and genitalia mucosal erosions and was tachypnoeic with audible wheezing. He had TEN due to amoxicillin given for an upper respiratory tract infection the day before. Serologies for *Mycoplasma* were negative. A punch biopsy over a characteristic lesion revealed subepidermal bullae consistent with the diagnosis. SCORTEN was three at presentation based on age, raised serum glucose and the extent of epidermal detachment. IVIG (total 3 g/kg) was initiated in the intensive care unit. Re-epithelialisation was seen after seven days post-IVIG with complete skin healing after one month. The initial cause of his breathlessness was attributed to adult respiratory distress syndrome and required supportive ventilation. His hospitalisation was complicated by extensive rhabdomyolysis and acute renal failure that required continuous veno-venous haemofiltration. He also had a moderately raised transaminitis and myocardial injury likely due to the extensive drug reaction. He went on to develop a nosocomial pneumonia that resolved with aztreonam. Skin swabs grew *Pseudomonas aeruginosa* and *Candida*, which were treated with ciprofloxacin and fluconazole. The patient was well when she was discharged after two weeks of rehabilitation.

Clinical data of the six patients are summarised in Table II.

#### DISCUSSION

TEN is an acute idiosyncratic drug reaction associated

with a high mortality. It is a result of extensive keratinocyte apoptosis that is seen characteristically on histology as the sloughing of large areas of skin at the dermal-epidermal junction. Prognosis depends largely on the extent of skin involved. Prompt diagnosis, stopping the suspected drug and rapid initiation of supportive treatment remain the mainstay of management. Common drugs implicated in TEN include sulphonamides, allopurinol anti-convulsants, penicillins and non-steroidal anti-inflammatory agents. The list is not exhaustive and many case reports exist in the literature of different medications causing TEN. The SCORTEN score is a useful tool in predicting mortality in TEN. It is a sum of seven parameters calculated within 48 hours of admission to an intensive care unit. If more than five parameters are present, the predicted mortality rate is more than 90%. Most of our patients had low scores of one to two, and this predicts mortality at 3%–12%, which is consistent clinically. Of the two patients with scores of three and a predicted mortality of 30%, one died. We find the SCORTEN useful in counselling patients and relatives with regard to prognosis (Table I).

As with most adverse drug reactions, TEN is a major histocompatibility complex (MHC) class I restricted reaction. More unique though is the increased number of TEN patients who are HLA-B12 positive, implying the underlying role of genetic susceptibility in this disease.<sup>(1)</sup> Recently, Hung et al demonstrated that the HLA-B 1502 gene in the Han Chinese may predispose them to carbamazepine induced TEN-SJS.<sup>(2)</sup> In our hospital, five of six patients in the last three years were female. There is no evidence of a gender predominance in the literature and this can be attributed to the limited number of patients given the rarity of the condition. A few mechanisms have been suggested to account for this extensive immunological reaction to certain drugs. Drug specific T-cell release of perforin granzyme-mediated cytotoxicity has been demonstrated by Nassif et al in patients with TEN.<sup>(3)</sup> This pathway occurs simultaneously with Fas ligand (FasL) expression which have been hypothesised as the death ligand induced for abnormal apoptosis of epidermal cells. Viard et al demonstrated that serum FasL is increased in

these patients. This is the basis for the use of intravenous IVIG in TEN. Pooled human immunoglobulin contain anti-Fas antibodies that have been shown *in vitro* to impede apoptosis when pre-incubated with keratinocytes.<sup>(4)</sup>

Serum FasL levels have been shown to fluctuate with the progression of the disease. Chang et al demonstrated that FasL levels monitored using enzyme immunosorbent assays rose with the appearance of extensive skin bullae and returned to baseline within days once the condition stopped progressing.<sup>(5)</sup> Cytokines, such as interleukin-6 and tumour necrosis factor-alpha (TNF-alpha), are increased in the lesional skin of patients with TEN. Chave et al have suggested another possible pathway in the pathogenesis of skin lesions in TEN, involving the TNF-alpha receptor-1 death pathway.<sup>(6)</sup> This may explain the rapid clinical improvement seen in a handful of patients given TNF-alpha inhibitors such as infliximab as treatment. Humoral immunity may also be involved in TEN as clinical presentation occurs up to three to four weeks after being administered the suspected drug. This period of sensitisation as well as the earlier onset of disease if patients are given the same drug again lend weight to this hypothesis. Park et al also noticed that the mucocutaneous reaction in TEN is similar to that seen in paraneoplastic pemphigus, which is a disease involving auto-antibodies to periplakin, a 190-kDa protein. They demonstrated that patients with TEN have similar circulating auto-antibodies to periplakin, further supporting a humoral role.<sup>(7)</sup>

IVIG interferes with death ligand induced apoptosis.<sup>(4)</sup> Initial results have been promising, to the extent that many centres routinely use IVIG in patients with TEN. Doses used range between 0.8 and 4 g/kg administered over 1–4 days. Recently, Paquet et al demonstrated that immunoglobulin G (IgG) levels in the serum and from the lesional skin are raised in patients with TEN after being infused with IVIG, while remaining low in patients who are provided supportive therapy only. In addition, intraepidermal IgG levels were elevated in the involved and uninvolved skin of these treated patients which was not seen in the patients receiving supportive care. They concluded that the infusion of IVIG can provide protection to the keratinocytes in patients with TEN, and so help limit the disease progression.<sup>(8)</sup> In addition, early infusion of IVIG can convey this protection as soon as the diagnosis is made, and further limit the massive apoptosis of keratinocytes.<sup>(9)</sup> The earlier enthusiasm for IVIG has been tempered by other studies showing that it did not significantly benefit patients with TEN and may even be harmful, especially in patients with renal impairment.<sup>(10-12)</sup> Ultimately, a large randomised controlled trial on the use of IVIG in patients with TEN will have to be carried out to clarify this point.

A local series by Tan et al described 12 patients with either SJS/TEN or TEN and administered IVIG at 1.5–2

g/kg in total. The demographics of the patients and results appear to be similar.<sup>(13)</sup> In our series, it took 2–7 days from the onset of symptoms to the start of IVIG. However, all our patients received 3 g/kg of IVIG as results from other centres showed increased survival with higher doses of IVIG, limited only by the side effects. Our patients did not experience any adverse events at this dosage. We believe slow infusion rates and close fluid and electrolyte monitoring are essential to avoid adverse events. In the past, corticosteroids have been traditionally used in the treatment of TEN. Intravenous steroids in most published articles did not alter the course of the illness and in fact may prove harmful by possibly increasing the risk of infection, prolonging wound healing and promoting gastrointestinal bleeding. Conversely, other small case series have demonstrated that high dose short-term corticosteroids may improve survival. Doses of corticosteroid used have been as high as prednisolone at 400 mg/day initially and slowly tailing down over 4–6 weeks.<sup>(14)</sup> The use of corticosteroids in TEN remains controversial.

High-dose IVIG is now used to treat many autoimmune and inflammatory diseases, and while beneficial, has its own list of side effects. Most are not severe, but occasionally may lead to anaphylaxis and acute renal failure. Fortunately, close monitoring during the infusion of IVIG and taking careful steps to tailor the dose to the patient can minimise these side effects. All the patients in our series did not experience adverse events related to IVIG. Vecchiotti et al recently published an article characterising a severe eczematous reaction that occurs initially on the palms and soles followed by a pruritic maculopapular exanthem involving the whole body approximately ten days after the infusion of IVIG.<sup>(15)</sup> This appears to be an uncommon adverse event but should be recognised as it may complicate the clinical picture of TEN. An interesting use of IVIG is as prophylaxis for SJS or TEN. This was used successfully in a patient with recurrent SJS to intravenous contrast dye.<sup>(16)</sup>

As cytokines, such as interleukin-6 and TNF-alpha, are found in higher quantities in lesional skin in TEN, anti-TNF-alpha agents such as infliximab have been used with success in a handful of patients.<sup>(17,18)</sup> Cyclosporin has also been demonstrated to be useful in TEN with no reported mortality associated with its use. As cyclosporin inhibits CD8, extensive epidermal destruction may be reduced. Furthermore, it appears to shorten the duration of active disease within 24–36 hours and time to complete re-epithelialisation.<sup>(19)</sup> This has been seen at doses of 3–5 mg/kg/day either administered orally or intravenously. The duration of the use of cyclosporin ranged from eight to 24 days in various reports, and tapered off until re-epithelialisation occurred. Similar effects had been seen with the use of intravenous cyclophosphamide in a handful of patients. It was administered at doses of 300 mg/day

initially, tapering to 100 mg/day for up to six days.<sup>(20)</sup>

Plasmapheresis appears to be promising as an alternative modality. In a review by Egan et al, six patients underwent daily exchanges until 24 hours had elapsed without the appearance of new blisters. There was no mortality in this group of patients.<sup>(21)</sup> Recently, it was used in a patient with TEN and AIDS with good effect.<sup>(22)</sup> However, plasmapheresis is a labour-intensive and costly procedure and carries a risk of transfusion-associated complications. Intravenous N-acetylcysteine (300 mg/kg/day) also appears to be beneficial in a few patients with TEN by decreasing the time to re-epithelialisation.<sup>(23)</sup> The only medication to date that has clearly shown no benefit or even increases the mortality rate is thalidomide. It has been postulated that this may have been a result of a paradoxical rise in TNF-alpha levels caused by thalidomide.<sup>(24)</sup>

Supportive management still remains the mainstay of the treatment of TEN. This involves skilled clinical assessment with early identification of the culprit drug and immediate withdrawal. Close fluid and electrolyte monitoring in an intensive care setting is optimal. Antibiotics should also be considered in the event of infection. Constitutional symptoms such as skin pain or fever need to be addressed as all our patients experienced some discomfort in this aspect. All our patients were admitted to the intensive care unit within two days of admission where they were monitored closely. In addition, they were given topical or systemic antibiotics or both for concomitant infections. Emphasis was placed on good local treatment and meticulous wound care such as loose dressings without adhesives as well as minimal skin handling to prevent further damage to the skin. Good eye care with early referral to the ophthalmologist and good oral care were instilled in all patients to avoid complications. Five of the six patients survived with no morbidity.

In summary, TEN is a devastating disease and is difficult to halt once in progression. The use of IVIG is still controversial, but it has its proponents and appears to have benefited the patients in our series. We recommend a total dose of 3 mg/kg of IVIG based on our experience. However, IVIG is costly in Singapore. The patient, as well as family members, need to be counselled extensively and have their expectations managed.

#### ACKNOWLEDGEMENT

We would like to thank Dr Kent Mancer for assisting with the histology.

#### REFERENCES

- Roujeau JC, Huynh TN, Bracq C, et al. Genetic susceptibility to toxic epidermal necrolysis. *Arch Dermatol* 1987; 123:1171-3.
- Hung SI, Chung WH, Jee SH, et al. Genetic susceptibility to carbamazepine-induced cutaneous adverse drug reactions. *Pharm Genom* 2006; 16:297-306.
- Nassif A, Bensussan A, Boumsell L, et al. Toxic epidermal necrolysis: effector cells are drug-specific cytotoxic T cells. *J Allergy Clin Immunol* 2004; 114:1209-15.
- Viard I, Wehrli P, Bullani R, et al. Inhibition of toxic epidermal necrolysis by blockade of CD95 with human intravenous immunoglobulin. *Science* 1998; 282:490-3.
- Chang HY, Cooper ZA, Swetter SM, Marinkovich MP. Kinetics and specificity of Fas ligand infuaction in toxic epidermal necrolysis. *Arch Dermatol* 2004; 140:242-4.
- Chave TA, Mortimer NJ, Sladden MJ, Hall AP, Hutchinson PE. Toxic epidermal necrolysis: current evidence, practical management and future directions. *Br J Dermatol* 2005; 153:241-53.
- Park GT, Quan G, Lee JB. Sera from patients with toxic epidermal necrolysis contain autoantibodies to periplakin. *Br J Dermatol* 2006; 155:337-43.
- Paquet P, Kaveri S, Jacob E, et al. Skin immunoglobulin deposition following intravenous immunoglobulin therapy in toxic epidermal necrolysis. *Exp Dermatol* 2006; 15:381-6.
- Yeung CK, Lam LK, Chan HH. The timing of intravenous immunoglobulin therapy in Stevens-Johnson syndrome and toxic epidermal necrolysis. *Clin Exp Dermatol* 2005; 30:600-2.
- Shortt R, Gomez M, Mittman N, Cartotto R. Intravenous immunoglobulin does not improve outcome in toxic epidermal necrolysis. *J Burn Care Rehabil* 2003; 24:S88.
- Brown KM, Silver GM, Halerz M, Walaszek PS, Gamelli RL. Toxic epidermal necrolysis syndrome: does IgG make a difference? *J Burn Care Rehabil* 2003; 24:S87.
- Bachot N, Revuz J, Roujau J-C. Intravenous immunoglobulin treatment for Stevens-Johnson syndrome and toxic epidermal necrolysis. *Arch Dermatol* 2003; 139:33-6.
- Tan AW, Thong BY, Yip LW, Chng HH, Ng SK. High-dose intravenous immunoglobulins in the treatment of toxic epidermal necrolysis: An Asian series. *J Dermatol* 2005; 32:1-6.
- Tegelberg-Stassen MJAM, van Vloten WA, Baart de la Faille H. Management of nonstaphylococcal toxic epidermal necrolysis: Follow-up study of 16 case histories. *Dermatologica* 1990; 180:124-9.
- Vecchiotti G, Kerl K, Prins C, et al. Severe eczematous skin reaction after high-dose intravenous immunoglobulin infusion: report of 4 cases and review of the literature. *Arch Dermatol* 2006; 142:213-7.
- Hebert AA, Bogle MA. Intravenous immunoglobulin prophylaxis for recurrent Stevens-Johnson syndrome. *J Am Acad Dermatol* 2004; 50:286-8.
- Hunger RE, Hunziker T, Buettiker U, Braathen LR, Yawalkar N. Rapid resolution of toxic epidermal necrolysis with anti-TNF-alpha treatment. *J Allergy Clin Immunol* 2005; 116:923-4.
- Fischer M, Fiedler E, Marsch WC, Wohlrab J. Antitumor necrosis factor-alpha antibodies (infliximab) in the treatment of a patient with toxic epidermal necrolysis. *Br J Dermatol* 2002; 146:707-9.
- Khalili B, Bahna SL. Pathogenesis and recent therapeutic trends in Stevens-Johnson syndrome and toxic epidermal necrolysis. *Ann Allergy* 2006; 97:272-81.
- Trautmann A, Klein CE, Kampgen E, Brocker EB. Severe bullous drug reactions treated successfully with cyclophosphamide. *Br J Dermatol* 1998; 139:1127-8.
- Egan CA, Grant WJ, Morris SE, et al. Plasmapheresis as an adjunct treatment in toxic epidermal necrolysis. *J Am Acad Dermatol* 1999; 40:458-61.
- Nomura T, Abe R, Fujimoto K, et al. Plasma exchange; a promising treatment for toxic epidermal necrolysis with AIDS. *AIDS* 2004; 18:2446-8.
- Redondo P, de Felipe I, de la Pena A, et al. Drug induced hypersensitivity syndrome and toxic epidermal necrolysis. Treatment with N-acetylcysteine. *Br J Dermatol* 1997; 136:645-6.
- Wolkenstein P, Latarjet J, Roujeau JC, et al. Randomised comparison of thalidomide versus placebo in toxic epidermal necrolysis. *Lancet* 1998; 352:1586-9.
- Bastuji-Garin S, Fouchard N, Berticchi M, et al. SCORTEN: A severity-of-illness score for toxic epidermal necrolysis. *J Invest Dermatol* 2000; 115:149-53.