Diagnostic transgastric flexible peritoneoscopy: is pure natural orifice transluminal endoscopic surgery a fantasy?

Hyder Q, Zahid M A, Waqar S H, Rashid R, Hadi S F, Qazi S, Haider H K H

ABSTRACT

We present the first transgastric peritoneoscopy in a 20-year-old man. The objectives were to evaluate the impact of the site of viscerotomy on the technical feasibility of natural orifice transluminal endoscopic surgery (NOTES), assess transgastric peritoneoscopy as a complementary procedure, determine the safety and efficacy of NOTES, and attempt inspection/biopsy of the gallbladder. The patient was admitted with a benign gastric outlet obstruction, chronic cholecystitis and radiological suspicion of a mass in the gallbladder which was not visualised on diagnostic laparoscopy. Complementary transgastric peritoneoscopy was performed to gain deeper penetration of the tumour with the flexible tip of the gastroscope. The visceral "aperture" was created in the antrum where gastrojejunal anastomosis would be fashioned. Laparoscopic transillumination of the anterior gastric wall facilitated this part of the procedure. During transgastric peritoneoscopy, the gallbladder and structures in the upper and left hemi-abdomen appeared retrograde due to the unusual location of the gastrotomy. The right hemi-abdomen and pelvis were easily examined with a "straight shaft" approach. The gallbladder could not be identified with exploratory laparoscopy and transgastric peritoneoscopy. Due to risk of visceral injury, open gastrojejunal anastomosis and cholecystectomy were performed. Intraoperatively, an inflamed, thick-walled gallbladder was found adherent to the proximal duodenum. Transgastric peritoneoscopy was safely performed in our patient. The postoperative course was uneventful. Our patient showed significant improvement at 13 weeks after surgery without any procedure-related complication. In conclusion, transgastric peritoneoscopy may be used to complement diagnostic laparoscopy. Laparoscopic assistance during transluminal access facilitates simple tasks inside the peritoneal cavity to be performed safely.

Keywords: natural orifice transluminal endoscopic surgery, peritoneoscopy, transgastric peritoneoscopy, transluminal access

Singapore Med J 2008;49(12):e375-e381

INTRODUCTION

Natural orifice transluminal endoscopic surgery (NOTES) represents transluminal diagnostic or resective intervention within the abdominal cavity by introducing a flexible endoscope through a natural orifice. The potential benefits of a "scarless" and "incisionless" access to the peritoneal cavity lack scientific evidence at present. NOTES is, therefore, widely regarded as an "experimental alternative" to conventional and laparoscopic surgeries. The popular advantages of NOTES include the absence of trauma to the abdominal wall, little pain or scarring and a shorter hospital stay.[1] Transgastric peritoneoscopy was first described in porcine models in 2004.[2] Tubal ligation, oophorectomy, gastrojejunostomy, liver biopsy, cholecystectomy, appendectomy and lysis of adhesions are some of the transluminal procedures on record. Pai et al have claimed success in transcolonic exploration in animals.[3] Experimental transgastric resections with telerobots were also reported.[4] Rao and Reddy carried out the first transgastric appendectomy in humans, in 2006.[5] It was followed by successful transvaginal cholecystectomy in France and the USA, in 2007.[6] In spite of several controversies, NOTES has emerged as the ultimate goal of many endoscopists and surgeons. We have conducted the first transgastric peritoneoscopy in humans. The location of viscerotomy should preferably allow "straight" access to the target organ with minimal retroflexion of the endoscope. In our opinion, transluminal peritoneoscopy has the potential to complement diagnostic laparoscopy in future. We believe that sincere interdisciplinary collaboration is vital to the development of NOTES. Laparoscopic assistance allowed us to avoid visceral injury in our patient during transluminal access to the peritoneal cavity. The laparoscopic-endoscopic hybridisation currently offers better homeostasis, reliable closure of the viscerotomy and safety during NOTES intervention.

Department of Gastroenterology, Pakistan Institute of Medical Sciences, G-8/3, Islamabad, Pakistan

Hyder Q, FCPS
Assistant Professor

Department of General Surgery

Zahid MA, FCPS
Associate Professor

Waqar SH, FCPS
Assistant Professor

Rashid R, FCPS
Assistant Professor

Hadi SF, FRCP
Executive Director

Qazi S, MBBS
House Officer

Department of Pathology and Laboratory Medicine, University of Cincinnati, 231 Albert Sabin Way, Cincinnati, OH 45267-0529, USA

Haider HKH, PhD
Research Scientist

Correspondence to:
Dr Qurratulain Hyder
Tel : (51) 926 1170
Email: ghyder2194@hotmail.com

CASE REPORT

The patient is a 20-year-old man who was admitted to our surgical unit on May 14, 2007, with a diagnosis of benign gastric outlet obstruction and gallstone disease. The presenting symptoms were postprandial epigastric distension, pain and vomiting for 2½ years. The pain was dull and boring in character. It was constant, localised and usually bearable. However, there were frequent episodes of severe, sharp and stabbing pain in the epigastric and right hypochondrial regions with radiation to the right lower chest, interscapular region and the upper back. These attacks were triggered by food intake, but also occurred spontaneously. There was temporary relief after vomiting and on consumption of "warm liquids". The vomiting was projectile, sour and malodorous. It was occasionally coffee-ground but often contained food consumed a few days earlier. There was preceding nausea and a subjective feeling of "a rolling ball of gas" in the upper abdomen. The bowels were scanty and infrequent. The stools were intermittently black, tarry and foul smelling. These complaints were associated with excessive belching, anorexia, generalised weakness and mild weight loss. There was no history of fever, jaundice, pruritus, rectal bleeding, arthralgias or urinary and respiratory symptoms.

In November 2005, he was admitted at a private clinic for two whole blood transfusions. He admitted having received analgesics for myalgias and body aches. The course of illness was gradually progressive and the symptoms became unresponsive to outpatient general practitioner management at least three months before admission to our hospital. The past history was suggestive of recurrent acute appendicitis. Open appendectomy was performed in December 2003. He remained asymptomatic for about ten months after the surgery. Our patient denied any habituation, addiction or self-medication. There was no family history of tuberculosis, cholelithiasis, acid peptic disorder and inflammatory bowel disease.

On general physical examination, there was mild dehydration, moderate anaemia and inadequately preserved nutritional status. The blood pressure was 105/70 mmHg. The patient was anicteric and afebrile. There was no clubbing, pedal oedema or ascites. The scar of the previous appendectomy was visible in the right lower quadrant. The abdomen was grossly distended in the epigastric region, where mild tenderness could be elicited on deep palpation. The percussion note was resonant in the upper abdomen and a succussion splash was audible. The liver span was normal and no abdominal mass was palpable. The gut sounds were sluggish. There was no other systemic abnormality on clinical examination. The preliminary diagnostic evaluation was conducted during his random visits to the medical doctor and is summarised in Table I.

Table 1. Preliminary diagnostic evaluation of the patient.

Total leucocytes 7,600/mm^3 (polymorphs: 55.1%; lymphocytes: 25%)
Platelet count: 41,3000/mm^3
Haemoglobin: 8.1 g/dL
Mean corpuscular volume: 71.7 fl
Erythrocyte sedimentation rate: 7 mm/lst hour
Serum bilirubin: 0.4 mg/dL
Serum alanine aminotransferase: 13 IU/L
Serum alkaline phosphatase: 124 IU/L
Blood urea-nitrogen: 25 mg/dL
Serum creatinine: 0.7 mg/dL
Prothrombin time: 17 s (control: 15 s)
Serum amylase: 89 U/L
Blood glucose: 103 mg/dL
Serum K+: 3.7 mEq/L
Serum Na+: 131 mEq/L
Serum albumin: 3.4 g/dL

Urine analysis and renal function tests were normal. Mantoux intradermal reaction was negative. The chest radiograph was normal. An erect abdominal radiograph showed an enlarged gastric shadow with air-fluid level in the fundic region. The bowel loops were mildly dilated, but there was no evidence of mechanical obstruction. Abdominal ultrasonography (US) done on April 9, 2007 demonstrated a solitary gallstone, measuring 20 mm in diameter. The wall of the gallbladder was reported as significantly thick and vascular. It measured up to 12 mm in thickness, raising the possibility of a neoplasm. US of the liver, common bile duct, pancreas, kidneys, urinary bladder and prostate was unremarkable. There was no free fluid in the peritoneal cavity and the retroperitoneal space was normal. On computed tomography (CT) of the abdomen done on May 7, 2007, the gallbladder was not visualised (Fig. 1a). There was no evidence of biliary dilatation or focal lesion in the liver and pancreas. The stomach was enormously distended due to gastric outlet obstruction. The bowel loops showed mild dilatation (Fig. 1b). Other abdominal viscera were normal. No abdominal lymphadenopathy, ascites or pleural effusion was seen. The gallbladder was barely identified on US performed after CT. The radiologist supported the previous diagnosis of chronic (calculous) cholecystitis, with suspicion of an isodense mass in the gallbladder.

During initial hospitalisation, the patient was kept nil by mouth and had a central line inserted. He showed significant clinical improvement with total parenteral nutrition and fluid support over the next 12 days. Three units of whole blood were transfused for correction of anaemia. The stomach was thoroughly washed with normal saline prior to flexible upper gastrointestinal endoscopy on May 19, 2007. It revealed complete gastric outlet obstruction in the postbulbar region. No duodenal lesion was detected. The mucosa in the stomach and distal oesophagus was moderately hyperaemic due to prolonged stasis and reflux of gastric contents. A small amount of

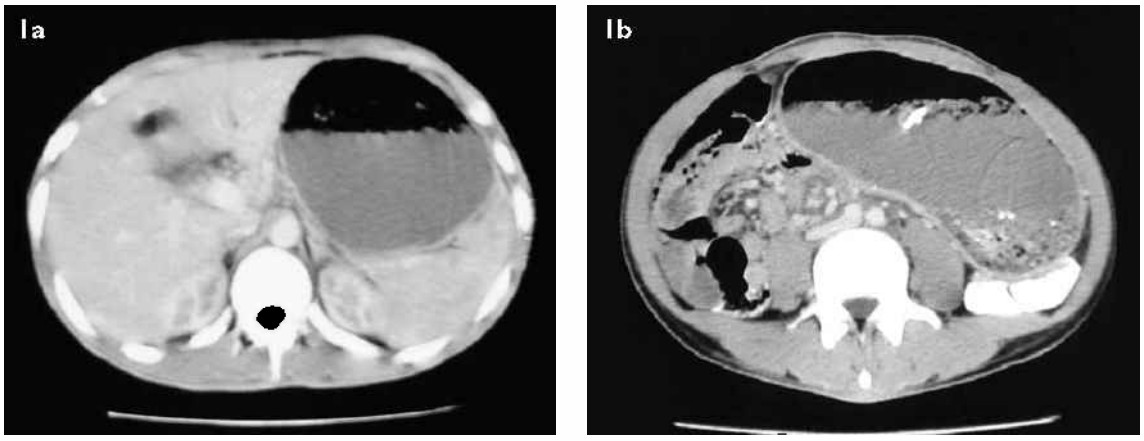

Fig. 1 Axial CT images show (a) non-visualisation of the gallbladder, and (b) enormous dilatation of the stomach.

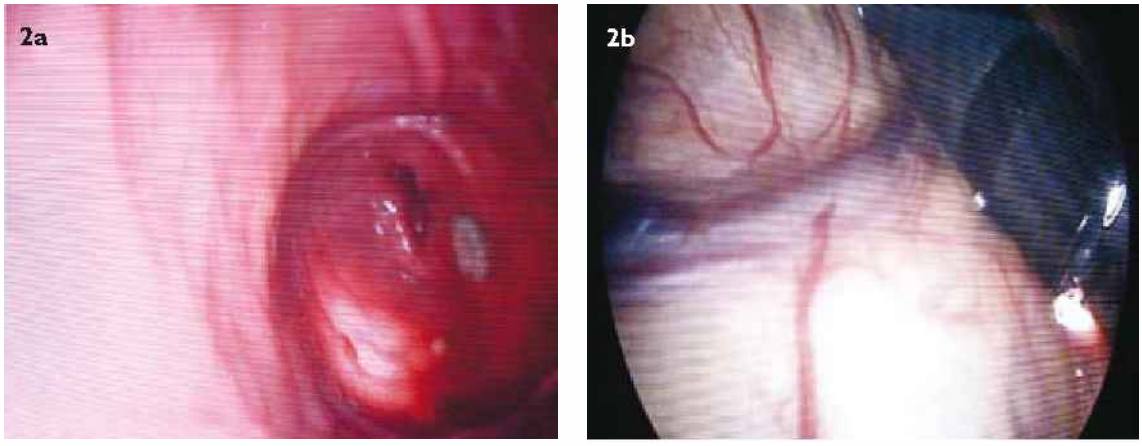

Fig. 2 Laparosopic photographs show (a) laparoscopic transillumination of the gastric antrum before viscerotomy, and (b) flexible gastroscope within the abdominal cavity.

retained food was present in the stomach. Laparoscopic cholecystectomy and gastrojejunostomy were scheduled on May 26, 2007. On exploratory laparoscopy, the gallbladder was not identified due to adhesions in the subhepatic region. Transgastric peritoneoscopy was performed as a complementary procedure. On account of the inferior location of the viscerotomy, there was little success in reaching the gallbladder for inspection and biopsy. Anticipating risk of visceral injury with laparoscopic intervention, the surgical team carried out open cholecystectomy and gastrojejunostomy.

Informed consent was obtained for laparoscopic and possibly open surgery, and for conducting an experimental procedure of diagnostic transgastric peritoneoscopy in the event that conventional laparoscopy failed to obtain adequate views. Intravenous antibiotics (ciprofloxacin 200 mg × 12 hourly, and metronidazole 500 mg × 8 hourly) were advised 48 hours before surgery. Exploratory laparoscopy was performed under general anaesthesia. A Veress needle was inserted in the infraumbilical region and CO_2 pneumoperitoneum was achieved up to a pressure of 13 mmHg. It was followed by introduction of a 30° telescope (Gimmi CET.0611.23) through an infraumbilical incision. The gallbladder was not visualised due to extensive adhesions and matting of viscera in the subhepatic region. The stomach was enormously dilated and prominent vessels were visible on its anterior surface. Postappendectomy adhesions were seen in the right iliac fossa. There was mild dilatation of the bowel loops without bowel discolouration and ileus. Transgastric exploration was deemed necessary to complement diagnostic laparoscopy by attempting deeper penetration of the subhepatic region with the flexible tip of the endoscope. Video gastroscope (Karl Storz 9.8 mm; single accessory channel 2.8 mm) was next introduced per orally. Needle knife (Boston Scientific 4 mm; microvasive) was passed through the scope. Approximately 6 cm proximal to the pylorus, a 1-cm horizontal incision was made on the anteroinferior aspect of the gastric antrum.

The site of antral "aperture" was selected to correspond with the location for subsequent gastrojejunal anstamosis. This step was facilitated by laparoscopic transillumination of the anterior gastric wall (Fig. 2a). The flexible gastroscope was introduced into the abdominal cavity through the antral opening (Fig. 2b). The accessible areas during transgastric peritoneoscopy were the anterior surface of the stomach, greater omentum, anterior parieties, and structures in the right hemi-abdomen, including postappendectomy

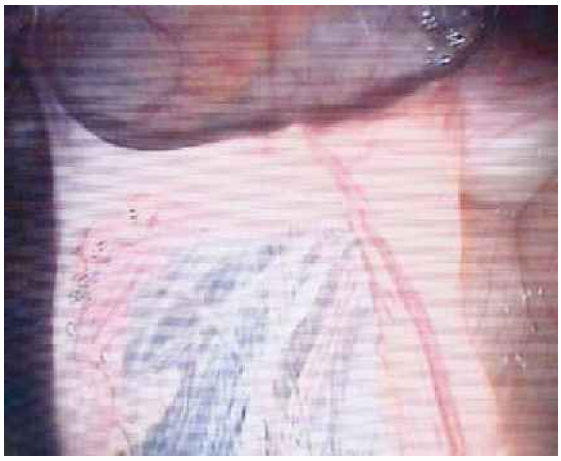

Fig. 3 Endoscopic photograph shows peritoneal adhesions from a previous appendectomy.

Fig. 4 Endoscopic photograph of the urinary bladder (anterior) and the rectum (posterior).

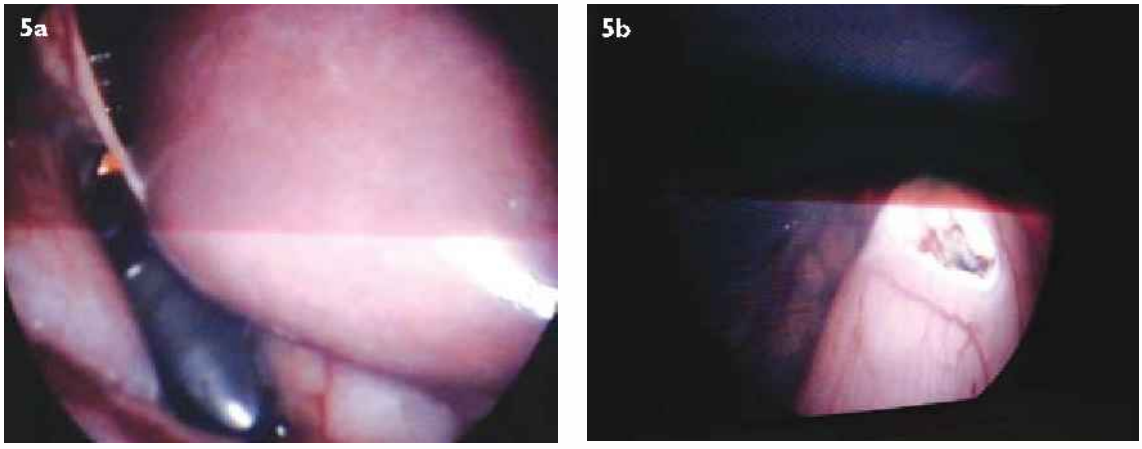

Fig. 5 (a) Photograph shows attempted visualisation of the subhepatic area with retroflexed endoscope. (b) Laparoscopic photograph of the antral viscerotomy (subsequently used for open gastrojejunal anastomosis).

adhesions (Fig. 3), part of the pelvis (Fig. 4) and mildly-distended gut loops in the mid-abdomen. There was no endoscopical evidence of bowel discolouration and atony, or presence of fluid, tubercles and nodules in the peritoneal cavity. The gallbladder was not identified. However, the inferior margin of the liver was approached with maximum retroflexion of the endoscope (Fig. 5a). It was due to the unusual location of gastrotomy in our patient (Fig. 5b). Anticipating a technically difficult laparoscopic operation, the surgical team decided in favour of laparotomy with a midline incision. Intraoperatively, a thick-walled gallbladder was seen adherent to the proximal duodenum in its postbulbar region. The affected segment of the duodenum was scarred and atretic. The regional anatomy was grossly distorted due to extensive peritoneal adhesions. No mass lesion was detectable in the gallbladder, liver, stomach, duodenum and pancreas. It appeared as if a minor leak from a duodenal ulcer had initiated the adhesive process, which was superimposed by recurrent attacks of (calculous) cholecystitis. The consequent matting of the local viscera and the thickened wall of the gallbladder were misinterpreted as mass lesion on serial radiological examinations. Open cholecystectomy was performed after lysis of adhesions, and viscerotomy was managed with gastrojejunal anastomosis. Histopathology of the gallbladder demonstrated mucosal hyperplasia and increased mucosal folds. The lamina propria was infiltrated with chronic inflammatory cells. There was no evidence of malignancy. The Rokitansky-Aschoff sinuses, lined with benign epithelium, were also seen in the muscular layer.

The postoperative recovery was uneventful. The antibiotics were discontinued four days after the surgery. The central line and drains were removed, and oral intake was permitted on the sixth postoperative day. The patient was discharged on June 4, 2007. In view of the transgastric procedure, he was advised regular follow-up at fortnightly intervals. There was significant subjective and clinical improvement at 13 weeks after surgery. There was no fever, jaundice, postprandial abdominal pain, distension or vomiting. The urine and stools were normal. His appetite improved and our patient gained > 2.5 kg in body weight. Upper gastrointestinal endoscopy repeated at four months post surgery revealed superficial anastomotic ulcers on the gastric side. There were no

postprandial symptoms, haemetemesis or malaena. He was advised to undergo acid suppressive therapy with proton pump inhibitors, and to have a repeat endoscopic evaluation after four months.

DISCUSSION

The current surge for NOTES has surpassed the enthusiasm for laparoscopic surgery, which was described as the "second French revolution" in 1987.[7] The medical experts are finding it difficult to reconcile with the paradox that intra-abdominal resections can be carried out by "creating a perforation", which would otherwise be dreaded by the endoscopists and surgeons alike. At the same time, difficulty in choosing between trauma and pain after conventional surgery or the risk of intraperitoneal haemorrhage/peritoneal sepsis with NOTES has generated a mass confusion. In fact, this "U-turn" has opened a pandora box of controversies. The major issues pertain to ethics, selection of patients, equipment, technique, funding for research/training, and interdisciplinary collaboration.[8] It will take several years before clinical NOTES is uniformly accepted as a reliable mode of treatment, like laparoscopic surgery.

The short-term safety of NOTES is established by several animal studies and a few successful operations in humans. It is encouraging to observe that the "experimentation" on animals has not lasted too long before its practical translation into "clinical trials" in India, France and the USA. The medical science has made progress only by "learning" on humans from "clinical methods" and adverse reactions of "thalidomide/chemoradiation" to the outcome of the first "human heart transplant" when immunosuppression was as primitive as NOTES is at present. Both favourable and fatal results of new modalities have been universally accepted as equally significant for the long-term benefit of mankind. It is because of the fact that the "experimentation" on animals cannot go on indefinitely. The recent NOTES procedures on humans augment our belief that a medical or surgical technique is ethical and justified as long as it is performed safely, no matter how "differently", with prior knowledge/consent of the patient and with the purpose of confirming/refuting or adding a new concept.

With the first clinical transgastric peritoneoscopy in a controlled environment, we have safely assessed the technical feasibility of NOTES with reference to the site of viscerotomy. It was performed as a complementary procedure when diagnostic laparoscopy failed to provide adequate information about the status of the gallbladder in our patient. For ethical reasons and unknown long-term complications of NOTES, approach to the gallbladder fossa was attempted by us without creating separate apertures in the gastric wall for transgastric peritoneoscopy and gastrojejunal anastomosis. The safety of the intervention was ensured by using laparoscopic transillumination for gastrotomy. It eliminated the risk of visceral damage and intraperitoneal bleeding in the present case. Magnetic resonance imaging and CT are also recommended for guided viscerotomy during NOTES.[9] It is interesting to note that the results of both transgastric and transcutaneous explorations were nearly the same in terms of clinical information on the suspected mass in the gallbladder. This complementary overlap between two separate techniques is observed during evaluation with other modalities in routine clinical practice. The peritoneal access, achieved with balloon dilatation, has the advantage of spontaneous closure. The viscerotomy is sometimes managed with a gastrostomy tube.[10] Gastrojejunal anastomosis in our patient provided the dual benefits of definitive treatment and safe closure of the antral aperture.

The use of the single channel flexible gastroscope without an overtube was considered sufficient because no therapeutic NOTES procedure was planned in our patient. We believe that the translocation of flora of the natural orifice is an inseparable though undesirable component of NOTES. The risk of bacterial contamination is considered insignificant from the transgastric access and would intuitively be higher in transcolonic explorations. The overtube can probably increase microbial translocation by virtue of its larger diameter and by contamination of the tip/shaft of the endoscope on its repeated removal. It can also result in mechanical interference by compromising the flexibility of the endoscope within the oesophageal lumen. The parenteral antibiotics and gastric acid apparently constitute an effective prophylaxis against bacterial translocation. The role of antibiotic lavage of the stomach, therefore, remains doubtful and the peritoneal spillage may even cause chemical irritation.

An ideal site for viscerotomy is undetermined. The transgastric route is generally preferred to other natural orifices. In our opinion, it is due to suitable length/easier handling of the forward viewing gastroscopes, besides a lower risk of contamination. We admit having little success in reaching the subhepatic region. It was primarily due to the unusual location of the "antral aperture". However, the inferior margin of the liver was reached in spite of a very low position of gastrotomy. It means that transgastric evaluation of the gallbladder could have been achieved in our patient by entering the peritoneal cavity through the anterosuperior aspect of the gastric antrum. This observation is in conformity with several animal studies about the impact of the site of viscerotomy on NOTES interventions.[11] Thus, the transgastric route may not remain ideally suited for therapeutic NOTES in the upper abdomen due

to the retrograde position of many structures. In our experience, a "straight shaft" approach from the opposite half of the peritoneal cavity is practically more suitable for the interventional endoscopist. We anticipate three subdivisions of the anterior gastric wall: "transantral access" for the right hemi-abdomen, "transfundic access" for the left hemi-abdomen, and a "pendulum access" through the midcorpus region for the viscera in the mid-abdomen and pelvis. The transurethral, transvaginal and transcolonic routes may be accepted similarly for NOTES in the anterior, middle and posterior planes of the pelvis/upper abdomen, respectively.

The endosurgeons have stretched their imagination for application of NOTES in accident victims and critically ill patients with bowel ischaemia.[12] How rational would it be to create "visceral perforation" in a patient with a pre-existing surgical abdomen remains to be seen. The creation of pneumoperitoneum in a person on assisted ventilation is like generating two positive pressures simultaneously. We know that a well-maintained pneumoperitoneum aggravates low flow states by decreasing the venous return. The presence of serosanguinous fluid, adhesions and matting of bowel loops in cases with abdominal sepsis, bowel infarction, granulomatous inflammation and malignancy renders even diagnostic laparoscopy technically far more difficult than in our patient. NOTES intervention seems virtually impossible under these circumstances. A natural orifice may not be the best route for retrieval of the resected organ. Surgical tasks, like resection, mobilisation, anastamosis and management of intraperitoneal bleeding appear too challenging to be handled independently by an endoscopist. There are claims about new endoscopic suturing techniques, which provide secure, full thickness closure of the visceral puncture.[13] It is pertinent to recall that suturing methods for gastroesophageal reflux disease are not very popular.[14] The results of endoscopic suturing in patients with ruptured "clean" ulcers due to drugs and acid injury may be different from those with bowel perforation secondary to enteric fever, tuberculosis and malignancy. The limited success of laparoscopic bariatric surgery is to be kept in mind before recommending NOTES in morbidly obese subjects.[15] On account of technical limitations of laparoscopic surgery, the cosmetic benefits appear to have been set aside with the advent of hand-assisted laparoscopic surgery.[16] The robotic surgery is being promoted for more precise and secure resection-anastomosis.[17] The control of iatrogenic bleeding within the abdominal cavity during NOTES is obviously more demanding than sclerotherapy of a spurting varix by the interventional endoscopist, considering the limited working space and poor resolution. The close proximity of structures and intestinal peristalsis may worsen the situation during active haemorrhage. If and when we overcome these practical limitations of NOTES, the closure of viscerotomy with T-bars or star/basket anchors will not remain an issue. The major concern should, therefore, be about our "way into" rather than "way out" of the abdomen while studying NOTES, lest we end up choosing a highly selective form of surgery in future.

NOTES may be "incisionless", but it is certainly not "scarless". Healing with fibrosis is a universal feature of any intraperitoneal intervention irrespective of the access through the parietal or visceral peritoneum. In laparoscopic surgery, postoperative peritoneal scarring is correlated with the number, size and location of ports. Thus it tends to involve even those abdominal quadrants, which have no existing pathology. The likelihood of peritoneal adhesions is increased if the visceral aperture is closed with a gastrostomy tube. Thus, a second NOTES intervention may become technically more difficult. It is similar to the effect of postinflammatory adhesions on diagnostic laparoscopy in our patient. The emergence of hand-assisted laparoscopic surgery and the ultimate reliance of laparoscopic/robotic/NOTES interventions on conventional surgery support our belief that the cosmetic benefit should not be interpreted as the principal advantage of NOTES. The safety, effectiveness and spectrum of NOTES are more important issues. NOTES *per se* is "surgery". We do not expect its physiological and immunological burden to be different from other forms of surgery. If operative trauma to the abdominal wall had a significant impact on the immune status,[18] then open surgery would not have been accepted as the treatment of choice in cancers and immunocompromised states.

It was approximately 90 years after the creation of the first pneumoperitoneum in 1901,[19] when laparoscopy gained popularity after some "hiccups" in 1985.[20] On the contrary, NOTES has made rapid progress. We have seen scores of animal studies and a few "clinical trials" in less than five years. Natural Orifice Surgery Consortium for Assessment and Research (NOSCAR) has allocated enormous funds for clinical, laboratory and industrial research. A new generation of endoscopic equipment with improved optics/triangulation and ability to lock into position are available.[21,22] It includes: R-scope, Cobra scope, Endoclips, The Stringer Device, EndoCinch and Eagle Claw.[23] Some researchers have suggested a separation of endoscope and accessories,[24] which may cause difficulty in depth perception, similar to laparoscopy. These advancements have given a boost and sophistication to the practice of endoscopy. On the other hand, the tactile perception and artistry of the human hand seem to be gradually replaced by robots and gadgets.

Several years will elapse before transluminal surgery becomes popular and NOTES paves its way into other disciplines, like gynaecology/obstetrics, urology, cardiothoracic surgery and neurosurgery. We believe that the learning curve is steeper for the endoscopist than for the surgeon, considering dissection/suturing and management of iatrogenic visceral damage/bleeding. In our experience, the presence of the laparoscope within the abdominal cavity is extremely reassuring for a NOTES interventionist to operate with confidence. Intraoperative enteroscopy and laparoscopy-guided endoscopic retrograde cholangiopancreatography are examples of the hybrid techniques in current practice. It is important to remember that NOTES *per se* is a hybrid of endoscopy and laparoscopy. The current "learning phase" of NOTES is probably the most logical explanation for endoscopic-laparoscopic hybridisation to avert surgical misadventures in humans. The concept of temporary hybridisation supports the rationality of "stepwise" learning. A hybrid approach is obviously less traumatic than open surgery. We, therefore, favour the application of the hybrid technique during (clinical) NOTES procedures in India, France and the USA. The hybridisation is vital not only for reasons of safety and interdisciplinary learning, but also for the survival of NOTES. The technical limitations of NOTES may even oblige us in the long run to accept hybrid procedures in routine medical practice. Laparoscopic-endoscopic hybridisation may become an indispensable component of the training programme for endoscopists in the forthcoming years. We even foresee the modified version of NOTES as two interventional endoscopists, or the endoscopist and laparoscopic surgeon, operate from opposite directions through separate natural orifices. More clinical procedures will enlighten us whether a temporary compromise on the cosmetic benefits of NOTES through hybridisation is relevant to its development, or the "experimentation" on animals has to go on for many more years.

We conclude that peroral, transgastric endoscopic peritoneoscopy in humans is a safe procedure. Laparoscopic guidance allows transgastric access to be accomplished in a secure and reliable manner. The site of viscerotomy is a crucial factor for diagnostic/therapeutic intervention by the transluminal route. A "straight shaft" approach provides easy access to the desired location within the peritoneal cavity. In our opinion, laparoscopic-endoscopic hybrid procedures constitute a logical way out of the present "learning phase" of NOTES. We support more "clinical trials" to establish the safety and efficacy of this amazing mode of treatment.

REFERENCES

1. Chung-Wang KO, Kalloo AN. Per-oral transgastric abdominal surgery. Chin J Dig Dis 2006; 7:67-70.
2. Kalloo AN, Singh VK, Jagannath SB, et al. Flexible transgastric peritoneoscopy: a novel approach to diagnostic and therapeutic interventions. Gastrointest Endosc 2004; 60:14-7.
3. Pai RD, Fong DG, Bundga ME, et al. Transcolonic endoscopic cholecystectomy: a NOTES survival study in a porcine model. Gastrointest Endosc 2006; 64:428-34.
4. Lehman AC, Rentschler ME, Farritor SM, Oleynikov D. Endoluminal minirobots for transgastric peritoneoscopy. Minim Invasive Ther Allied Technol 2006; 15:384-8.
5. Rao GV, Reddy N. Transgastric appendectomy in humans. Presentation at World Congress of Gastroentrology, Montreal, September 2006 [unpublished data].
6. de la Fuente SG, DeMaria EJ, Reynolds JD, Portenier DD, Pryor AD. NOTES: where it stands: new developments in surgery natural orifice transluminal endoscopic surgery (notes). Arch Surg 2007; 142:295-7.
7. Malik A, Mellinger JD, Hazey JW, Dunkin BJ, MacFadyen BV Jr. Endoluminal and transluminal surgery: current status and future possibilities. Surg Endosc 2006; 20:1179-92.
8. Pasricha PJ. NOTES: a gastroenterologist's perspective. Gastrointest Endosc Clin N Am 2007; 17:611-6, viii-ix.
9. Vosburgh KG, Estepar RSJ. Natural orifice transluminal endoscopic surgery (NOTES): An opportunity for augmented reality guidance. Studies Health Tech Informatics 2007: 15:485-90.
10. Onders RP, McGee MF, Marks J, et al. Natural orifice transluminal endoscopic surgery (NOTES) as a diagnostic tool in the intensive care unit. Surg Endosc 2007; 21:681-3.
11. Fong DG, Ryou M, Pai RD, et al. Transcolonic hepatic wedge resection in a porcine model. Gastrointest Endosc 2006; 63:102 (abstract).
12. Giday SA, Kantsevoy SV, Kalloo AN. Principle and history of Natural Orifice Transluminal Endoscopic Surgery (NOTES). Minim Invasive Ther Allied Technol 2006; 15:373-7.
13. Hu B, Chung SC, Sun LC, et al. Endoscopic suturing without extracorporeal knots: a laboratory study. Gastrointest Endosc 2005; 62:230-3.
14. Chadalavada R, Lin E, Swafford V, Sedghi S, Smith CD. Comparative results of endoluminal gastroplasty and laparoscopic antireflux surgery for the treatment of GERD. Surg Endosc 2004; 18:261-5.
15. Hu B, Chung SC, Sun LC, et al. Transoral obesity surgery: endoluminal gastroplasty with an endoscopic suture device. Endoscopy 2005; 37:411.
16. Andrew S, Gavin W. Hand-assisted laparoscopic lymphadenectomy: a novel approach to a difficult area. ANZ J Surg 2003; 73:755-7.
17. Giulianotti PC, Coratti A, Angelini M, et al. Robotics in general surgery. Personal experience in a large community hospital. Arch Surg 2003; 138:777-84.
18. Sylla P, Kirman I, Whelan RL. Immunological advantages of advanced laparoscopy. Surg Clin North Am 2005; 85:1-18.
19. Litynski GS. Endoscopic surgery: the history, the pioneers. World J Surg 1999; 23:745-53.
20. Litynski GS. Eric Muhe and the rejection of laparoscopic cholecystectomy (1985): a surgeon ahead of his time. J Soc Laparoendosc Surg 1998; 2:341-6.
21. Swanstrom LL. [Current technology development for natural orifice transluminal endoscopic surgery]. Cir Esp 2006; 80:283-8. Spanish.
22. Bardaro SJ, Swanstrom L. Development of advanced endoscopes for Natural Orifice Transluminal Endoscopic Surgery (NOTES). Minim Invasive Ther Allied Technol 2006; 15:378-83.
23. Wagh MS, Thompson CC. Surgery insight: natural orifice transluminal endoscopic surgery - an analysis of work to date. Nature Clinical Practice Gastroenterol Hepatol 2007; 4:386-92.
24. Valdivieso E, Saenz R, Claudio N. Natural orifice transluminal endoscopic surgery: putting together minimally invasive techniques for a new era. Gastrointest Endosc 2007; 66:340-2.