

Perforation peritonitis due to gastrointestinal cryptococcosis as an initial presentation in an AIDS patient

Saha S, Agarwal N, Srivastava A, Kumar A

ABSTRACT

A 30-year-old woman underwent exploratory laparotomy for perforation peritonitis. Primary repair of the jejunal perforation was performed. The ulcer edge biopsy revealed *Cryptococcus*. Subsequently ELISA was reactive for HIV-1 antibody. This report describes a rare case of cryptococcal jejunal perforation, which was the initial presentation in an AIDS patient.

Keywords: acquired immunodeficiency syndrome, cryptococcus, gastrointestinal cryptococcus, jejunal perforation

Singapore Med J 2008; 49(11):e305-e307

INTRODUCTION

Abdominal complaints are frequent manifestations in acquired immunodeficiency syndrome (AIDS) patients, though the need for operative intervention is infrequent. Many pathogens have been implicated in causing hollow viscus perforation in these patients. We present a rare case of jejunal perforation caused by cryptococcal infection in a young woman.

CASE REPORT

A 30-year-old married woman, a resident of north-central India, presented to the emergency department of our hospital with complaints of abdominal pain and distension for four days and vomiting for one day. The pain was moderate in intensity and periumbilical in location in the initial two days, but became continuous and generalised subsequently. The vomiting was bilious in nature. Abdominal distension was progressive, but not associated with constipation or obstipation. There was no previous history of abdominal pain or systemic complaints like fever or fatigue. On examination, she was febrile, tachypnoeic, and had tachycardia. Pulse rate was 120/min, blood pressure was 100/60 mmHg, and temperature was 39°C. On abdominal examination, abdomen was distended and the lower abdomen was tender along with guarding. There was no organomegaly or ascites and bowel sounds were sluggish.

Baseline investigation revealed Hb 9.2 gm/dL, TLC 5,600/mm³, Urea 98 mg/dL, Na-145 meqL⁻¹, K-

4.6 meqL⁻¹. Chest radiograph showed no gas under the diaphragm. Ultrasonography of the abdomen revealed free intraperitoneal fluid with debris, suggestive of infected fluid. With a suspicion of perforation peritonitis, contrast-enhanced computed tomography (CT) of the abdomen showed fluid in the peritoneal cavity along with free air, which confirmed the diagnosis of perforation peritonitis.

The patient underwent emergency exploratory laparotomy. At laparotomy, there was 1 L of biliopurulent fluid in the peritoneal cavity. A single perforation, 0.5 cm in diameter, was seen on the antimesenteric jejunal border, 36 cm from the ligament of Treitz. Lavage of the peritoneal cavity was done with warm saline, and biopsy was taken from the edge of the perforation. The perforation was repaired in a single layer with interrupted 3-0 polyglactin (vicryl) sutures, since it was small in size with healthy surrounding serosa. Abdominal drain was placed in the pelvic cavity. Parenteral antibiotics (ceftriaxone and metronidazole) were given in the perioperative period. Postoperative period was uneventful and the patient was allowed oral feeding on the third day. Histological examination of the specimen revealed *Cryptococcus* infection. Haematoxylin and eosin stain showed round and oval defects contain faintly basophilic organisms suggestive of *Cryptococcus* (Fig. 1). Confirmation was done by staining with Alcian blue, mucicarmine and Gomori methenamine silver stains, which revealed encapsulated yeast cells (Fig. 2).

Because of detection of an opportunistic pathogen on biopsy, ELISA test for HIV-1 and HIV-2 was done, after proper counselling. Serological tests showed a positive ELISA test for HIV-1 antibody. CD4 count was 200 cells mm⁻³. The patient was started on a three-drug antiretroviral therapy (ART) with lamivudine, stavudine and nevirapine. These are the drugs currently available in India under the National AIDS Control Organisation distribution centres. Amphotericin B infusion was administered for two weeks from the fifth postoperative day after which she was started on oral fluconazole for gastrointestinal cryptococcosis. The patient had no evidence of ocular or pulmonary cryptococcal infection. CD4 count after six months was 574 cells mm⁻³. She tolerated the ART well and did not suffer any new

Department of
Surgical Disciplines,
All India Institute of
Medical Sciences,
Ansari Nagar,
Delhi 110029,
India

Saha S, MBBS, MS
Senior Resident

Agarwal N, MBBS,
MS
Senior Resident

Srivastava A, MBBS,
MS, PhD
Professor

Kumar A, MBBS
Junior Resident

Correspondence to:
Dr Nitin Agarwal
Tel: (91) 11 2435 6446
Fax: (91) 11 2435 9445
Email: dmitinagarwal76@gmail.com

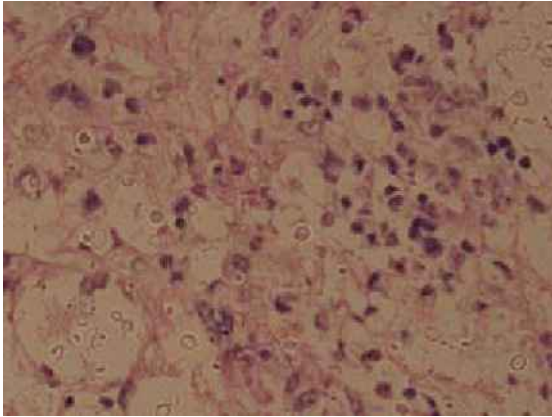


Fig. 1 Photomicrograph of the ulcer edge biopsy shows round and oval defects which contain faintly basophilic organisms that vary in size. Organisms tend to marginate at the periphery of the defects. A mixed infiltrate with pale staining organisms is seen. Individual organisms are separated from the neighbouring inflammatory cells by symmetrically rounded clear spaces (Haematoxylin & eosin, $\times 400$).

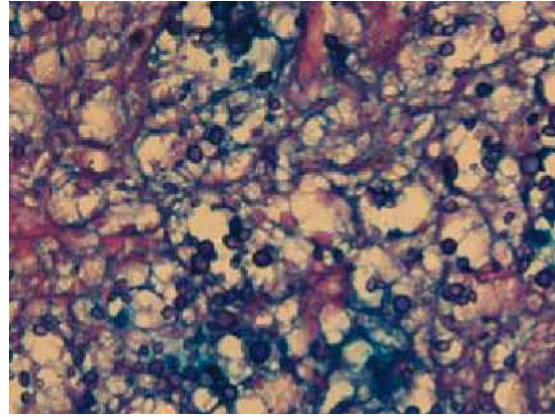


Fig. 2 Photomicrograph of the same specimen using a different stain to confirm *Cryptococcus* infection. The cell wall and capsule appear in contrasting colour, as Alcian blue stains the capsule (Alcian blue-Periodic acid-Schiff, $\times 400$).

opportunistic infection at seven months after treatment. The spouse also tested positive for the retrovirus and underwent treatment.

DISCUSSION

Secondary peritonitis is a common surgical emergency in India. The prevalence of HIV infection is also rising rapidly, with an estimated 5.21 million people infected with the virus in our country.⁽¹⁾ Gastrointestinal symptoms are very common in patients with AIDS. However, these are mainly chronic symptoms, like diarrhoea, abdominal pain, jaundice and gastrointestinal bleeding. The incidence of acute abdomen in AIDS is less common. This is mainly because the abdominal catastrophe occurs often as a sequel of the chronic gastrointestinal symptoms, and manifests with more subtle signs due to immunosuppression. Fever and raised counts are less frequently seen.⁽²⁾ It has also been shown that only 2%–5% of abdominal complaints in AIDS patients warrant surgical intervention.^(3–5) Due to these reasons, diagnosis and treatment are often delayed, with poor outcomes. In our patient, the diagnosis was established after 24 hours of admission due to equivocal signs of peritonitis.

Most opportunistic infections in AIDS are seen after the CD4 count drops below 200 cells mm^{-3} . Cytomegalovirus (CMV) is the most common virus implicated in the gastrointestinal tract. Primary infection is asymptomatic, but reactivation occurs when the CD4 counts drop below 100 cells mm^{-3} . The colon is commonly involved, and manifestations are bleeding, diarrhoea or perforation.⁽⁶⁾ Primary CMV peritonitis has also been reported.⁽⁷⁾ Mycobacterial infections of the gastrointestinal tract are also frequently observed in

AIDS patients. In developing countries, co-infection with *Mycobacterium tuberculosis* is seen in more than 40% of the cases.⁽⁶⁾ Atypical mycobacteria have been reported in 10%–15% of patients.⁽⁸⁾ Mycobacterial infections usually present with diarrhoea and abdominal pain. Involvement of the ileocaecal region is predominant, as with immunocompetent patients. They are seen earlier in the disease, at CD4 counts of around 400 cells mm^{-3} . The diagnosis is established by CT and identification of acid-fast bacilli in the specimens.

Cryptosporidium and microsporidia are important pathogens in AIDS and are more common in developing countries. Presentation is often with abdominal pain and diarrhoea. Perforation of the intestine is rare. Among the fungal infections of the gastrointestinal tract, *Candida* is the most common pathogen, and infection with this organism is usually oral or oesophageal. Necrotising candidial enterocolitis can cause perforation. Histoplasmosis of the colon has also been reported, which causes mainly diarrhoeal disease. Treatment is with amphotericin B infusion followed by oral fluconazole.⁽⁹⁾

Cryptococcal infection in AIDS is considered as a disease-defining illness, usually seen at CD4 counts of less than 200 cells mm^{-3} . The usual manifestations are pulmonary, but meningitis, septicaemia and ocular manifestations have also been reported. Meningoencephalitis is the most frequent manifestation of cryptococcosis in HIV-infected individuals. Review of literature could identify only a few reports of gastrointestinal involvement with *Cryptococcus*.^(10–13) Of these, one case has been reported in an immunocompetent host.⁽¹⁰⁾ Chalsani et al reported three cases with gastroduodenal involvement, with endoscopic documentation. The lesions were nodular, plaque-like, or ulcers.⁽¹²⁾ In two patients, gastroduodenal

cryptococcosis was the initial clinical manifestation of disseminated cryptococcosis.^(11,13) Thus gastrointestinal tract cryptococcal infection may manifest as asymptomatic or mildly symptomatic lesions, and could be a marker for disseminated cryptococcosis.

It is also interesting that *Cryptococcus* has been commonly seen in patients of liver failure with peritonitis, and infected ascites. Gastrointestinal involvement with *Cryptococcus* in these cases have poorer outcomes.⁽¹⁴⁻¹⁶⁾ One of these patients had coexistent AIDS. While cirrhosis is an immunosuppressive state, it is surprising that only a handful of cases of AIDS have been shown to have gastrointestinal involvement with *Cryptococcus*. In our patient, the presence of this organism in the jejunal perforation edge, and also the diagnosis of AIDS which was established after this event, were the unexpected features. Testing for the retrovirus in all cases of peritonitis is still not routine in our country. In conclusion, gastrointestinal cryptococcal infection is one of the causes of the intestinal perforation in the AIDS patient. This case highlights the importance of taking the edge biopsy of the perforated ulcer for the histopathological evaluation.

REFERENCES

1. National AIDS Control Organization. HIV/AIDS Epidemiological Surveillance and Estimation Report for the Year 2005. National AIDS Control Organization, Ministry of Health & Family Welfare Government of India; 2006 April.
2. Truskett PG. HIV infection in surgical practice. *Med J Aust* 1993; 158:264-5.
3. Whitney TM, Brunel W, Russell TR, Bossart KJ, Schechter WP. Emergent abdominal surgery in AIDS: experience in San Francisco. *Am J Surg* 1994; 168: 239-43.
4. LaRaja RD, Rothenberg RE, Odom JW, Mueller SC. The incidence of intra-abdominal surgery in acquired immunodeficiency syndrome: a statistical review of 904 patients. *Surgery* 1989; 105:175-9.
5. Ferguson CM. Surgical complications of human immunodeficiency virus infection. *Am Surg* 1988; 54:4-9.
6. Shiekh RA, Yasmeen S, Prindville TP, Reubner BH. Intestinal perforation and peritonitis in AIDS: case series and review of the literature. *JK Practitioner* 2004; 11:248-56.
7. Wilcox CM, Forsmark CE, Darragh TM, Benedict Yen TS, Cello JP. Cytomegalovirus peritonitis in a patient with the acquired immunodeficiency syndrome. *Dig Dis Sci* 1992; 37:1288-91.
8. Chin DP, Hopewell PC, Yajko DM, et al. Mycobacterium avium complex in the respiratory or gastrointestinal tract and the risk of M. avium complex bacteremia in patients with human immunodeficiency virus infection. *J Infect Dis* 1994; 169:289-95.
9. Salvaggio MR, Pappas PG. Current concepts in the management of fungal peritonitis. *Curr Infect Dis Rep* 2003; 5:20-4.
10. Chaitowitz M, Shaw ML, Mokoena TR. Gastrointestinal cryptococcosis presenting as spontaneous jejunal perforation in a nonimmunocompromised host. *Dig Dis Sci* 2003; 48:1196-9.
11. Washington K, Gottfried MR, Wilson ML. Gastrointestinal cryptococcosis. *Mod Pathol* 1991; 4:707-11.
12. Chalsani N, Wilson CM, Hunter HT, Schwartz DA. Endoscopic features of gastroduodenal cryptococcosis in AIDS. *Gastrointest Endosc* 1997; 45:315-7.
13. Bonacini M, Nussbaum J, Ahluwalia C. Gastrointestinal, hepatic, and pancreatic involvement with *Cryptococcus neoformans* in AIDS. *J Clin Gastroenterol* 1990; 12:295-7.
14. Franca AV, Carneiro M, dal Sasso K, Souza Cda S, Martinelli A. Cryptococcosis in cirrhotic patients. *Mycoses* 2005; 48:68-72.
15. Stiefel P, Pamies E, Miranda ML, et al. Cryptococcal peritonitis; report of a case and review of literature. *Hepatogastroenterology* 1999; 46:1618-22.
16. Singh N, Husain S, De Vera M, Gayowski T, Cacciarelli TV. *Cryptococcus neoformans* infection in patients with cirrhosis, including liver transplant candidates. *Medicine (Baltimore)* 2004; 83:188-92.