

Melaena: an unusual presentation of a pseudoaneurysm of the internal carotid artery

Tan V K M, Tan H H, Ong Y K, Tan S G

ABSTRACT

Pseudoaneurysm of the internal carotid artery is a rare but potentially fatal condition, and its clinical manifestations are often varied. Knowledge of this condition is essential to making the diagnosis. We describe a case of a 38-year-old man who presented with melaena. He also reported blood-stained sputum in the morning for several days. The only significant physical finding was a left peritonsillar mass. Initially worked up for a gastrointestinal bleed, computed tomography of the neck showed a large pseudoaneurysm of the internal carotid artery. A bypass from the proximal external carotid artery to the distal middle cerebral artery had to be created prior to angiographic embolisation of the pseudoaneurysm due to an inadequate supply from the contralateral cerebral hemisphere. The patient made an uneventful recovery with no neurological deficits.

Keywords: endovascular embolisation, extracranial-intracranial bypass, internal carotid artery, melaena, pseudoaneurysm

Singapore Med J 2008; 49(11):e296-e299

INTRODUCTION

Pseudoaneurysm of the internal carotid artery (ICA) is a rare but potentially fatal condition. Definitive treatment requires securing the aneurysm – either surgically or endovascularly. Occlusion of one carotid artery has its obvious attendant risk of cerebral ischaemia caused by hypoperfusion, resulting in acute neurological compromise or death. Pre-occlusion analysis of the adequacy of a patient's collateral circulation should be performed. Patients with poor collateral circulation are at high risk of cerebral ischaemia unless an extracranial-intracranial bypass is performed prior to the permanent ICA occlusion.

CASE REPORT

An otherwise healthy 38-year-old man presented with melaena for six days. He also had small amounts of blood-stained sputum. He had not experienced any soreness in his throat. He had no other respiratory or

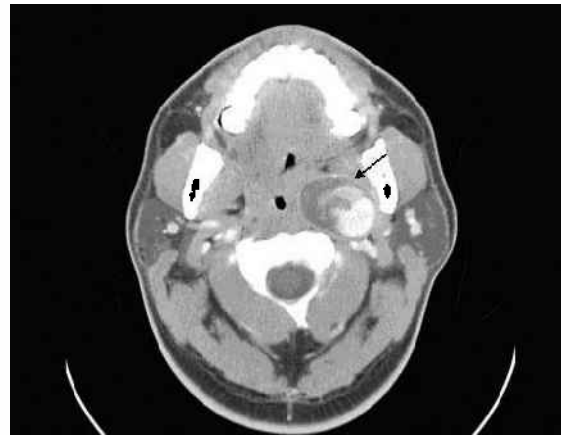


Fig. 1 Axial CT image shows a large, left ICA pseudoaneurysm with a thick non-opacified sac into which the contrast is leaking (arrow). The oropharynx is seen to be narrowed on the left.

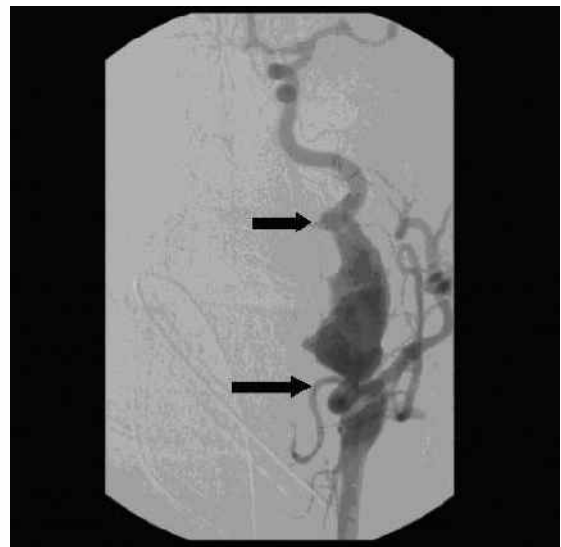


Fig. 2 Digital subtraction arteriogram shows a large, tortuous left ICA pseudoaneurysm (arrows delineate the extent of the aneurysm).

abdominal symptoms. He is a non-smoker and had a tonsillectomy 20 years ago. At presentation, the patient was afebrile. He was noted to be tachycardic at 124 beats per minute. His blood pressure was stable at 160/114 mmHg. Examination of the respiratory system was unremarkable. No neurological deficits were noted. Oral examination revealed a left peritonsillar swelling with no obvious source of bleeding. There was no palpable mass on abdominal examination. Digital rectal examination revealed stale melaena.

Department of
General Surgery,
Singapore General
Hospital,
Outram Road,
Singapore 169608

Tan VKM, MBBS,
MRCS
Medical Officer

Tan SG, FRCS
Senior Consultant and
Vascular Surgeon

Department of
Gastroenterology

Tan HH, MBBS,
MRCP
Associate Consultant

Department of
Otolaryngology,
5 Lower Kent Ridge
Road,
Singapore 119074

Ong YK, MBBS,
MMed, MRCS
Associate Consultant

Correspondence to:
Dr Veronique KM Tan
Tel: (65) 6321 4051
Fax: (65) 6220 9323
Email: vquetan@
gmail.com

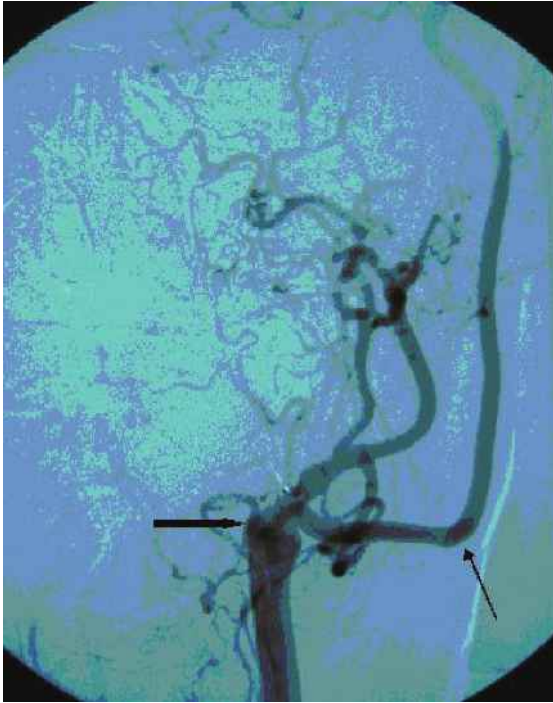


Fig. 3 Digital subtraction arteriogram done postembolisation shows the complete occlusion of the ICA pseudoaneurysm (thick arrow). Good flow is demonstrated in the saphenous vein bypass (thin arrow) from the proximal ECA to the distal MCA (not shown).

A nasoendoscopy was performed to exclude a lesion in the upper aerodigestive tract which might account for blood in the oral cavity. The only abnormality in the upper airway was a left peritonsillar mass. There was no visible source of bleeding. A fine-needle aspirate of this lesion yielded blood. Haemostasis was secured post fine-needle sampling. Initial investigations showed a haemoglobin concentration of 13.3 g/dL. The chest radiograph was normal. Investigations then focused on the gastrointestinal tract to identify the cause for his presentation of melaena. The patient underwent oesophagogastroduodenoscopy, which revealed mild oesophagitis and antral gastritis only. He was started on intravenous omeprazole but continued to have melaena and episodes of blood-stained sputum while in the ward. Serial serum haemoglobin recorded a nadir of 10.6 g/dL.

In view of the persistence of bloodstains in the patient's sputum each morning and a dropping haemoglobin count, a repeat otolaryngology opinion was sought. Again, the only positive finding was a left peritonsillar mass noted on oral examination. With the history of recurrent oropharyngeal bleed and the finding of a peritonsillar mass, computed tomography (CT) of the neck was performed to assess the parapharyngeal space. This revealed a large aneurysmal sac occupying the left parapharyngeal space which appeared to arise

from the end of the left common carotid (Fig. 1). The pseudoaneurysm had a thick, non-opacified sac that appeared to be chronic and longstanding. No surrounding stranding or signs of inflammation were noted radiologically. Clinically, the patient remained afebrile and did not experience any soreness of the throat. Aerobic and anaerobic blood cultures and smears for acid-fast bacilli were negative.

An urgent cerebral angiogram showed a large left ICA aneurysm spanning almost the entire cervical ICA, from above the bifurcation to the petrous ICA (Fig. 2). Cross-circulation at the skull base was not demonstrated during the carotid angiogram, as contralateral manual occlusion was not performed in view of the large aneurysm on the left side of the neck. Urgent exclusion of the pseudoaneurysm was needed. In view of the lack of identifiable skull base arterial branches serving as collateral conduits, the patient was assessed to be unable to tolerate permanent left ICA occlusion. An extracranial-intracranial bypass from the proximal external carotid artery to the distal middle cerebral artery using an autologous saphenous vein graft was created prior to endovascular embolisation. Endovascular embolisation to exclude the pseudoaneurysm was then performed via bilateral femoral arterial punctures. The left carotid angiogram showed the large left internal carotid pseudoaneurysm and demonstrated flow in the vascular graft. A detachable balloon system was then loaded into the left ICA and the balloon guided into the precavernous segment of the left ICA. It was inflated and detached in this position. A second balloon was deployed just distal to the origin of the proximal left ICA. A third balloon was detached at the origin of the left ICA to complete occlusion.

No neurological deficits were noted post-intervention. Follow-up computed CT angiogram done three days later showed complete exclusion of the abnormal left ICA segment and good flow through the newly-created bypass (Fig.3). The patient had no further oral bleeding and had an uneventful recovery.

DISCUSSION

A pseudoaneurysm is an extravascular haematoma that communicates with the intravascular space. The vascular wall has been breached, and the external wall of the aneurysmal sac consists only of the outer arterial layer, perivascular tissues or blood clot.⁽¹⁾ Pseudoaneurysms of the cervical ICA are rare. They may occur as a sequelae to parapharyngeal or retropharyngeal sepsis, presumably due to an arterial wall weakened by arteritis due to the adjacent septic foci. Other causes include gunshot or stab injuries, blunt head trauma, and iatrogenic causes such as needle puncture, arterial grafting and tonsillectomy.^(2,3)

Clinical manifestations of an ICA pseudoaneurysm are varied. Knowledge of this condition is essential to making this diagnosis.⁽³⁾ Signs of a pseudoaneurysm include an enlarging, pulsatile lateral neck mass, a medially bulging pharyngeal wall or detection of a thrill or bruit.⁽⁴⁾ A pseudoaneurysm may also declare itself by causing mass effect on surrounding structures. Ipsilateral lower cranial nerve palsies or Horner's syndrome may result from a pseudoaneurysm's compressive effects on the lower four cranial nerves or sympathetic chain, which share the parapharyngeal space.^(3,5,6) Recurrent undiagnosed haemorrhages from the oropharynx, ear or nose, or a purplish discolouration of the skin or oral mucosa are often signs of a sentinel event.⁽⁴⁾ Carotid blow-out syndrome is always a possible first manifestation of a carotid pseudoaneurysm.⁽²⁾

The high morbidity and mortality rates associated with pseudoaneurysms of the ICA demand prompt diagnosis – both to institute appropriate definitive treatment and to avoid them being sampled with obvious potential devastating consequences.⁽⁴⁾ In our case, a fine-needle aspirate was performed which fortuitously did not result in any morbidity. It also did not contribute to the diagnosis. In retrospect, given the clinical finding of a peritonsillar mass and the history of recurrent oropharyngeal bleed, imaging of the parapharyngeal space should initially have been performed to exclude a vascular lesion. Until a pseudoaneurysm of the ICA is conclusively excluded by imaging methods, no biopsy nor incision and drainage of any parapharyngeal lesion should be performed.

The diagnosis of a cervical carotid artery pseudoaneurysm may be established using Doppler ultrasonography or imaging modalities, such as contrast-enhanced CT or magnetic resonance imaging. The definitive diagnostic test is cervical angiography.^(2,4) Following the diagnosis of a pseudoaneurysm, urgent institution of treatment is often necessary as the risk of a carotid blow-out is ever present. Sentinel bleed with intermittent haemorrhage usually portend rupture, and the typical spontaneous cessation of such haemorrhagic episodes belie the gravity of this finding.⁽⁴⁾

Patients with pseudoaneurysms of the ICA often require planned or emergency sacrifice of the carotid artery. Traditionally, surgical ligation of the extracranial ICA to exclude the aneurysmal segment is the definitive treatment of extracranial ICA pseudoaneurysms.^(4,5) However, with the advancement of neurointervention therapy, carotid occlusion may be achieved using endovascular technique.^(2,6) Trapping of the pseudoaneurysm is accomplished by placing coils or detachable balloons distal then proximal to the vessel defect, effectively blocking both retrograde

and antegrade blood flow. As in our patient with a pseudoaneurysm extending to the base of the skull, such endovascular occlusion allow for securing distal control without the need for complex and dangerous surgery.

Occlusion of one carotid artery has its obvious attendant risk of cerebral ischaemia caused by hypoperfusion, resulting in acute neurological compromise or death. Pre-occlusion analysis of the adequacy of a patient's collateral circulation should be performed.⁽⁷⁾ Angiographically identifiable arterial branches may be revealed by manoeuvres, such as external manual ICA compression or temporary intraoperative occlusion of the ICA. As with the case presented, such manoeuvres may not be feasible as external compression of a large pseudoaneurysm is wisely avoided. The technique of temporary ICA occlusion through intravascular balloon inflation in conjunction with cerebral angiography has proven to be an effective method to evaluate structural and functional haemodynamic support to the ipsilateral cerebral hemisphere prior to permanent carotid artery sacrifice.⁽⁷⁾ Functional assessment is done by clinical neurological examination with or without adjunctive electroencephalographical monitoring, while the carotid artery is temporarily occluded with an inflated intravascular balloon. Patients who do not respond well to temporary occlusions are considered to be at high risk of cerebral ischaemia unless an extracranial-intracranial bypass is performed prior to the permanent ICA occlusion.

Pseudoaneurysm of the extracranial ICA is rare. It may present in a myriad of ways and the diagnosis must be borne in mind. In our patient, the unusual presentation with melaena led us to assess the gastrointestinal tract for a bleeding source. A high index of suspicion is needed especially in a patient who presents with a unilateral pulsatile oropharyngeal or neck mass. Pseudoaneurysms need to be diagnosed in order to avoid potentially dangerous investigational procedures and also for urgent definitive treatment. Definitive management involves sacrifice of the ICA as the aneurysmal segment needs to be excluded. This may be done surgically or endovascularly. Prior to occlusion of the carotid artery, analysis of the adequacy of ipsilateral cerebral perfusion by collaterals should be done. If collateral supply is deemed inadequate, creation of an extracranial-intracranial vascular bypass should be performed prior to sacrifice of the ICA.

ACKNOWLEDGEMENT

We would like to thank Dr Francis Hui for his help and for the angiograms.

REFERENCES

1. Cotran RS, Kumar V, Collins T. Blood vessels. In: Robbins Pathologic Basis of Disease. 6th ed. Philadelphia: WB Saunders, 1999: 524.
2. Pearson SE, Choi SS. Pseudoaneurysm of the internal carotid artery: a case report and review of the literature. Arch Otolaryngol Head Neck Surg 2005; 131:454-6.
3. Watson MG, Robertson AS, Colquhoun IR. Pseudoaneurysm of the internal carotid artery: a forgotten complication of tonsillitis? J Laryngol Otol 1991; 105:588-90.
4. Reisner A, Marshall GS, Bryant K, Postel GC, Eberly SM. Endovascular occlusion of a carotid pseudoaneurysm complicating deep neck space infection in a child. Case report. J Neurosurg 1999; 91:510-4.
5. Glaiberman CB, Towbin RB, Boal DKB. Giant mycotic aneurysm of the internal carotid artery in a child: endovascular treatment. Paediatr Radiol 2003; 33:211-5.
6. Semple CW, Berkowitz RG, Mitchell PJ. Embolization of an extracranial internal carotid artery pseudoaneurysm. Ann Otol Rhinol Laryngol 2005; 114:90-4.
7. Allen JW, Alastra AJG, Nelson PK. Proximal intracranial internal carotid artery branches: prevalence and importance for balloon occlusion test. J Neurosurg 2005; 102:45-52.