

Angioinvasive pulmonary mucormycosis presenting as multiple bilateral pulmonary nodules in a patient without obvious predisposing factors

Sharma A, Gupta V, Singh R S, Kakkar N, Singh S, Bambery P

ABSTRACT:

Pulmonary mucormycosis is a rare, frequently fatal, fungal infection. It is usually seen in the presence of various immunocompromised states, such as diabetes mellitus, haematological malignancy or renal transplantation. In the absence of underlying predisposing conditions, presentation with infiltrates, consolidation, cavitation and mass lesion have been reported. We describe a 50-year-old man who presented with cough and chest pain for six months. Chest radiograph and computed tomography showed bilateral multiple pulmonary nodules. Surgical lung biopsy revealed angioinvasive mucormycosis. He had complete recovery with amphotericin therapy.

Keywords: angioinvasive pulmonary mucormycosis, fungal infection, pulmonary mucormycosis, pulmonary nodules

Singapore Med J 2008; 49(10): e269-e271

INTRODUCTION

Mucormycosis and zygomycosis are general terms for infections caused by various fungi, such as *Rhizopus*, *Rhizomucor*, *Mucor* and *Cunninghamella*.⁽¹⁾ Mucormycosis is a life-threatening fungal infection that occurs primarily in patients with various immunocompromised states, such as diabetes mellitus, haematological malignancies, post-renal transplant patients and stem cell transplant patients.⁽²⁾ Rarely, these infections occur in patients without any underlying immunocompromised state. We describe one such patient who had no obvious predisposing condition, and had complete recovery with amphotericin therapy.

CASE REPORT

A 50-year-old male farmer, a chronic smoker, presented with a dry cough and left-sided chest pain for six months. There was no history of a recent traffic accident or significant travel history. On examination, all systems were normal, but he was thinly built (body mass index of 18 kg/m²). The various investigations

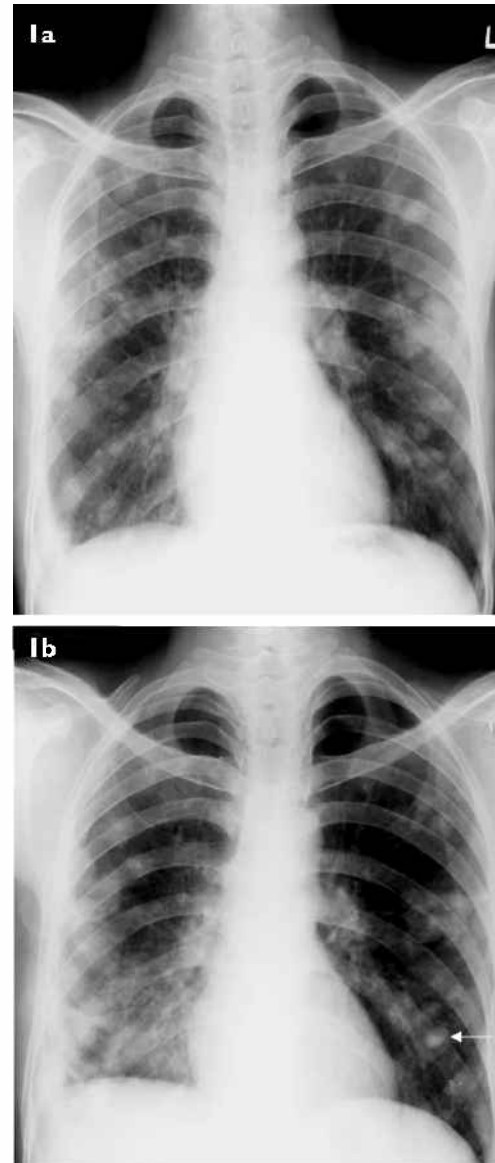


Fig. 1 Chest radiograph (posteroanterior view) taken (a) pre-treatment shows multiple well-defined nodules distributed randomly in bilateral lung fields. (b) Post-treatment radiograph shows a decrease in number of nodules and appearance of calcification (arrow).

are summarised in Table 1. Investigations revealed mild anaemia. Chest radiograph showed bilateral nodular opacities (Fig. 1a). Contrast-enhanced computed tomography (CECT) showed multiple

Department of Internal Medicine,
Post Graduate Institute of Medical Education and Research,
Chandigarh 160012, India

Sharma A, MD
Assistant Professor

Singh S, MD
Professor

Bambery P, MD, FRCP
Professor

Department of Radiodiagnosis

Gupta V, MD
Assistant Professor

Department of Cardiovascular and Thoracic Surgery

Singh RS, MCh
Additional Professor

Department of Histopathology

Kakkar N, MD
Associate Professor

Correspondence to:
Dr Aman Sharma
Tel : (91) 172 275 6681
Fax: (91) 172 274 4401
Email: amansharma74@yahoo.com

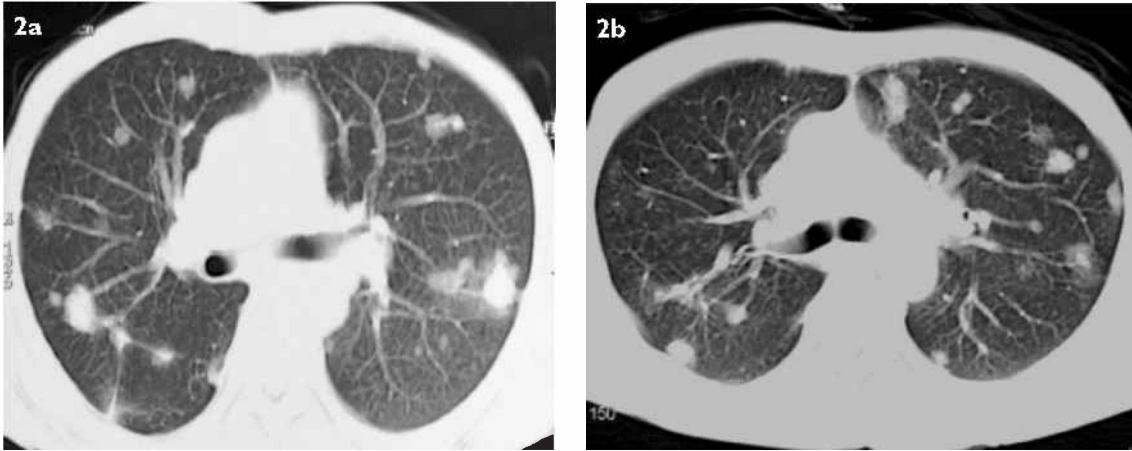


Fig. 2 Axial CECT images taken at the subcarinal level. (a) Pre-treatment image shows multiple rounded nodules in both lung fields. (b) Post-treatment image shows a decrease in the number and size of the nodules (especially in the right lung).

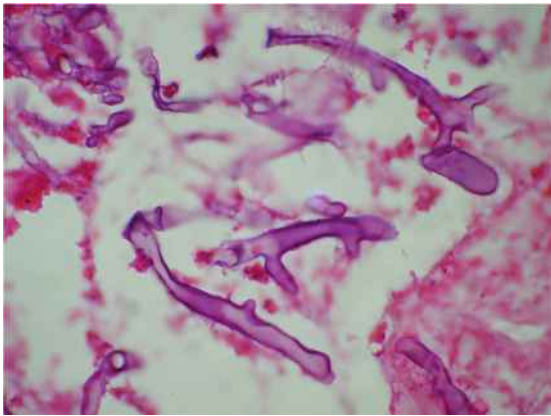


Fig. 3 Open lung biopsy shows aseptate, broad fungal hyphae with right angle branching, suggestive of mucormycosis (Periodic acid schiff stain, $\times 100$).

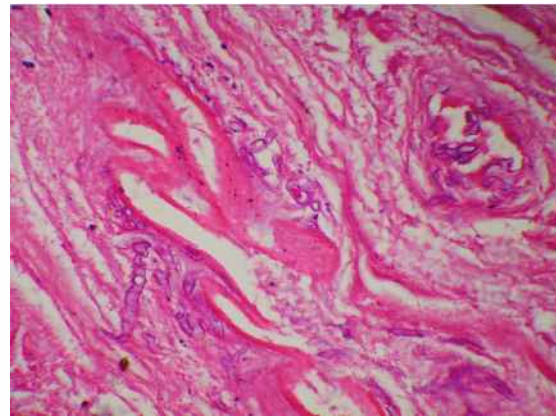


Fig. 4 Photomicrograph from the open lung biopsy shows fungal vasoinvasion (Haematoxylin & eosin, $\times 40$).

well-defined nodules scattered in both lung fields (Fig. 2a). A few of these lesions showed the “feeding vessel sign,” suggestive of angioinvasion. Nitroblue tetrazolium, antinuclear antibodies, anti-nuclear cytoplasmic antibodies and human immunodeficiency virus serology were negative. Barium meal and follow-through, ultrasonography of the abdomen/testes and CECT of the abdomen done to exclude abdominal malignancy were normal. Radiographs of the paranasal sinuses showed evidence of bilateral frontal and left maxillary sinusitis.

As CT-guided aspiration was non-contributory, a surgical lung biopsy was done. This showed infiltration by aseptate, broad fungal hyphae with right-angle branching suggestive of mucormycosis (Fig. 3). Few sections showed angioinvasion by the fungus (Fig. 4). As the nodules were diffusely distributed bilaterally, surgical resection was not possible; he was therefore given amphotericin in a total cumulative dose of 1.5 g. Repeat chest radiograph (Fig. 1b) and CECT (Fig. 2b) done after eight weeks showed resolution of smaller nodules and calcification of larger nodules. After 18

months of follow-up, the patient had gained weight and was totally asymptomatic.

DISCUSSION

Zygomycosis is an uncommon fungal infection reported mostly from patients with some other predisposing illness. Various groups of clinical infections reported are rhinocerebral, pulmonary, cutaneous, gastrointestinal, isolated renal and disseminated.⁽²⁾ Roden et al reviewed all cases of histologically- or culture-proven cases of zygomycosis in the English literature published from 1885.⁽³⁾ They reported 929 patients, of whom 224 patients had pulmonary mucormycosis. Only 14 patients (6.25%) did not have any underlying risk factor. An increasing trend of zygomycosis has also been reported from India.⁽⁴⁾ Out of the 178 cases of zygomycosis reported from our institute, 12 had pulmonary mucormycosis and all of them had an underlying disease in the form of diabetes mellitus (9), renal transplant (1), steroid therapy (1) and concomitant tuberculosis (1).

Among patients with pulmonary zygomycosis

Table I. Various laboratory parameters at the time of admission.

Laboratory parameters	Values
Haemoglobin (g/dL)	9.4
Total leucocyte count (/ μ L)	6,000
Erythrocyte sedimentation rate (mm/1st hr)	60
Platelet count (/ μ L)	264,000
Peripheral blood film	Mild anisocytosis, microcytosis, hypochromia
Fasting blood sugar (mg/dL)	80
Postprandial sugar (mg/dL)	90
Serum albumin (g/dL)	3.6
Blood urea (mg/dL)	25
Serum creatinine (mg/dL)	0.6
Serum alkaline phosphate (KAU)	7
ANA	Negative
ANCA	Negative
Stool for occult blood	Negative
HIV	Negative
HBs Ag	Negative

without an identifiable predisposing condition, bilateral consolidation,⁽⁵⁾ pleural-based mass,⁽⁶⁾ upper-lobe infiltrates with cavitation,⁽⁷⁾ solitary pulmonary nodule⁽⁸⁾ and hilar mass⁽⁹⁾ have all been described. To the best of our knowledge, multiple bilateral diffusely-scattered pulmonary nodules have not yet been reported. This presentation has been encountered in patients with an underlying predisposing condition.⁽¹⁰⁾ Disseminated fungal infection can mimic systemic necrotising vasculitis. Nodular pulmonary infiltrates are a common feature of Wegner's granulomatosis, and with this demonstration, its place in the differential diagnosis of Wegner's granulomatosis is strengthened. Radiographs of the paranasal sinuses in our patient showed evidence of bilateral frontal and left maxillary sinusitis. Consideration of Wegner's granulomatosis led to surgical lung biopsy in this patient.

Invasive zygomycosis has a high mortality rate in patients with immunocompromised states. The reported overall mortality is 80%; 65% in patients with isolated pulmonary mucormycosis and 96% in patients with disseminated disease.⁽²⁾ The treatment usually requires a combination of surgery in resectable lesions with antifungal agents like amphotericin, though treatment alone with amphotericin also works in special situations like in our patient. The total duration of therapy is not well defined, but usually a total cumulative dose of

1.5 g of amphotericin is enough in a selected group of patients who respond only to amphotericin therapy. The most common side effect seen with amphotericin therapy is nephrotoxicity. Liposomal amphotericin can be used in the presence of nephrotoxicity.

REFERENCES

1. Bigby TD, Serota ML, Tierney LM Jr, Matthey MA. Clinical spectrum of pulmonary mucormycosis. *Chest* 1986; 89:435-9.
2. Tedder M, Spratt JA, Anstadt MP, et al. Pulmonary mucormycosis: Results of medical and surgical therapy. *Ann Thorac Surg* 1994; 57:1044-50.
3. Roden MM, Zaoutis TE, Buchanan WL, et al. Epidemiology and outcome of zygomycosis: A review of 929 reported cases. *Clin Infect Dis* 2005; 41:634-53.
4. Chakrabarti A, Das A, Mandal J, et al. The rising trend of invasive zygomycosis in patients with uncontrolled diabetes mellitus. *Med Mycol* 2006; 44: 335-42.
5. De P, Ferrinho LGM. Pulmonary phycomycosis without obvious predisposing factors. *S Afr Med J* 1985; 68:893.
6. Zeilender S, Drenning D, Glauser FL, Bechar D. Fatal *Cunninghamella bertholletiae* infection in an immunocompetent patient. *Chest* 1990; 97:1482-3.
7. Record NB, Ginder DR. Pulmonary phycomycosis without obvious predisposing factors. *JAMA* 1976; 235:1256-7.
8. Matsushima T, Soejima R, Nakashima T. Solitary pulmonary nodule caused by phycomycosis in a patient without obvious predisposing factors. *Thorax* 1980; 35:877-8.
9. Majid AA, Yii NW. Granulomatous pulmonary zygomycosis in a patient without underlying illness. *Chest* 1991; 100:560-1.
10. McAdams HP, Christenson MR, Strollo DC, Patz EF. Pulmonary mucormycosis: Radiological findings in 32 cases. *Am J Roentgenol* 1997; 168:1541-8.