

Edwards syndrome with double trisomy

Tennakoon J, Kandasamy Y, Alcock G, Koh T H H G

ABSTRACT

Double trisomy is rare and the only case reported in the literature died soon after birth. We present another case of double trisomy (48XYY, +18) in a male neonate, who was born to a 28-year-old gravida three parity one mother at 35 weeks of gestation. The baby had features of trisomy 18. Karyotype of the patient showed 48, XYY, +18, Ish (DYZ3*2), (D18ZI*3), nuc ish (DYZ3*2), (D18ZI*3). The patient had clinical features of trisomy 18. There was no family history of diabetes mellitus and no exposure to chemicals. It has been suggested that the rarity of Y-chromosome involvement in trisomy 18 may be due to discrepancy between the sexes.

Keywords: double trisomy, Edwards syndrome, gonosomal trisomy, karyotype, trisomy 18

Singapore Med J 2008;49(7):e190-e191

INTRODUCTION

Double trisomy is rare, and the only known case reported in the literature died at 70 minutes of age. We present another case of double trisomy (48XYY, +18).

CASE REPORT

A male neonate was born to a 28-year-old gravida three parity one mother at 35 weeks of gestation by vaginal delivery. This pregnancy was uneventful. Her first pregnancy in 1997 was electively terminated in the first trimester. In 1999, her first baby was born at 38 weeks of gestation, and he is currently well. In this case, late antenatal ultrasonography done two days prior to delivery showed a small-for-gestational-age foetus with fairly normal foetal morphology. There was no abnormality noted, there was no mass/cyst, and nuchal fold thickness was normal. At birth, he had a good Apgar score and did not require resuscitation. He weighed 1,880 g (less than tenth percentile) and the head circumference was 32 cm (between tenth and 50th percentile). The patient had features of trisomy 18, which included low set ears, low hairline, small oral opening, and micrognathia, clenched hand with overlapping fingers, single palmar crease, clinodactyly, inguinal hernia, cardiac murmur and rocker bottom feet. No high arch palate was seen.

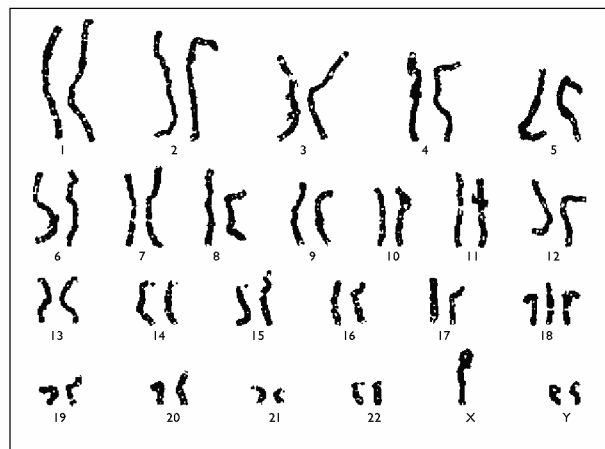


Fig. 1 Chromosome analysis shows trisomy 18 with double Y chromosome (48, XYY, +18).

Echocardiogram showed a small ventricular septal defect, an atrial septal defect and a small patent ductus arteriosus. Cranial ultrasonography showed bilateral grade two intraventricular haemorrhages. Chest radiograph showed cardiomegaly but there was no rib abnormality. He was treated for cardiac failure and received bubble continuous positive airway pressure for two weeks due to mild respiratory distress. Karyotype showed double trisomy 48, XYY, +18 (Fig. 1). The patient was discharged home on nasogastric feeds at six weeks of age, but passed away at four months of age.

DISCUSSION

The rate of double trisomy among aborted fetuses is about 2%.⁽¹⁾ Combined autosomal and gonosomal trisomies in patients with trisomy 18 have only been reported in one case.⁽²⁾ However, various other combinations of autosomal and gonosomal trisomies have been reported.⁽³⁾ Out of these, the more common presentations were trisomy 21 with XXY (29 cases) and trisomy 21 with XYY (16 cases).⁽²⁾ Gonosomal trisomies associated with trisomy 18 were XXY and XXX. It has been suggested that rareness involving the Y chromosome in trisomy 18 may be due to discrepancy between the sexes in the occurrence of trisomy 18. The female-to-male ratio is three to one.⁽³⁾

Presentation of trisomy 18 with XYY has been reported in only one case in medical literature, with the baby dying at birth.⁽²⁾ This patient had only a few

Neonatal Intensive
Care Unit,
The Townsville
Hospital,
Douglas,
QLD 4814,
Australia

Tennakoon J, MD
Registrar

Kandasamy Y,
FRACP
Consultant

Alcock G, FRACP
Consultant

Koh THHG, MD,
FRACP
Consultant

Correspondence to:
Dr Yoga Kandasamy
Tel: (61) 7 4796 2989
Fax: (61) 7 4796 2981
Email: yoga_
kandasamy@health.
qld.gov.au

clinical features of trisomy 18. Our patient presented far more clinical features of trisomy 18. Karyotype of the patient showed 48, XYY, +18, Ish (DYZ3*2), (D18Z1*3), nuc ish (DYZ3*2), (D18Z1*3). Both parents had normal chromosomal studies. The cause of double trisomy is unknown, although there is some evidence to show that maternal age-related mechanisms could be the underlying cause.⁽¹⁾

REFERENCES

1. Diego-Alvarez D, Ramos-Corrales C, Garcia-Hoyos M, et al. Double trisomy in spontaneous miscarriages: cytogenetic and molecular approach. *Hum Reprod* 2006; 21:958-66.
2. Felding I, Kristofferson U. A child with double trisomy: 48, XYY, +18. *Hereditas* 1981; 95:169-71.
3. Schwanitz G, Hagner M. Double trisomy as a mosaic. Case history (48, XYY, + 21/47,XY, +21) and survey of the literature of mixed autosomal-gonosomal trisomies. *Acta Genet Med Gemellol (Roma)* 1978; 27:67-74.