

Afibrinogenaemia: a rare cause of young myocardial infarct

Kumar N, Padma Kumar R, Ramesh B, Garg N

ABSTRACT

Afibrinogenaemia is a quantitative deficiency of fibrinogen that is associated with an increased bleeding tendency. Patients with afibrinogenaemia are at risk of excessive bleeding, but unusually, these patients may also experience thrombotic episodes. We report a 27-year-old man, with a known history of afibrinogenaemia, and who presented with acute onset of chest pain. Clinical examination was normal. Electrocardiogram revealed features suggestive of inferior and right ventricular myocardial infarction. This diagnosis was confirmed on echocardiogram, and by the elevated levels of cardiac enzymes troponin T and Creatinine kinase-MB. In view of the existing afibrinogenaemia, thrombolytics and anticoagulants were not given. He was managed with antiplatelets, nitrates, statins and angiotensin converting enzyme inhibitors. Young coronary artery disease risk factors (including thrombophilia) were otherwise normal. The patient tolerated dual antiplatelet therapy without any bleeding. The thrombotic episode occurring in tandem with the afibrinogenaemia, as have been observed in previous reports, is likely to be the cause for acute myocardial infarction in our patient.

Keywords: afibrinogenaemia, myocardial infarction

Singapore Med J 2008;49(4):e104-e106

INTRODUCTION

Afibrinogenaemia is a rare autosomal recessive disorder first described in 1920,⁽¹⁾ and is characterised by immeasurable and extremely low fibrinogen levels in plasma. Fibrinogen is a glycoprotein that circulates in plasma. It normally has a concentration of 24 g/L and a half-life of four days.⁽²⁾ It is synthesised primarily in hepatocytes and is secreted as a hexamer composed of three pairs of polypeptide chains.⁽³⁾ Bleeding, as well as thrombotic episodes, has been described in afibrinogenaemic patients. The most common presentation is excessive bleeding from the umbilical stump. 250 cases

of afibrinogenaemia have been reported in the world,⁽⁴⁾ but few case reports associated with myocardial infarction are known. In our case, a young man who was recently diagnosed with afibrinogenaemia, had acute inferior and right ventricular myocardial infarction.

CASE REPORT

A 27-year-old man, who was evaluated for excessive bleeding while brushing his teeth, was found to have afibrinogenaemia (Table I). Analytic tests revealed absent fibrinogen using the Clauss method, markedly reduced fibrinogen antigen level, normal platelet count and bleeding time, infinitely prolonged activated partial thromboplastin time, prothrombin time and thrombin time. He presented to us with chest pain of two hours duration. He was born out of a second-degree consanguineous marriage. Both parents and two younger brothers were asymptomatic; however, two younger sisters died within one week of birth. No details pertaining to the causes of death were available.

On admission, his pulse rate was 100/min and blood pressure was 160/100 mmHg. Cardiovascular examination revealed left ventricular S4. Electrocardiogram showed 2 mm ST segment elevation in leads II, III, aVF and V4r, and ST depression in leads I and aVL (Fig. 1), with first degree atrioventricular block. Echocardiogram revealed inferior and right ventricular free wall hypokinesia, and left ventricular ejection fraction was 55%. In view of the high bleeding risk, thrombolysis or primary percutaneous transluminal coronary angioplasty could not be done. He was managed with dual antiplatelet therapy (aspirin plus clopidogrel), statins and angiotensin converting enzyme inhibitors. After five hours from onset, the chest pain subsided and ST segment elevation settled to baseline. Troponin T, obtained after 12 hours onset of chest pain, was 0.33 ng/ml (normal 0–0.3 ng/ml). His fasting lipid profile was normal (low density lipoprotein 127mg/dL, triglyceride 76mg/dL, high density lipoprotein 44 mg/dL). Serum lipoprotein (a) and homocysteine levels were within normal limits. Liver function tests were normal, with negative fibrinogen degradation product. The patient did not experience a recurrence of angina. The low grade atrioventricular block improved spontaneously over the next two days, possibly due to collateralisation.

DISCUSSION

Department Of
Cardiology,
Kasturba Medical
College,
Manipal,
Karnataka 576104,
India

Kumar N, MBBS
Postgraduate

Padma Kumar R,
MD, DM, DNB
Associate Professor

Ramesh B, MD, DM
Assistant Professor

Garg N, MBBS, MD
Registrar

Correspondence to:
Dr Naresh Kumar
Room no. 624,
NBQ Hostel,
Manipal University,
Manipal,
Karnataka 576104,
India
Tel: (91) 9 964 237 042
Email: doc_naresh@
yahoo.co.in;
nareshkgoval@
gmail.com

Table I. Summary of bleeding-related tests.

Factor 13 activity	No clot formed
Clot retraction	No clot formed
Fibrinogen antigenic assay	5.02%
Fibrinogen	Not detected (Clauss method)
Thrombin time	Control:13 seconds; patient > 2 minutes
Activated partial thromboplastin time (aPTT)	Control: 28.3 seconds; patient > 3 minutes
Prothrombin time (PT)	Control:12 seconds; patient > 2 minutes International normalised ratio (INR) >10
Platelets	326,000/mm ³
Bleeding time	2 minutes 30 seconds

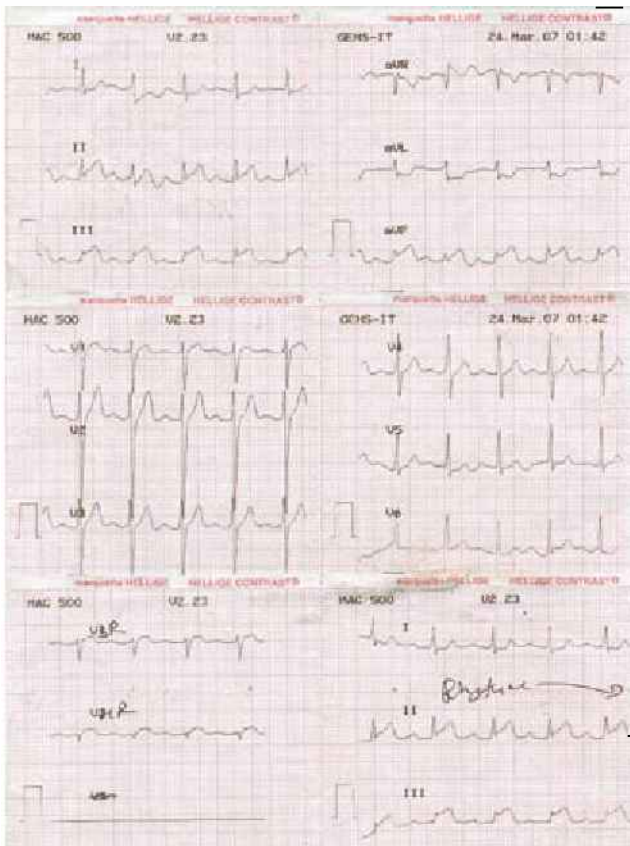


Fig. I ECG shows 2mm ST segment elevation in leads II, III, aVF and V4r; and ST depression in leads I and aVL.

Congenital afibrinogenemia is the result of defective fibrinogen synthesis.⁽⁵⁾ These patients are at risk of excessive bleeding as well as thrombosis. The tendency of a particular patient towards bleeding or thrombosis depends on the mutations they possess. Various mutations have been shown to be associated with thrombosis.⁽²⁾ They result in (1) Polymerisation abnormalities due to impaired fibrinopeptide B release; (2) Reduced fibrinolysis due to abnormalities that interfere with plasminogen binding or activation on the fibrin clot; and (3) Defective fibrin binding of thrombin, resulting in a prolonged activity of the unbound thrombin, leading to amplification of fibrin clot formation and enhanced platelet activation.

In afibrinogenemia, with fibrinogen levels less

than 0.1 g/L, bleeding manifestations range from mild to severe. Umbilical cord haemorrhage frequently provides an early alert to the abnormality. Thrombotic episodes⁽⁶⁾ have been found to occur with excessive transfusion of cryoprecipitate. In young patients with myocardial infarction, hypercoagulable states have to be ruled out.⁽⁷⁾ Tests should also be run to ensure normal liver function, and to confirm the absence of malnutrition and usage of fibrin degradation products. These results have to be obtained in order to rule out acquired causes of afibrinogenemia.⁽⁸⁾

Myocardial infarction in afibrinogenemia is a therapeutic challenge, as anticoagulants are contraindicated in these patients. It has been advised that antiplatelets can be used safely in these patients if the need arises, as we have done in our case. Anticoagulants have also been used in cases of recurrent thrombotic episodes as life-long therapy, but the patient has to be advised on the risk of bleeding; risk-benefit analysis should also be justifiable for the implementation of such a measure.⁽²⁾ Our patient did not experience any episodes of severe bleeding in his life or suffer acute myocardial infarction at a young age. He did not have any conventional or rare risk factors for atherosclerotic coronary artery disease. A work-up for thrombophilia was negative.

All the recent trials^(9,10) in ST elevation myocardial infarction (STEMI) comparing thrombolysis versus percutaneous coronary intervention (PCI) have clearly shown the advantage of using early PCI over STEMI, if no contraindications exist. Drug sensitivity is an important consideration as PCI requires the administration of heparin and Gp2b/3a inhibitors. As heparin was contraindicated in our patient, and without conclusive efficacy in treating afibrinogenemic patients using Gp2b/3a inhibitors, it was decided that the risk of bleeding outweighed any benefit afforded by PCI. PCI was therefore not considered for our patient.

Plasma coagulation proteins normally circulate in plasma in their biologically-inactive forms. When the thromboresistant nature of the vascular system is altered, the coagulation system is activated and this results in the formation of haemostatic thrombi, composed of platelets

and fibrin. The two pathways of coagulation (extrinsic pathway and intrinsic pathway) converge, which leads to generation of the pivotal coagulation enzyme, thrombin. At the site of vascular injury, platelets undergo adhesion, activation and aggregation to form an occlusive platelet plug. Membranes of the activated platelets facilitate thrombin generation by providing a surface for the assembly of coagulation factors and cofactors. Also, thrombin is a potent activator of platelets, stimulating the availability of additional activated platelet surface for further thrombin generation. This reciprocal interaction between thrombin and platelets promotes and amplifies the formation of a tightly-focused haemostatic plug composed of platelets and fibrin.⁽¹¹⁾ Fibrinolytic agents can lyse thrombin to recanalise occluded blood vessels. They are curative rather than prophylactic. Antiplatelet agents, on the other hand, interfere directly with platelet function, and are useful prophylaxis against thromboembolic disorders.

The clopidogrel in unstable angina to prevent recurrent events (CURE) Trial⁽¹²⁾ showed that a combination of clopidogrel and aspirin conferred a 20% reduction in cardiovascular deaths from myocardial infarction or stroke, when compared with treatment using aspirin alone, in both low and high risk patients with unstable angina/non-ST segment elevation myocardial infarction (NSTEMI). The efficacy and safety of this combination of clopidogrel and aspirin in patients with STEMI, especially in those receiving fibrinolytic therapy, has not been established, but this is currently being investigated in the clopidogrel as adjunctive reperfusion therapy-thrombolysis in myocardial infarction 28 (CLARITY-TIMI 28) and clopidogrel and metoprolol in myocardial infarction trial (COMMIT) trials. As no other therapy could be used in our patient, dual antiplatelet therapy was initiated.

A thrombotic event due to afibrinogenemia was likely to be the cause for acute myocardial infarction in this patient. We report this case to highlight the thrombotic complications that can occur in this rare bleeding diathesis, and to elicit discussion on the management issues involved.

REFERENCES

1. Rabe F, Salomon E. [Ueber-faserstoffmangel im Blute bei einem Falle von Hämophilie]. *Arch Int Med* 1920; 95:2-14. German.
2. Israels SJ. Inherited abnormalities of fibrinogen. In: *emedicine* from webMD [online]. Available at: www.emedicine.com/ped/topic3042.htm. Accessed April 2, 2007.
3. Anwar M, Iqbal H, Gul M, Saeed N, Ayyub M. Congenital afibrinogenemia: report of three cases. *J Throm Haemost* 2005; 3:407-9.
4. Leeners JV, Mossakowski J, Kayser S. [Case report of congenital afibrinogenemia]. *Klin Padiatr* 1995; 207:34-5. German.
5. Al Mondhiry H, Ehmann WC. Congenital afibrinogenemia. *Am J Hematol* 1994;46:343-7.
6. Lak M, Keihani M, Elahi F, Peyvandi F, Mannucci PM. Bleeding and thrombosis in 55 patients with inherited afibrinogenemia. *Br J Haematol* 1999; 107:204-6.
7. Girolami A, Ruzzon E, Tezza F, et al. Arterial and venous thrombosis in rare congenital bleeding disorders: a critical review. *Haemophilia* 2006; 12:345-51.
8. Awasthy N, Aggarwal KC, Gupta H, Saluja S. Congenital hypofibrinogenemia. *Indian Pediatr* 2004; 41:185-7.
9. Zahn R, Schuster S, Schiele R, et al. Comparison of primary angioplasty with conservative therapy in patients with acute myocardial infarction and contraindications for thrombolytic therapy. Maximal Individual Therapy in Acute Myocardial Infarction (MITRA) Study Group. *Catheter Cardiovasc Interv* 1999; 46:127-33.
10. Juliard JM, Himbert D, Golmard JL, et al. Can we provide reperfusion therapy to all unselected patients admitted with acute myocardial infarction? *J Am Coll Cardiol* 1997; 30:157-64.
11. Bennett JS. Platelet-fibrinogen interactions. *Ann N Y Acad Sci* 2001;936:340-54.
12. Yusuf S, Zhao F, Mehta SR; Clopidogrel in Unstable Angina to Prevent Recurrent Events Trial Investigators. Effects of clopidogrel in addition to aspirin in patients with acute coronary syndromes without ST-segment elevation. *N Engl J Med* 2001; 345:494-502.