

# Medullary carcinoma in a lingual thyroid

Yadav S, Singh I, Singh J, Aggarwal N

## ABSTRACT

**Total ectopia of thyroid is a rare phenomenon and malignant change in an ectopic thyroid is even rarer. We report a case of medullary carcinoma in a total ectopic lingual thyroid occurring in a 45-year-old woman who presented with dysphagia, plummy voice and a round sessile mass at the base of the tongue. The mass was extirpated using Trotter's midline approach. Upon examination, it was found to be medullary carcinoma in an ectopic thyroid. Permanent substitution therapy with thyroxine secured the euthyroid status of the patient. The embryological basis and a review of literature regarding carcinomatous change in an ectopic thyroid is also discussed. There is a need to investigate for an ectopic thyroid, or even total ectopia, in the case of any smooth mass found at the base of the tongue.**

**Keywords:** calcitonin, ectopic thyroid, lingual thyroid, medullary carcinoma, thyroid carcinoma, thyroid gland

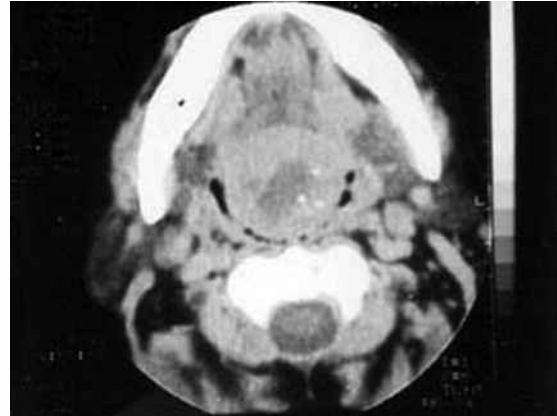*Singapore Med J 2008;49(3):251-253*

## INTRODUCTION

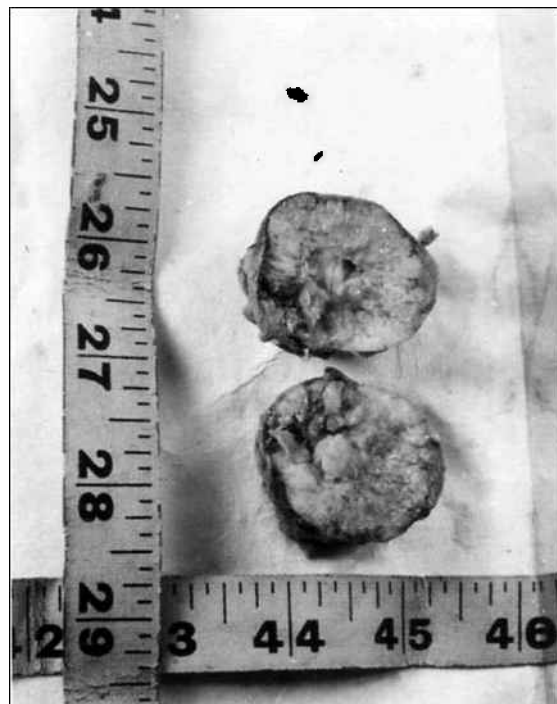Embryologically, the thyroid gland develops as the first pharyngeal derivative by an endodermal diverticulum, in the midline of the ventral pharynx between the first and second pharyngeal pouches. A diverticulum descends caudally into the loose prepharyngeal connective tissue and passes anterior to the developing hyoid bone and forms most of the thyroid parenchyma. However, parafollicular C-cells reach the thyroid by ultimobranchial bodies, which are the product of the fourth and fifth branchial pouches and form 1%–30% of the thyroid weight.<sup>(1)</sup> Failure of descent of either the medial anlage of the thyroid, or the ultimobranchial bodies, and the incomplete obliteration of its vertical tract, lead to ectopic thyroid development. The ectopic thyroids are usually located in the midline from the base of tongue to the diaphragm, but can be also be present laterally. Lingual thyroid is not a very common lesion; carcinomatous change in it is very rare. The majority of carcinomas observed in the lingual thyroid are reported to be follicular,<sup>(2,3)</sup> with very few case reports of papillary carcinoma.<sup>(4)</sup> However, medullary carcinoma in ectopic thyroid is almost unknown. The authors report a case of medullary carcinoma in an ectopic lingual thyroid.

## CASE REPORT

A 45-year-old woman attended the outpatient department of otolaryngology at our Institute with chief complaints of difficulty in swallowing and change of voice for the last



**Fig. 1** Axial CT image taken at the level of mandible shows a round hyperdense structure with few calcified specks in it located at the posterior aspect of the tongue.



**Fig. 2** Specimen photograph shows the excised encapsulated mass.

two years. Initially, the symptoms were very mild, i.e. the patient had a foreign body sensation, or the impression of something stuck in the throat. Subsequently, she developed some difficulty in taking solids accompanied with a marked change in her speech. There was no difficulty in swallowing liquids, but her voice had perceptibly taken on to a plummy character. The patient also started snoring heavily. However, there was no evidence of sleep apnoea. There was also no symptom suggestive of disturbed thyroid status. On clinical examination of her oral cavity, a mass was noted at the base of the tongue during its protrusion. The indirect laryngoscopic examination revealed a

Department of  
Otorhinolaryngology,  
Post Graduate  
Institute of Medical  
Sciences,  
Rohtak 124001,  
India

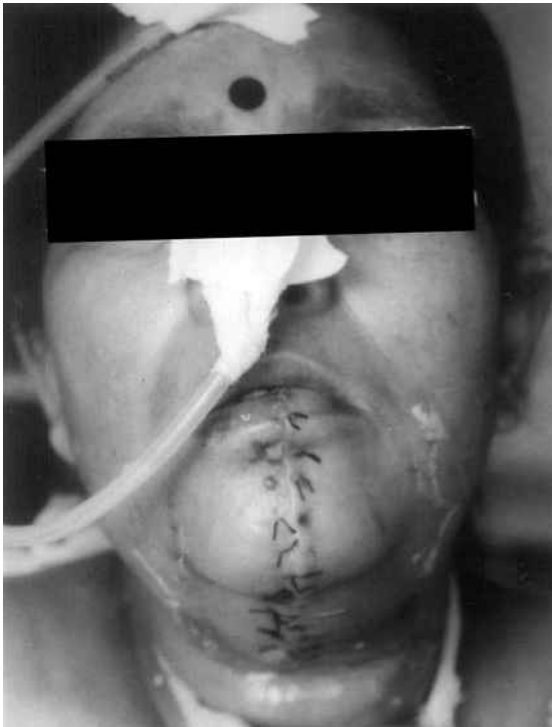Yadav S, MS, FAMS  
Associate Professor

Singh I, MS  
Senior Resident

Singh J, MS  
Lecturer

Aggarwal N, MBBS  
Resident

**Correspondence to:**  
Dr Neeraj Aggarwal  
c/o Dr SPS Yadav,  
30/9J Medical Enclave,  
Rohtak 124001,  
India  
Tel: (91) 935 562 8602  
Fax: (91) 126 221 1308  
Email: neeraj9704  
@yahoo.com

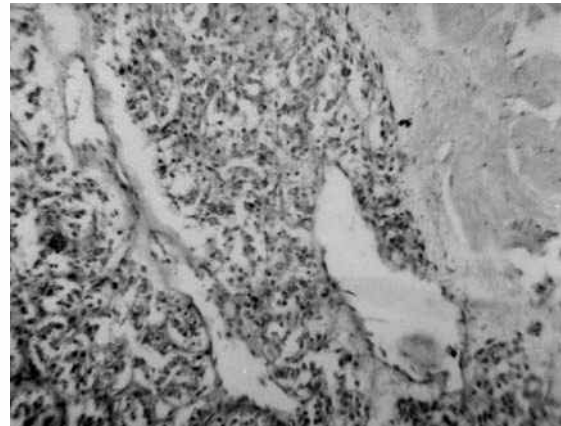


**Fig. 3** Postoperative clinical photograph of the patient shows the midline incision used.

round, sessile mass of approximately 4 cm in diameter in the midline, at the base of the tongue. On palpation, the mass was firm and immobile with well-defined margins, smooth surface and overlying normal mucosa. No cervical lymph nodes could be palpated. Routine preoperative investigations, such as complete haemogram and urine examinations, were within normal limits.

Axial computed tomography (CT) (Fig. 1) taken at the level of the mandible showed a round hyperdense structure with a few calcified specks at the posterior aspect of tongue. The neck was not included in the CT, as clinically it was not suspected to be lingual thyroid. Fine-needle aspiration cytology (FNAC) of the mass revealed it to be a monomorphic adenoma. The encapsulated mass (Fig. 2) was excised in total using Trotter's midline approach (Fig. 3). The wound was stitched in layers and the mandible was fixed by wire. The patient developed pharyngocutaneous fistula postoperatively, which healed on conservative management in two weeks, and the patient was discharged.

The histopathology of the excised mass revealed it to be medullary carcinoma of the thyroid. The tumour showed a solid proliferation of round and polygonal cells of granular amphophilic cytoplasm and medium-sized nucleus. These cells were separated by scanty stroma, hyalinised collagen and amyloid (Fig. 4). Immunohistochemically, the tumour cells were positive for calcitonin. During follow-up, she was found to have developed features of hypothyroidism, which was confirmed on investigations for the thyroid status. Ultrasonography of the thyroid, and the thyroid scintiscan, revealed the absence of any thyroid tissue in the body. She has been on regular thyroxine supplements, and has been regularly followed-up on, for the last ten years. Her serum calcitonin levels are also being monitored



**Fig. 4** Photomicrograph shows characteristic cellular morphology of medullary carcinoma (Haematoxylin & eosin  $\times 100$ ).

regularly.

## DISCUSSION

Lingual thyroid results from a defect in the embryological development. The tongue is the most usual site for a total ectopy of the thyroid.<sup>(5)</sup> Incidence of lingual thyroid remnants has been reported to be up to 10% in an autopsy series.<sup>(6,7)</sup> Montgomery, in an extensive review of the subject, reported in 1935 that in 70% of cases, the ectopic gland is the only thyroid tissue present, while in 30% of such cases, the thyroid tissue is also present at the usual site, as was observed in another study.<sup>(8,9)</sup> On hindsight, we totally agree with the recommendation made in previous studies to always keep in mind the possibility of lingual thyroid whenever a patient presents with a mass in the tongue, and to carry out <sup>131</sup>I uptake.<sup>(2,4)</sup> However, we did not investigate the thyroid status as we were misled by the FNAC results. A few studies have found labelled thyroglobulin as the most useful immunohistological marker to confirm the thyroid origin of the tissue.<sup>(10-12)</sup> The majority of lingual thyroid cases are asymptomatic and are usually found on routine oral examination. The usual presenting symptom in lingual thyroid is dysphagia; however, pain, dysphonia and dyspnoea may also be observed. Our patient presented with a complaint of dysphagia, plummy voice and snoring.

Carcinomatous change in the lingual thyroid is rather rare. According to Buckman, the earliest case of cancer in the lingual thyroid was reported in 1910 by Gunn and Rutgers.<sup>(13)</sup> Frequency of lingual thyroid carcinoma is estimated by Jarvis to be approximately one in 100 cases, with a female-to-male ratio ranging from 3:1 to 8:1.<sup>(14)</sup> Age ranges from 12 to 86 years, with most carcinomas occurring in the third decade of life.<sup>(15)</sup> The majority of these are reported to be follicular<sup>(2,3)</sup> and rarely, papillary carcinomas.<sup>(4)</sup> Medullary carcinoma of the thyroid generally constitutes 5%–10% of all thyroid malignancies,<sup>(16)</sup> and was first recognised in 1959 as a distinct clinical entity.<sup>(17)</sup> It develops mainly in subjects during their fourth decade of life, although the overall age range is from 10 to 79 years, with a female preponderance, as was seen in the present case. In 50%–75% of cases, the condition is familial and is a part of the multiple endocrine

neoplasia (MEN) syndrome.

Grossly, the tumour appears firm or hard, grey-white, sometimes gritty and is usually fairly well-demarcated. But infrequently, encapsulated lesions are also seen, as was seen in the present case. Areas of haemorrhage, fibrosis, necrosis and calcification may be evident on a cut section. Basic histopathological structure consists of uniform polygonal or spindle-shaped cells arranged in solid cords, trabeculae, festoons, whorls and nests of varying sizes, or large masses separated by a hyaline, usually abundant amyloid stroma,<sup>(18)</sup> which may be demonstrated by Congo red stain. Medullary carcinoma of thyroid arises from the parafollicular cells or C-cells of the thyroid.<sup>(19)</sup> In this particular case, the medullary carcinoma arose primarily in the lingual thyroid. After surgery, the patient became hypothyroid, suggesting that this was the only thyroid tissue in the body. This rules out the possibility of any occult primary tumour anywhere else. Although there is no data on the occurrence of C-cell rests in the tongue, the presence of such cells in the thymus and parathyroid indicates that their migration is occasionally subject to aberration.<sup>(20)</sup> This aberrant migration might be the source of C-cells in this case.

Another possible source of medullary carcinoma in the lingual thyroid may be the embryonal endocrine cell rests in the region of the first and second pharyngeal pouch. These rests may have adopted the morphological and biological properties of C-cells during the process of neoplastic transformation. C-cells produce the polypeptide hormone calcitonin. Estimates of its basal level, or after stimulation with calcium, or pentagastrin injection intravenously are of diagnostic value in understanding medullary carcinoma of the thyroid. We followed-up the patient for ten years and monitored the calcitonin level, which remained consistently low, thus ruling out any recurrence. Although medullary carcinomas do frequently metastasise to the regional lymph nodes, this did not occur in the present case. We investigated the patient to rule out any MEN syndrome and found no evidence of it; this confirmed she had a rare sporadic case of medullary carcinoma in the ectopic lingual thyroid.

Lesions at the base of the tongue are very infrequent. They present with soreness, discomfort or fullness of throat, dysphonia, dysphagia, snoring and a plummy voice. The differential diagnosis includes squamous cell and other carcinomas, lymphoma, hypertrophy of lingual tonsil, lingual thyroid and mixed salivary tumour. Rarely-reported lesions may include malignant change in lingual thyroid, schwannoma, myoepithelioma, haemangioma, leiomyoma, granular cell tumour, alveolar soft part carcinoma and various cystic lesions, such as epidermoid branchial cyst and lingual thyroglossal cyst. These lesions present with similar symptoms, except that odynophagia and referred otalgia point towards malignancy, especially squamous cell carcinoma. On examination, the squamous cell carcinoma is an ulceroproliferative lesion with marked induration. Lingual thyroid is smooth, nodular and shows surface vascularity.

The imaging features of these lesions are not very

characteristic except in lingual thyroid, where CT shows high attenuation because of high iodine content. Contrast enhancement also increases the differential density of the lingual thyroid as compared to surrounding tissue. In malignancy at the base of the tongue, CT is done to show the infiltration in the muscles, lymph node metastasis and planning of radiotherapy. Squamous cell carcinoma shows inhomogenous lesion enhancement. CT and magnetic resonance (MR) imaging can easily diagnose cystic lesions, but the type of cyst, e.g. branchiogenic or lingual thyroid duct cyst, can be difficult to differentiate. Other types of lesions are so uncommon that CT or MR imaging can merely indicate whether the lesion is likely to be benign or malignant. There are no specific diagnostic characteristics except that the lesion, e.g. haemangioma, will appear similar as in any other part of the body and the final diagnosis can only be established by biopsy, as was demonstrated in the present case.

#### ACKNOWLEDGEMENT

The authors gratefully acknowledge Dr Rohit Sharma, pathologist, for providing the histological diagnosis.

#### REFERENCES

- Collins P. Embryology and development. In: Williams PL, Bannister LH, Berry MM, et al, eds. *Gray's Anatomy - The Anatomical Basis of Medicine and Surgery*. 38th ed. New York: Churchill Livingstone 1995: 174-99.
- Goeder P. Follicular carcinoma in a lingual thyroid. *J Laryngol Otol* 1980; 94:437-9.
- Diaz-Arias AA, Bickel JT, Loy TS, et al. Follicular carcinoma with clear cell change arising in lingual thyroid. *Oral Surg Oral Med Oral Pathol* 1992; 74:206-11.
- Singh HB, Joshi HC, Chakravarty M. Carcinoma of the lingual thyroid. Review and case report. *J Laryngol Otol* 1979; 93:839-44.
- Batsakis JG, EL-Naggar AK, Luna MA. Thyroid gland ectopias. *Ann Otol Rhinol Laryngol* 1996; 105:996-1000.
- Baughman RA. Lingual thyroid and lingual thyroglossal tract remnants: a clinical and histopathologic study with review of the literature. *Oral Surg Oral Med Oral Pathol* 1972; 34:781-99.
- Sauk JJ. Ectopic lingual thyroid. *J Pathol* 1970; 102:239-43.
- Montgomery ML. Lingual thyroid: a comprehensive review. *West J Surg* 1935; 43:661-9.
- Farrell ML, Forer M. Lingual thyroid. *Aust N Z J Surg* 1994; 64:135-8.
- Albores-Saavedra J, Nadji M, Civantos F, Morales AR. Thyroglobulin in carcinoma of the thyroid: an immunohistochemical study. *Hum Pathol* 1983; 14:62-6.
- Logmans SC, Jöbsis AC. Thyroid-associated antigens in routinely embedded carcinomas. Possibilities and limitations studied in 116 cases. *Cancer* 1984; 54:274-9.
- Davila RM, Bedrossian CW, Silverberg AB. Immunocytochemistry of the thyroid in surgical and cytologic specimens. *Arch Pathol Lab Med* 1988; 112:51-6.
- Buckman LT. Lingual thyroid. *Laryngoscope* 1936; 46:765.
- Jarvis JF. Lingual thyroid: a report of three cases and discussion. *S Afr Med J* 1969; 43:8-12.
- LiVolsi VA, Perzin KH, Savetsky L. Carcinoma arising in median ectopic thyroid (including thyroglossal duct tissue). *Cancer* 1974; 34:1303-15.
- Brunt LM, Wells SA Jr. Advances in the diagnosis and treatment of medullary thyroid carcinoma. *Surg Clin North Am* 1987; 67:263-79.
- Hazard JB, Hawk WA, Grile G. Medullary (solid) carcinoma of the thyroid - a clinicopathologic entity. *J Clin Endocrinol Metab* 1959; 19:152-61.
- Saad MF, Fritsche HA Jr, Samaan NA. Diagnostic and prognostic values of carcinoembryonic antigen in medullary carcinoma of the thyroid. *J Clin Endocrinol Metab* 1984; 58:889-94.
- Williams ED. Histogenesis of medullary carcinoma of the thyroid. *J Clin Pathol* 1966; 19:114-8.
- Galante L, Gudmundsson TV, Matthews ET, et al. Thymic and parathyroid origin of calcitonin in man. *Lancet* 1968; 2:537-8.