

An early experience of liver transplantation in portal vein thrombosis

Shelat V G, Diddapur R K

ABSTRACT

Portal vein thrombosis (PVT) is a recognised complication of end-stage liver disease. As PVT is a relative contraindication to liver transplantation, potential candidates are often rejected due to increased risk and complexity of the surgical procedure. Thromboendovenectomy is a commonly-used technique for this vexing problem. We report a surgeon's experience of dealing with PVT at the time of liver transplantation. Two patients with liver cirrhosis and PVT underwent orthotopic liver transplantation (OLT) at the National University Hospital. The case notes of these two patients were retrospectively reviewed, along with a brief review of literature. Our early experience shows that with careful case selection and meticulous surgical technique, OLT can be safely done in patients with PVT without significant complications.

Keywords: end-stage liver disease, liver transplantation, portal vein thrombosis, thromboendovenectomy

Singapore Med J 2008;49(2):e37-e41

INTRODUCTION

Splanchnic vein thrombosis used to be a contraindication for orthotopic liver transplantation (OLT). Preoperative work-up may fail to detect splanchnic vein thrombosis and transplant candidates can develop *de novo* thrombosis while they are on the waiting list. The modern era transplant surgeon has to be familiar with the current strategies of dealing with splanchnic venous thrombosis. The technique can vary from simple thromboendovenectomy to complex venous bypass and reconstructive procedures. The inability to restore portal venous inflow to nurture the transplanted liver has resulted in a very high mortality.⁽¹⁾ We report a single surgeon's experience (RKD) of dealing with portal vein thrombosis (PVT) at the time of liver transplantation.

CASE REPORTS

All liver transplant patients at the National University Hospital were retrospectively analysed. Two patients with cirrhosis and PVT underwent OLT at the hospital (Table I).

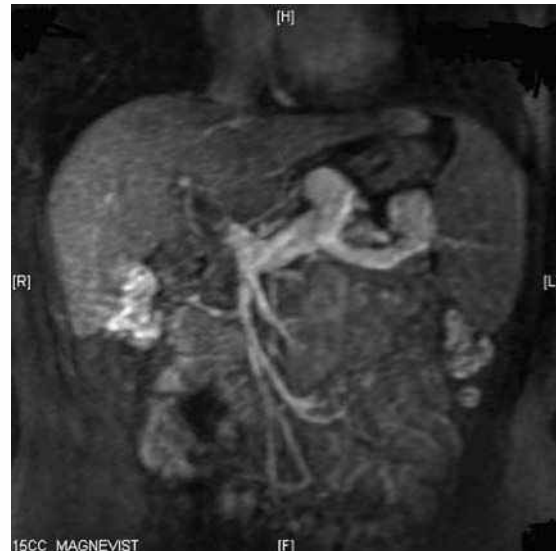

Fig. 1 Contrast-enhanced MR image shows Yerdel's Grade II PVT.

Case 1

A 47-year-old male diabetic patient with hepatitis B cirrhosis and associated hypersplenism was worked up for liver transplantation. His magnetic resonance (MR) imaging revealed a complete thrombus in the portal vein extending up to the splenomesenteric confluence (Yerdel Grade II) (Fig. 1). MR imaging also showed the common hepatic artery originating from the superior mesenteric artery. He underwent thromboendovenectomy during OLT. The duodenum was kocherised, and the right and left portal veins were dissected and looped. The common portal vein was dissected to beneath the head of pancreas distal to the thrombus. Thrombosis of the portal vein was approached by dissection of the entire length of the portal vein up to the splenomesenteric confluence (Fig. 2). This was achieved by ligating the coronary vein and the distal short pancreatic veins securing meticulous haemostasis. A soft vascular clamp (spoon-shaped DeBakey's vascular clamp) was applied to the common portal vein towards the splenomesenteric confluence beyond the thrombus. Stay sutures at three o'clock and nine o'clock positions were taken in the portal vein with 5-0 polypropylene. The common portal vein was then controlled with fingers (thumb and index) and thromboendovenectomy was completed using a combination of Fogarty's balloon catheter, endarterectomy spatula and vascular forceps

Hepatobiliary & Pancreatic Surgery and Liver Transplant Unit, Department of Surgery, National University Hospital, Singapore 119074

Shelat VG, MS, MRCSE, MRCPSClinical Fellow

Diddapur RK, FRCS, Hesperis Diploma in Transplantation (ECOT), FAMS Consultant and Acting Head

Correspondence to: Dr Ravishankar K Diddapur Specialist Surgery Singapore Pte Ltd, #02-35, Gleneagles Hospital (Annexe Block), 6A Napier Road, Singapore 258500 Tel: (65) 9181 7293 Fax: (65) 6479 7608 Email: ravi_diddapur@hotmail.com

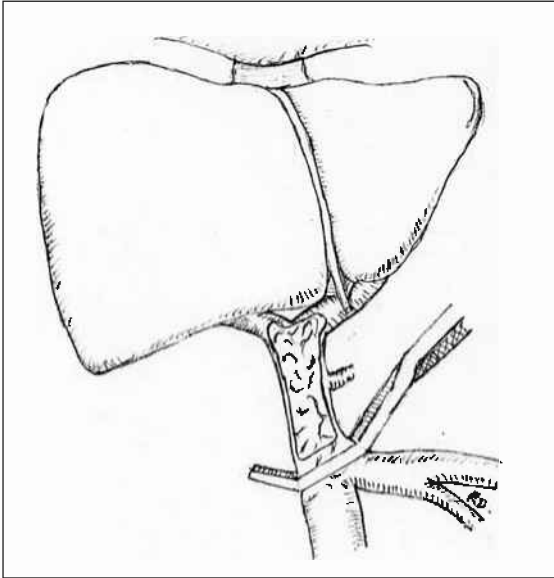


Fig. 2 Diagram shows the window in the portal vein to demonstrate the thrombus; the dissection is up to the splenomesenteric confluence.

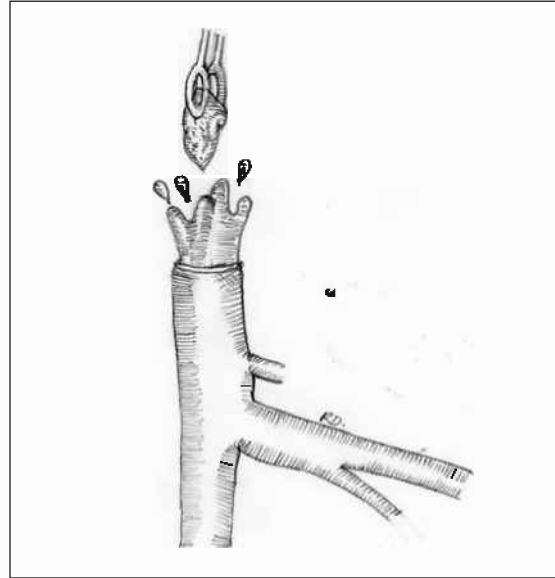

Fig. 3 Diagram shows the thromboendovenectomy being performed.

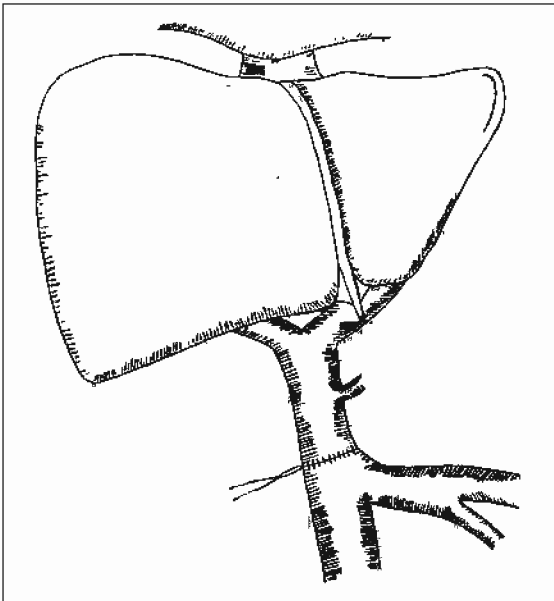


Fig. 4 Diagram shows the end-to-end porto-portal vein anastomosis with growth factor.

(Fig. 3).

Thromboendovenectomy was performed, and the organised thrombus, along with intima, was dissected with the endarterectomy spatula. Dissection in the correct plane ensures complete removal of the thrombus with a smooth-tapered edge. The intima was then stitched to the adventitia using 6-0 polypropylene suture where it was separated. The donor common portal vein was anastomosed to the recipient common portal vein with polypropylene 6-0 with eversion of edges after taking care for growth factor (Fig. 4). Prior to portal venous anastomosis, we flushed the recipient portal vein with heparinised saline to remove any clots. Intraoperatively, Doppler ultrasonography (US) was used to confirm patency of the portal vein.

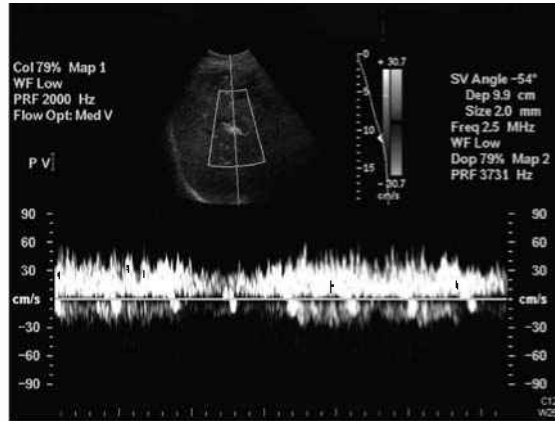


Fig. 5 Postoperative Doppler US image shows good flow in the portal vein with peak velocity of approximately 40 cm/sec.

Postoperatively, we used Doppler monitoring for assessing the patency and flow characteristics of the portal vein. Intraoperative blood loss was 5 L, and the postoperative course was complicated by arrhythmias that needed repositioning of the pulmonary artery catheter. The patient also developed an infection by *Klebsiella pneumoniae* and anastomotic bile duct stricture. The stricture needed endoscopic stenting. The biliary stent was removed three months later without any residual stricture demonstrated. His hospital stay was two weeks and he was doing well at 30 months follow-up. The follow-up Doppler US confirmed a good portal venous flow with a velocity of 40 cm/sec (Fig. 5).

Case 2

A 45-year-old male diabetic patient with a past history of alcohol abuse developed alcoholic cirrhosis that was proven by biopsy. He had grade 1 encephalopathy and ascites. He also had past history of haematemesis. After abstinence for six months, he was worked up for liver

Table I. Clinical characteristics of two patients with PVT undergoing thromboendovenectomy.

Case	Gender	Age (years)	Diagnosis	Yerdel's grade	ICU stay (days)	Hospital stay (weeks)	Follow-up (months)	Rethrombosis
1	Male	47	Hepatitis B cirrhosis	II	3	2	30	No
2	Male	45	Alcoholic liver cirrhosis	III	10	4	8	No

Table II. Grading of portal vein thrombosis, according to Yerdel et al.⁽¹⁴⁾

Grade	Definition
I	< 50% thrombosis of portal vein with or without minimal extension into the SMV.
II	> 50% occlusion of the portal vein, including total occlusions, with or without minimal extension into the SMV.
III	Complete thrombosis of both portal vein and proximal SMV. Distal SMV is patent.
IV	Complete thrombosis of the portal vein and proximal as well as distal SMV.

transplantation. His computed tomography (CT) of the abdomen revealed multiple varices, splenomegaly, gross ascites and PVT. The thrombosis involved the confluence of splenic and superior mesenteric veins along with extension into proximal superior mesenteric vein (Yerdel Grade III). He underwent thromboendovenectomy during OLT, as discussed in the previous case. Immediately postoperatively, his abdominal drain revealed fresh bleeding and so he was re-explored again. The hepatic artery anastomotic site was found to be bleeding and the anastomosis was refashioned. Ascites, bilateral pleural effusions and wound infection complicated his postoperative course. Ascites needed ultrasound-guided tapping with volume-to-volume replacement by salt free albumin. The wound was infected by methicillin-resistant *Staphylococcus aureus* (MRSA) and needed regular dressing after pus drainage. He was discharged after four weeks, and he is currently doing well at eight months of follow-up.

Thromboendovenectomy was successful in both patients; they were not put on any platelet anti-aggregate agents (like aspirin) or anticoagulants (like heparin/warfarin) postoperatively. Both patients did not develop rethrombosis after surgery and were well at follow-up.

DISCUSSION

PVT occurs in 5%–26% of end-stage liver disease patients.^(2,3) Cirrhotic patients with end-stage liver disease have increased intrahepatic resistance to portal flow. The increased resistance, along with the disseminated intravascular coagulopathy of cirrhosis, and endothelial injury due to portal hypertension, increases the incidence of PVT. It is more common for patients with cryptogenic cirrhosis, post-necrotic cirrhosis, autoimmune chronic active hepatitis, trauma, previous dissection of porta hepatis, tumours and previous splenectomy, to have PVT.⁽⁴⁻⁷⁾ PVT is also more common in male patients.⁽⁵⁾ Viability of an allograft is dependent on portal flow, and

hence patency of the portal vein needs to be maintained.⁽⁸⁾ Lerut et al reported 100% mortality when the liver is deprived of portal venous inflow.⁽¹⁾

Patients with PVT have a shrunken liver, large spleen, ascites and oesophageal varices. Doppler ultrasound and helical CT scans are highly accurate for diagnosing splanchnic vein thrombosis.^(9,10) All the patients on the waiting list at National University Hospital undergo trimonthly Doppler screening. There have been reports of 35%–57% incidence of unexpected PVT, found at transplantation, in patients who had negative results on previous duplex examinations.^(5-7,11-13) The higher false negative rate is attributed to post-duplex PVT, while patients are on the waiting list, and the identification of large portal collateral veins as the portal vein.⁽¹¹⁾ PVT can be graded preoperatively (Table II).⁽¹⁴⁾

Shaw et al first reported successful OLTs in patients with PVT using portal vein grafts.⁽¹⁵⁾ Presently, almost all patients with splanchnic vein thrombosis can have OLT. If the patients have PVT, the high-risk nature of surgery should be explained to the patient and informed consent should be obtained. In unsuspected PVT cases, the surgeon should be able to modify the surgery based on intraoperative evaluation and grading of the thrombus. In either case, the careful planning of the surgery and vigilant intraoperative assessment by experienced personnel is essential. However, with improved imaging modalities, this should be a rarity. Dissection of collateral rich hepatoduodenal ligament and thrombosed splanchnic veins, along with restoration of portal perfusion, demands high levels of surgical expertise. Portal perfusion can be restored from simple procedures like thromboendovenectomy, to the use of complex procedures using venous bypass and reconstruction. Isolated segmental PVT can be dealt with thromboendovenectomy.

When the thrombus involves the whole portal vein up to the splenomesenteric confluence, thromboendovenectomy can still be done, as in both of our cases. In some cases where

Table III. Various series on liver transplantation with PVT.

Study	No. patients	Doppler ultrasound	Blood transfusion /loss	ICU stay	Rethrombosis	Mortality/survival
Manzanet et al ⁽⁴⁾	62	Sensitivity 29% Specificity 97.5%	-	Comparable	3 patients	4-year survival is 71%
		Comments: Early reoperation rate (including retransplantation) was greater in patients with complete extensive PVT. Complete PVT with involvement of splanchnic vein has 33% mortality. All the patients with rethrombosis died.				
Andrei et al ⁽⁵⁾	34	-	-	-	-	Survival 67.6%
		Comments: Encouraging results with portal arterialisation and anticoagulation. Blood transfusion of > 30 units was associated with high mortality. Survival is lower in patients with extensive thrombosis.				
Shaked et al ⁽⁷⁾	23	Specificity > 93% False negative rate 35%	-	11.5 days	-	3-month mortality 35%
		Comments: Incidence of early (immediate) or delayed (3–6 days) primary non-function of the liver graft was 35% for PVT and 8% for patients without PVT.				
Seu et al ⁽¹¹⁾	70	False negative rate 34%	Mean blood transfusion was 23 units	-	3%	1-year survival 74%
		Comments: 87% cases were successfully managed by thromboendovenectomy.				
Langnas et al ⁽¹²⁾	16	Specificity 87%	Mean blood loss was 22 units	-	1 patient	1-year survival 81%
Yerdel et al ⁽¹⁴⁾	63	-	Mean blood transfusion was 10 units	-	-	5-year survival 65.6%
		Comments: 30% mortality for PVT patients versus 12.4% in controls.				
Francoz et al ⁽¹⁷⁾	38	-	-	-	-	2-year survival 83%
		Comments: 7.4% develop <i>de novo</i> thrombosis during follow-up on the waiting list or preoperatively. Low platelet count and past history of variceal bleeding were the only independent predictive factors for thrombosis.				
Molmenti et al ⁽¹⁸⁾	85	-	Mean requirement 6.23 units	5.75 days	2.4%	1-year patient survival 84.9%

there is sclerosis of the portal vein along with thrombosis, the portal vein can be excised and an interposition iliac vein graft can be used to anastomose the donor portal vein to the recipient splenomesenteric confluence. Common iliac veins are hence routinely harvested at the time of cadaveric multiorgan retrieval. Extensive splanchnic venous thrombosis involving the splenic and/or superior mesenteric veins can be dealt with by the use of an extra anatomic jump graft from the superior mesenteric vein to the donor portal vein. When an appropriate superior mesenteric vein segment is not available for jump graft, a jump graft from the left renal vein to the portal vein of the donor graft can be used for reconstruction. This is usually brought anterior to the pancreas and duodenum. In a living-related transplantation, a cryopreserved vascular graft of similar nature can be used.

Techniques using the internal jugular vein, saphenous vein or inferior mesenteric vein of the recipient have also been described. However, these not only carry higher risks, but also the experience of evidence for them is

limited. Arterialisation of portal vein⁽¹⁶⁾ and cavoportal hemitransposition (CPHT)⁽¹⁷⁾ has been reported by others to restore the portal perfusion. Table III shows various case series on PVT and liver transplantation. The results of surgery involving PVT have improved with experience, and are comparable to results of OLT in patients without PVT.^(11,14,18) In a study by Francoz, the proportion of partial or complete recanalisation was higher in those who received anticoagulation than in those who did not.⁽¹⁷⁾ We do not anticoagulate our patients routinely, except for Budd-Chiari syndrome or rethrombosis.

A recent meta-analysis of 15 studies including 56 OLTs with CPHT and renoportal anastomosis (RPA), revealed early encouraging results at short-term follow-up. Ascites, renal dysfunction, lower extremity and torso oedema, and variceal bleeding were common postoperative complications after CPHT and RPA.⁽¹⁹⁾ When PVT extends diffusely to the peripheral parts of the mesenteric veins, a combined small intestine and liver transplantation may be the only option. Experience with cluster transplantation is

very limited and is usually reserved if there is associated intestinal failure. Many series report that the results of surgery for PVT in OLT improve with experience, and the results are comparable to OLT in patients without PVT. Although it is not an absolute contraindication to liver transplantation, PVT is still a factor that adds to the technical challenge, complexity, morbidity and mortality of the procedure. Our early experience shows that with careful case selection and meticulous surgical technique, OLT can be safely done in patients with PVT without significant complications.

REFERENCES

1. Lerut J, Tzakis AG, Bron K, et al. Complications of venous reconstruction in human orthotopic liver transplantation. *Ann Surg* 1987; 205:404-14.
2. Nonami T, Yokoyama I, Iwatsuki S, Starzl TE. The incidence of portal vein thrombosis at liver transplantation. *Hepatology* 1992; 16:1195-8.
3. Okuda K, Ohnishi K, Kimura K, et al. Incidence of portal vein thrombosis in liver cirrhosis. An angiographic study in 708 patients. *Gastroenterology* 1985; 89:279-86.
4. Manzanet G, Sanjuán F, Orbis P, et al. Liver transplantation in patients with portal vein thrombosis. *Liver Transplantation* 2001; 7:125-31.
5. Stieber AC, Zetti G, Todo S, et al. The spectrum of portal vein thrombosis in liver transplantation. *Ann Surg* 1991; 213:199-206.
6. Davidson BR, Gibson M, Dick R, et al. Incidence, risk factors, management and outcome of portal vein abnormalities at orthotopic liver transplantation. *Transplantation* 1994; 57:1174-7.
7. Shaked A, Busuttil RW. Liver transplantation in patients with portal vein thrombosis and central portacaval shunts. *Ann Surg* 1991; 214:696-702.
8. Starzl TE, Francavilla A, Halgrimson CG, et al. The origin, hormonal nature and action of hepatotrophic substances in portal venous blood. *Surg Gynecol Obstet* 1973; 137:179-99.
9. Miller VE, Berland LL. Pulsed Doppler duplex sonography and CT of portal vein thrombosis. *Am J Roentgenol* 1985; 145:73-6.
10. Marn CS, Francis IR. CT of portal venous occlusion. *AJR Am J Roentgenol* 1992; 159:717-26.
11. Seu P, Shackleton CR, Shaked A, et al. Improved results of liver transplantation in patients with portal vein thrombosis. *Arch Surg* 1996; 131:840-4.
12. Langnas AN, Marujo WC, Stratta RJ, et al. A selective approach to preexisting portal vein thrombosis in patients undergoing liver transplantation. *Am J Surg* 1992; 163:132-6.
13. Moreno González E, García García I, Gómez Sanz R, et al. Liver transplantation in patients with thrombosis of the portal, splenic or superior mesenteric vein. *Br J Surg* 1993; 80:81-5.
14. Yerdel MA, Gunson B, Mirza D, et al. Portal vein thrombosis in adults undergoing liver transplantation: risk factors, screening, management and outcome. *Transplantation* 2000; 69:1873-81.
15. Shaw BW Jr, Iwatsuki S, Bron K, et al. Portal vein grafts in hepatic transplantation. *Surg Gynecol Obstet* 1985; 161:66-8.
16. Sheil AGR, Thompson JF, Stephen MS, et al. Donor portal vein arterialization during liver transplantation. *Transplant Proc* 1989; 21(1 Pt 2):2343-4.
17. Francoz C, Belghiti J, Vilgrain V, et al. Splanchnic vein thrombosis in candidates for liver transplantation: usefulness of screening and anticoagulation. *Gut* 2005; 54:691-7.
18. Molmenti EP, Roodhouse TW, Molmenti H, et al. Thrombectomy for organized portal vein thrombosis at the time of liver transplantation. *Ann Surg* 2002; 235:292-6.
19. P Marius, J Jonas, M Arianeb, et al. Surgical strategies for liver transplantation in the case of portal vein thrombosis – current role of cavoportal hemitransposition and renoportal anastomosis. *Clin Transplant* 2006; 20:551-62.