

Tumour seeding following percutaneous needle biopsy of hepatocellular carcinoma

Qua C S, Wong C H, Goh K L

ABSTRACT

We report a hepatocellular carcinoma seeding following needle biopsy in a 57-year-old man who first presented with a focal hepatic lesion at another hospital. The patient had been a hepatitis B carrier for 20 years. Initial surveillance ultrasonography showed a lesion in segment IV, in the background of non-cirrhotic liver and normal serum alpha-fetoprotein level (8 ng/ml). A percutaneous needle biopsy was done and histopathology confirmed well-differentiated hepatocellular carcinoma. The patient had refused surgery and preferred to try traditional medicine. He presented to us four months after the initial biopsy with epigastric swelling. This was found to be due to a tumour seeding along the previous biopsy tract. He was given radiofrequency ablation (RFA) of tumour along the needle tract, in addition to the primary tumour. We conclude that the need for percutaneous needle biopsy should be critically evaluated in patients presenting with focal hepatic lesions and the role of RFA in treating tumour seeding needs further evaluation.

Keywords: hepatocellular carcinoma, percutaneous needle biopsy, radiofrequency ablation, tumour seeding

Singapore Med J 2008; 49(1): e8-e11

INTRODUCTION

Percutaneous needle biopsies, performed under ultrasonography (US) or computed tomography (CT) guidance, have been increasingly used in the diagnostic work-up of focal hepatic lesions. These procedures are generally safe, although serious complications have been reported, including needle tract seeding. Although previous studies reported a very low incidence (0.005%) of tumour seeding following percutaneous needle biopsies,⁽¹⁾ there is little data on the risks of tumour seeding following needle biopsies of focal hepatic lesions. We report hepatocellular carcinoma (HCC) tumour seeding following needle biopsy

in a 57-year-old man who initially presented with a focal hepatic lesion at another hospital. As the patient had refused surgery, he was given radiofrequency ablation (RFA) of tumour along the needle tract in addition to the primary tumour.

CASE REPORT

A 57-year-old Chinese man presented with right subcostal swelling four months after undergoing US-guided fine needle biopsy of a focal hepatic lesion. He was known to be a hepatitis B carrier for 20 years and a surveillance US showed a focal hepatic lesion in segment IV, in the background of non-cirrhotic liver and normal serum alpha-fetoprotein (AFP) level (8 ng/ml). He was a non-drinker and there was no family history of chronic hepatitis B or HCC. A fine-needle biopsy was performed under US guidance, with subsequent histology confirming well-differentiated HCC. The patient was offered surgery but he turned it down because he preferred to try traditional medicine. He presented to us four months after the biopsy with a swelling over the anterior abdominal wall below the right subcostal margin, where the previous biopsy site was located.

Physical examination revealed right subcostal swelling with erythematous overlying skin and mild tenderness (Fig. 1). CT of the abdomen showed tumour seeding along the previous needle biopsy tract, extending from the primary

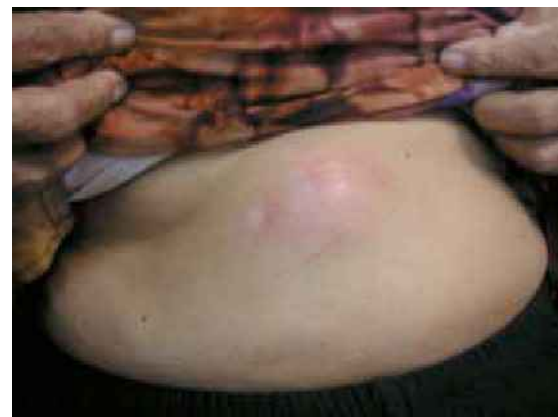

Fig. 1 Clinical photograph shows epigastric swelling with erythematous overlying skin.

Division of
Gastroenterology,
Department of
Medicine,
University of Malaya,
Lembah Pantai,
Kuala Lumpur 50503,
Malaysia

Qua CS, MMed, MRCP
Lecturer

Wong CH, MMed,
MRCP
Lecturer

Goh KL, FRCP, MD,
FACG
Senior Consultant

Correspondence to:
Dr Qua Choon-Seng
Tel: (60) 3 7949 2867
Fax: (60) 3 7960 4190
Email: csqua1@tm.net.my

tumour to the skin (Fig. 2). Repeated serum AFP was mildly raised (26 ng/ml). As the patient had refused surgery earlier, he was offered RFA of the needle tract tumour together with the primary tumour. This was done under conscious sedation using cooled-tip needle (Radionics, Burlington, MA, USA) under US-guidance via a percutaneous subxiphoid puncture. The needle tract tumour and the primary tumour were accessed through separate puncture sites and at the end of each procedure, the puncture tracts were ablated up to the skin surface with radiofrequency (RF). The entire procedure lasted about 30 minutes. The patient tolerated the procedure well with mild pain at the puncture site and was discharged two days later. Unfortunately, the patient did not turn up for follow-up one month later, where a repeat triple-phase CT was scheduled to assess the success of treatment following RFA and to locate any further new lesions or tumour seedings.

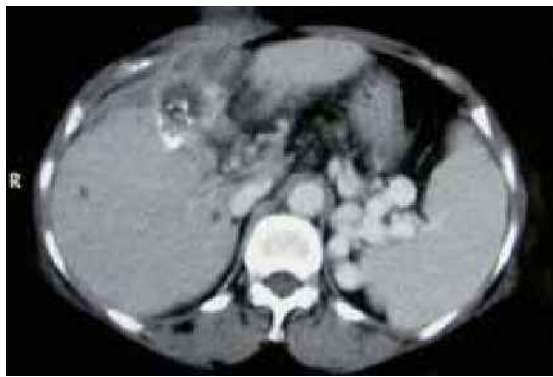


Fig. 2 Axial CT image shows tumour implantation along previous needle biopsy tract, extending from the primary tumour to the skin.

DISCUSSION

The advent and availability of modern imaging techniques have resulted in many hepatic lesions being increasingly recognised, sometimes incidentally. Many of these lesions pose a diagnostic challenge to clinicians as the nature of these tumours cannot be reliably ascertained despite imaging techniques (US, CT and magnetic resonance (MR) imaging) and blood investigations (serum AFP, hepatitis screening). As such, percutaneous fine-needle biopsy performed under US or CT guidance has become an important tool in helping the clinician overcome this dilemma. This diagnostic modality has been proven to be a generally safe procedure, although complications such as bleeding, biliary leak, pneumothorax and needle tract seeding have been reported.⁽²⁾ In the context of hepatic lesions, the risk of needle tract seeding following percutaneous biopsy of lesions, which may turn out to be HCC should be borne in mind as this may render subsequent surgery difficult or impossible.

The incidence of tumour implantation following fine-needle diagnostic procedures has been estimated to be less than 1/10,000.⁽¹⁾ This study included a large series of biopsies of many different organs performed for a variety of reasons (neoplastic and non-neoplastic). To date, there has been little data (less than 30 case reports) on the risk of tumour seeding following percutaneous needle biopsies of HCC. The incidence of this rare but serious complication is estimated to be 0.5%–2%,⁽³⁾ but this figure is likely to be higher as many cases are probably not reported.

In view of the risk of tumour seeding following percutaneous needle biopsies of HCC, many authors caution its use, especially if surgery is an option. A thorough clinical evaluation assessing the risks factors for HCC, such as history of alcohol intake and oral contraceptive use, screening for hepatitis B and C viruses, serum AFP levels, tumour markers (to differentiate between primary and metastatic liver lesions), appropriate imaging techniques (US, CT and MR imaging) are mandatory as initial diagnostic work-up. Only when a definitive diagnosis cannot be reliably made following initial careful assessment should a percutaneous biopsy be considered. The diagnosis of HCC is usually straightforward in the setting of cirrhosis, high level of serum AFP level coupled with abnormal imaging results. The usual practice in our hospital following abnormal ultrasound during surveillance, would be further imaging using triphasic CT to demonstrate hypervascularisation during arterial phase or MR imaging, to confirm the diagnosis of HCC. Liver biopsy is only considered when imaging results are inconclusive and no definitive surgical intervention is planned.

As our patient had liver biopsy performed at another hospital, we were unable to provide details regarding the location and size of the primary lesion, results of other investigations (if any) prior to the biopsy and the technical aspects related to the liver biopsy (e.g., type/size of biopsy needle, number of passes). The risks of tumour seeding following percutaneous biopsy is related to the size of biopsy needle,⁽¹⁾ number of passes,⁽¹⁾ superficial location of the tumour, intrinsic metastatic property of the tumour⁽⁴⁾ and patients' immunosuppression.⁽⁵⁾ Recently, the coaxial cutting needle technique had shown promising results with no tumour seeding reported in 128 patients with biopsy-proven HCC.⁽⁶⁾ This is not widely used by our radiologists (who performed all imaging-guided liver biopsies) yet, but may change in the future when more data is available.

We postulated that there probably were diagnostic uncertainties surrounding the nature of the hepatic lesion which prompted the needle biopsy, since apart from being a hepatitis B carrier, other parameters (normal serum AFP

level, non-cirrhotic liver) were not helpful. One possible reason could be due to the size of the original lesion being less than 2 cm with inconclusive imaging results, whereby there is still a role for liver biopsy,⁽⁷⁾ although this option should be thoroughly evaluated as this patient had no other significant comorbidity and therefore a potential candidate for surgery. An alternative strategy in a situation like this would be to repeat US every three months to detect any increase in size of the lesion, and then subject the patient to further imaging techniques in case of lesion growth. For lesions above 2 cm, most imaging techniques can confidently establish the diagnosis, even in patients with a normal serum AFP level.

Continued refinement of current imaging techniques is expected to result in even less need for liver biopsy as the nature of many hepatic lesions can be ascertained. These include multidetector CT, second generation contrast-enhanced US and dynamic MR imaging. Real-time contrast-enhanced US was found to have high sensitivity and specificity in diagnosing HCC, even in non-cirrhotic patients.⁽⁸⁾ There is also evolving data on the usefulness of new MR imaging contrast agents (such as superparamagnetic iron oxide, gadobenate dimeglumine) with improved characterisation of focal liver lesions.⁽⁹⁻¹¹⁾

The reported time taken for tumour implantation to occur ranged from three weeks to 48 months after the initial lesion was biopsied,⁽¹²⁾ in our patient, it appeared about four months after the biopsy. The treatment of needle tract implantation of HCC has not been clearly established. Surgical resections were reported in many cases, other treatment modalities included local radiotherapy⁽¹³⁾ and RFA of the tumour seeding.⁽¹⁴⁾ Surgical resection of implanted tumour appeared to be the preferred option, with reported survival of up to three years in the series by Takamori et al⁽¹²⁾ and five years in the series by Liu et al,⁽¹⁵⁾ following surgery for tumour implantation.

RFA has been increasingly used in recent years for the treatment of early HCC,⁽⁷⁾ but its role in the treatment of needle tract seeding has yet to be established, as it is also associated with a small risk of tumour seeding. Earlier studies by Llovet et al⁽¹⁶⁾ reported an alarmingly high rate (12.5%) of tumour seeding following RFA, but later studies reported substantially lower rates.⁽¹⁷⁻¹⁹⁾ This discrepancy is thought to be due to the small sample size of the study by Llovet et al (32 patients) and the use of needle biopsy before RFA in all patients in that study. The use of previous needle biopsy has been recognised as a risk factor for needle tract seeding following RFA,⁽¹⁶⁾ other predisposing factors include subcapsular location of tumour, high serum AFP level and poorly differentiated grade of HCC.^(20,21)

For our patient, as he had previously refused surgery and was still not keen for surgery, he was offered RFA of the needle tract tumour together with the primary tumour. Although this procedure is also associated with a low risk of tumour seeding, it is generally safe and well-tolerated, hence appears promising as a therapeutic option for needle tract seeding. This has yet to be confirmed through further studies involving more subjects. Needle tract seeding is a rare but serious complication following percutaneous biopsy of HCC. This procedure should only be considered when careful history-taking, imaging techniques and blood investigations fail to provide a definitive diagnosis. The need for percutaneous needle biopsy should be critically evaluated, especially if surgery is an acceptable option.

REFERENCES

- Smith EH. The hazards of fine-needle aspiration biopsy. *Ultrasound Med Biol* 1984; 10:629-34.
- Ferucci JT, Wittenberg J, Margoliese MN, Carey RW. Malignant seeding of the tract after thin-needle aspiration biopsy. *Radiology* 1979; 130:345-6.
- Durand F, Regimbeau JM, Belghiti J, et al. Assessment of the benefits and risks of percutaneous biopsy before surgical resection of hepatocellular carcinoma. *J Hepatol* 2001; 35:254-8.
- Goletti O, Chiarugi M, Bucciatti P, Macchiarini P. Subcutaneous implantation of liver metastasis after fine needle biopsy. *Eur J Surg Oncol* 1992; 18:636-7.
- Shimada M, Maeda T, Saitoh A, Morotomi I, Kano T. Needle track seeding after percutaneous ethanol injection therapy for small hepatocellular carcinoma. *J Surg Oncol* 1995; 58:278-81.
- Maturen K, Nghiem H, Marrero J, et al. Lack of tumor seeding of hepatocellular carcinoma after percutaneous needle biopsy using coaxial cutting needle technique. *Am J Roentgenol* 2006; 187: 1184-7.
- Bruix J, Sherman M, Llovet JM, et al. Clinical management of hepatocellular carcinoma. Conclusions of the Barcelona-2000 EASL conference. European Association for the Study of the Liver. *J Hepatol* 2001; 35:421-30.
- Celli N, Gaiani S, Piscaglia F, et al. Characterization of liver lesions by real-time contrast-enhanced ultrasonography. *Eur J Gastroenterol Hepatol* 2007; 19:3-14.
- Yamashita Y, Hatanaka Y, Yamamoto H, et al. Differential diagnosis of focal liver lesions: role of spin-echo and contrast-enhanced dynamic MR imaging. *Radiology* 1994; 193:59-65.
- Hamm B, Thoeni RF, Gould RG, et al. Focal liver lesions: characterization with nonenhanced and dynamic contrast material-enhanced MR imaging. *Radiology* 1994; 190:417-23.
- Kim YK, Kim CS, Lee YH, Kwak HS, Lee JM. Comparison of superparamagnetic iron oxide-enhanced and gadobenate dimeglumine-enhanced dynamic MRI for detection of small hepatocellular carcinomas. *Am J Roentgenol* 2004; 182:1217-23.
- Takamori R, Wong LL, Dang C, Wong L. Needle-tract implantation from hepatocellular cancer: Is needle biopsy of the liver always necessary? *Liver Transpl* 2000; 6:67-72.
- Ishii H, Okada S, Okusaka T, et al. Needle tract implantation of hepatocellular carcinoma after percutaneous ethanol injection. *Cancer* 1998; 82:1638-42.
- Espinoza S, Briggs P, Duret JS, Lapeyre M, de Baere T. Radiofrequency ablation of needle tract seeding in hepatocellular carcinoma. *J Vasc Interv Radiol* 2005; 16:743-6.
- Liu YW, Chen CL, Chen YS, et al. Needle tract implantation of hepatocellular carcinoma after fine needle biopsy. *Dig Dis Sci* 2007; 52:228-31.
- Llovet JM, Vilana R, Bru C, et al. Increased risk of tumour seeding

- after percutaneous radiofrequency ablation for single hepatocellular carcinoma. *Hepatology* 2001; 33:1124-9.
17. de Baere T, Risse O, Kuooh V, et al. Adverse effects during radiofrequency treatment of 582 hepatic tumours. *Am J Roentgenol* 2003; 181:695-700.
18. Poon RT, Ng KK, Lam CM, et al. Radiofrequency ablation for subcapsular hepatocellular carcinoma. *Ann Surg Oncol* 2004; 11:281-9.
19. Livraghi T, Lazzaroni S, Meloni F, Solbiati L. Risk of tumour seeding after percutaneous radiofrequency ablation for hepatocellular carcinoma. *Br J Surg* 2005; 92:856-8.
20. Hori T, Nagata K, Hasuike S, et al. Risk factors for the local recurrence of hepatocellular carcinoma after a single session of percutaneous radiofrequency ablation. *J Gastroenterol* 2003; 38:977-81.
21. Kato T, Reddy KR. Radiofrequency ablation for hepatocellular carcinoma: help or hazard? *Hepatology* 2001;33:1336-7.