

Prosthetic valve thrombosis despite seemingly-adequate anticoagulation: the dangers of transient lapses in anticoagulation

Jafary F H, Hassan K

ABSTRACT

We report a 19-year-old woman with thrombosis of a prosthetic mitral valve that was most likely due to a short dip in anticoagulation in the days preceding the event. Interestingly, at presentation the patient was super-therapeutic, most likely a result of hepatic congestion as the heart began to fail, creating an illusion of thrombosis despite adequate anticoagulation.

Keywords: anticoagulation lapse, prosthetic valve thrombosis, valve thrombosis

Singapore Med J 2008; 49(1): e1-e2

INTRODUCTION

Metallic prosthetic valves are associated with an increased risk of thrombosis and subsequent embolism. The morbidity and mortality associated with prosthetic valve thrombosis (PVT) is substantial. This risk is significantly greater with valves in the mitral position, probably owing to lower velocities of blood flow. Meticulous anticoagulation with warfarin reduces this risk considerably to approximately 0.2 per patient-year.⁽¹⁾ Most cases of PVT reported in the literature are associated with consistently inadequate anticoagulation. However, there is no data on the dangers of transient lapses in the level of anticoagulation. We report on a case of PVT occurring three months after implantation with super-therapeutic anticoagulation at presentation, but a short "dip" in levels in the days preceding the event.

CASE REPORT

A 19-year-old woman underwent mitral valve replacement with a CarboMedics™ bileaflet mechanical valve for mitral regurgitation three months prior to admission. Her postoperative course was unremarkable and international normalised ratio (INR) at discharge was 3.2. 15 days prior to admission, her INR decreased to 1.9, following which the dose of warfarin was increased. Five days prior to admission, she developed progressively worsening

dyspnoea. Physical examination revealed her to be afebrile and in florid pulmonary oedema. The prosthetic mitral valve sounds were considerably muffled. White blood cell counts and subsequent blood cultures were unremarkable.

Transthoracic echocardiography revealed a transmitral gradient of 28 mmHg with trivial mitral regurgitation.

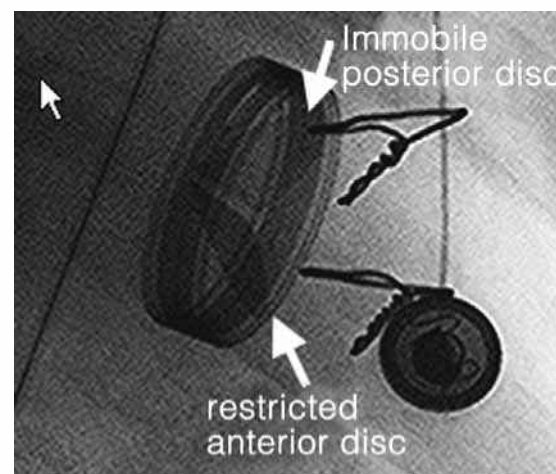


Fig. 1 Fluoroscopic image of mitral valve shows immobile and restricted leaflets.

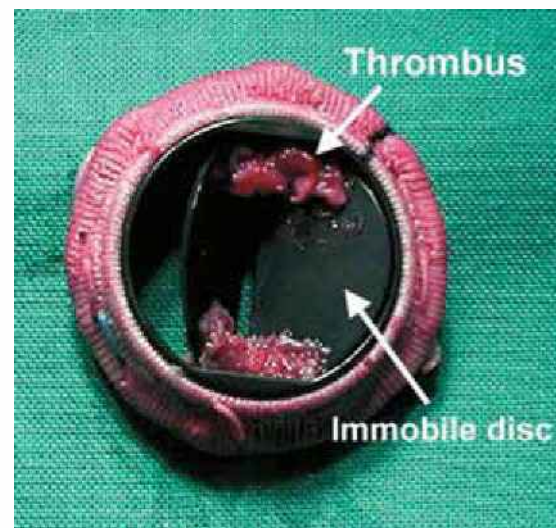

Fig. 2 Photograph shows the excised mitral valve laden with thrombus.

Department of
Medicine,
Section of Cardiology,
Aga Khan University
Hospital,
PO Box 3500,
Stadium Road,
Karachi 74800,
Pakistan.

Jafary FH, MD, FACC
Associate Professor

Hassan K, MBBS, FCPS
Honorary Lecturer

Correspondence to:
Dr Fahim H Jafary
Tel: (92) 21 486 4700
Fax: (92) 21 493 4294
Email: jafary@pobox.com

A transoesophageal echocardiogram (TEE) confirmed the above findings and suggested that the posterior mitral valve disc was immobile. No vegetations were seen. At fluoroscopy, the anterior disc was noted to have limited excursion and the posterior disc was immobile (Fig. 1). One day prior to admission, the patient's INR was 4.6. The patient underwent emergency replacement of her mitral valve, this time with a bioprosthesis. Perioperatively, the valve was laden with thrombus with severe restriction of both discs (Fig. 2). She has remained well since.

DISCUSSION

Thrombosis is an uncommon yet serious complication after valve replacement with a mechanical prosthesis. The clinical presentation can range from subtle embolic events to florid pulmonary oedema and cardiogenic shock. PVT should be suspected with any deterioration in clinical status or with thromboembolic complications. TEE and fluoroscopy can reliably evaluate leaflet mobility and help in diagnosis as well as follow-up of response to treatment.⁽²⁾ Therapy includes infusion of a thrombolytic agent for 27–72 hours, with or without heparin, and aspirin⁽³⁾ or surgery.⁽⁴⁾ Long-term anticoagulation is recommended in all patients to prevent PVT. The American Heart Association and the American College of Cardiology advocates an INR of 2.5–3.0 for bileaflet mechanical valves in the mitral position.⁽⁵⁾

The majority of patients with PVT that have been reported in the literature were attributed to inadequate anticoagulation. A more difficult question to answer is whether the duration of subtherapeutic anticoagulation that can lead to thrombosis is a continuous variable or has a critical “cut-off” value. In our patient, the relatively

suboptimal anticoagulation 15 days prior to admission (INR 1.9) may have resulted in a nidus of thrombus forming on the valve, eventually culminating in valve thrombosis. The super-therapeutic levels of anticoagulation observed at presentation may simply have been a consequence of hepatic congestion secondary to a failing heart, providing the illusion that this patient developed PVT despite being well-anticoagulated. Although not formally worked up, there was no prior history of any hypercoagulable state. It is unclear why our patient's anticoagulation levels dropped initially. As far as we can ascertain, there were no interacting drugs in her history nor was there an obvious dietary cause.

In conclusion, PVT can occur as a consequence of transient dips in anticoagulation level. This case highlights the dangers of failing to maintain adequate anticoagulation in patients with metallic prosthetic valves, even for relatively short durations. This is particularly true for developing countries where rheumatic valvular heart disease is very common and meticulous anticoagulation is logistically difficult.

REFERENCES

1. Chesebro JH, Fuster V. Valvular heart disease and prosthetic heart valves. In: Verstraete M, ed. *Thrombosis in Cardiovascular Disorders*. Philadelphia: WB Saunders, 1992:191-214.
2. Silber H, Khan SS, Matloff JM, et al. The St. Jude valve. Thrombolysis as the first line of therapy for cardiac valve thrombosis. *Circulation* 1993; 87:30-7.
3. Birdi I, Angelini GD, Bryan AJ. Thrombolytic therapy for left sided prosthetic heart valve thrombosis. *J Heart Valve Dis* 1995; 4:154-9.
4. Ezekowitz MD. Anticoagulation management of valve replacement patients. *J Heart Valve Dis* 2002; 11 Suppl 1:S56-60.
5. Bonow RO, Carabello B, de Leon AC Jr, et al. Guidelines for the management of patients with valvular heart disease: executive summary. A report of the American College of Cardiology/American Heart Association Task Force on Practice Guidelines (Committee on Management of Patients with Valvular Heart Disease). *Circulation* 1998; 98:1949-84.