

Spontaneous bilateral quadriceps tendon rupture

Vigneswaran N, Lee K, Yegappan M

ABSTRACT

Spontaneous bilateral quadriceps tendon ruptures are uncommon. We present a 30-year-old man with end-stage renal failure, who sustained this injury, and subsequently had surgical repair of both tendons on separate occasions. He has since regained full range of movement of both knees.

Keywords: end-stage renal failure, quadriceps rupture, spontaneous tendon rupture, tendon injury

Singapore Med J 2007; 48(11):1051–1054

INTRODUCTION

Traumatic tendon ruptures are common; however, spontaneous ruptures are not. The Achilles and patellar tendons are two of the commoner sites of reported ruptures. Bilateral spontaneous quadriceps tendon rupture is a very rare occurrence. We report a young man who sustained bilateral spontaneous quadriceps tendon rupture and underwent surgical repair of both tendons, with each surgery conducted about six weeks apart.

CASE REPORT

The patient is a 30-year-old Chinese man with renal failure secondary to glomerulonephritis. He has been on haemodialysis since 2000, and undergoes the procedure three times per week. Over the last few months prior to presentation, his intact parathyroid hormone (iPTH) levels increased from 150 to 170 pmol/L. He was admitted to the orthopaedic ward for left knee injury in January 2006. He had sustained this injury while climbing up the stairs to his home, when his left knee gave way. There were no other injuries. This patient had a similar incident involving his right knee about three weeks prior to this episode. He was still able to partially bear weight and ambulate. On admission, his right knee was weak and painful. Examination of his left knee showed a passive range of movement of 5–30 degrees, which was limited due to pain. There was effusion of the knee joint, with two separate bulges over the medial aspect of the knee joint and the lateral suprapatellar area, which were palpable.

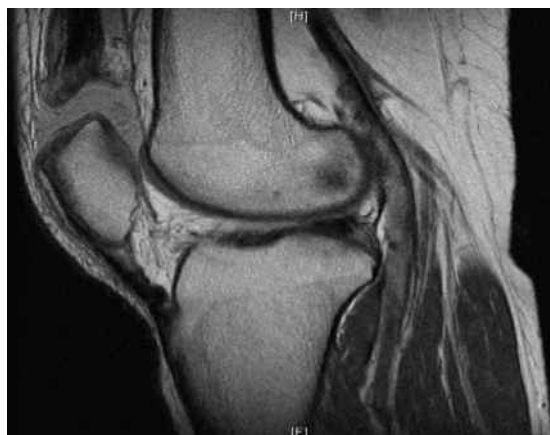

Fig. 1 Sagittal PD-W MR image of the left knee shows a complete tear of the quadriceps tendon.

Radiograph of his left knee showed no evidence of fracture, forward tilting or low-lying patella, calcification or soft tissue defects. The patient was initially treated with a therapeutic knee aspiration followed by bed rest, analgesia and physiotherapy. However, he still was unable to perform exercises during physiotherapy due to severe pain. Magnetic resonance (MR) imaging showed a complete tear of the left quadriceps tendon (Fig. 1) with haemarthrosis, tear of the joint capsule laterally, atrophy of the vastus lateralis, and a tear in the anterior horn of the lateral meniscus.

Quadriceps tendon repair was carried out for the left knee. The intraoperative findings were a transverse complete tear of the left quadriceps tendon at the upper border of patella, extending into the retinaculum on both sides. Both the quadriceps tendon and the upper border of patella were debrided and curetted, then washed (Fig. 2a). The retinaculum was repaired with vicryl 1/0 while the quadriceps was apposed to 70 degrees of flexion and tied with Mitek sutures onto the patella. Mitek sutures were anchored into three holes drilled on the superior surface of the patella (Fig. 2b). These were then reinforced with the remnant epitendinous sutures. A backslab was then placed for the left lower limb postoperatively.

MR imaging was subsequently performed for the other knee, showing a complete tear of the right quadriceps tendon with subchondral bone marrow oedema and an overlying chondral defect involving

**Department of
Orthopaedic
Surgery,
Tan Tock Seng
Hospital,
11 Jalan Tan
Tock Seng,
Singapore 308433**

Vigneswaran N,
MBBCh, BAO
House Officer

Lee K, MBBS,
MMed, MRCSE
Registrar

Yegappan M, MBBS,
FRCSE, FRCGS
Consultant

Correspondence to:
Dr Vigneswaran N
Tel: (65) 6357 7714
Fax: (65) 6357 7715
Email: vigneswaran_nallathamby@yahoo.com

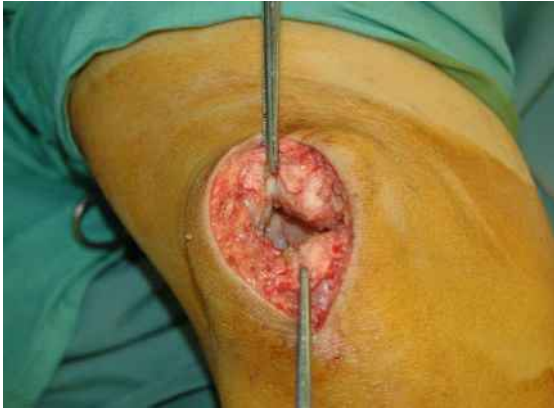


Fig. 2a Operative photograph shows the distal quadriceps tendon after debridement.

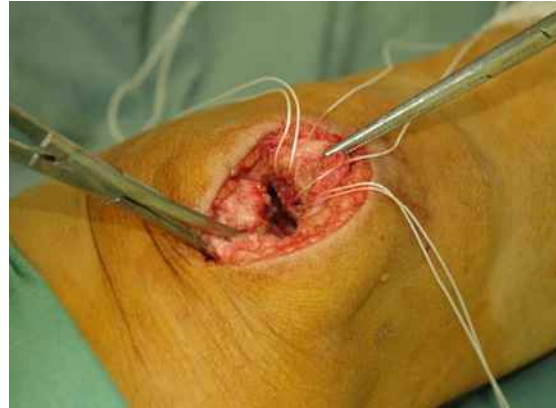


Fig. 2b Operative photograph of the left knee shows Mitek sutures in place between the distal quadriceps tendon and the superior patella.

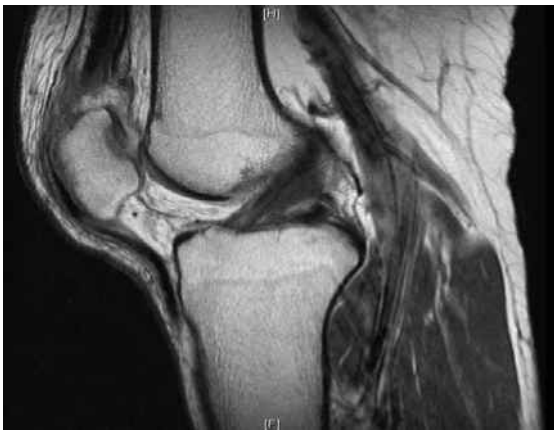

Fig. 3 Sagittal PD-W MR image of the right knee shows a complete tear of the quadriceps tendon and an anterior cruciate ligament strain.

the patellar apex (Fig. 3). A right patellar tendon and anterior cruciate ligament strain with a possible tear involving the anterior horn of the right lateral meniscus was also found.

The decision was made to postpone any intervention to the right knee to a later date, to allow time for the operated left knee to recover. If both knees were to be operated on at the same admission, the patient's recovery may have been stunted and there was a high possibility that he would have developed stiffness in both knees. The patient started physiotherapy on the second postoperative day. He was fitted with a knee brace and allowed to do weight-bearing exercises with an active range of motion of 0–60 degrees. Upon discharge, he could manage weight-bearing ambulation with crutches and negotiate the stairs.

As the patient's recovery was good, he was admitted approximately six weeks later for the repair of his right quadriceps tendon. The operation went well and

similarly, three Mitek sutures were used to repair the tendon. Intraoperative findings were fibrous tissue bridging the torn tendon. The patient was discharged the next day to continue physiotherapy at home. On follow-up, the patient could eventually perform a full range of movements with both knees, by eight weeks postoperation (Fig. 4). The patient's latest iPTH level was 186.1 pmol/L, and he was scheduled to consult an endocrinologist.

DISCUSSION

Rupture of tendons is not all that uncommon. There is considerable literature on the traumatic rupture of tendons. However, rupture of the quadriceps tendon is rare, and especially so if it is spontaneous and bilateral. In a retrospective study, it was found that this rare injury occurs more in males and more so on the non-dominant limb.⁽¹⁾ Tendinopathy is known to contribute to the rupture of tendons, be it spontaneous or traumatic. There are numerous contributing factors highlighted in the literature, the commonest being the existing comorbidity of chronic renal failure requiring dialysis.⁽²⁻⁴⁾ For these patients, malnutrition, insufficient dialysis, amyloidosis, chronic acidosis or hyperparathyroidism, are suspected to contribute to the pathogenesis of tendon rupture.⁽⁴⁾ However, the mechanism leading to tendinopathy is still a mystery.

Shioto et al deduced that the most likely aetiology of five patients on haemodialysis and who suffered spontaneous tendon ruptures, was secondary hyperparathyroidism, which caused fragility of the bone at the tendon insertion site.⁽⁵⁾ In a case study by Ryuzaki et al, histological examination of tendons suggested that repeated minor avulsion fractures of the bone cortex at the tendon insertion site preceded the final total tendon rupture, and the osteitis fibrosa

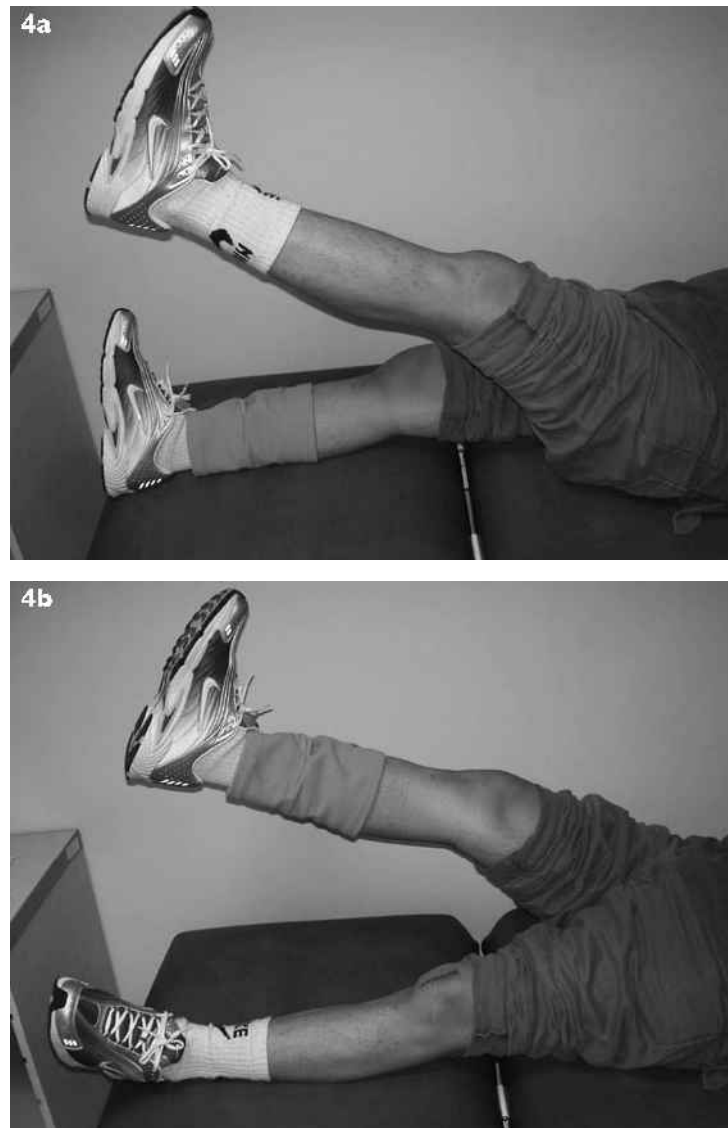


Fig. 4 Clinical photographs show that the patient had full range of movements of both knees, particularly extension, at eight weeks postoperation.

was responsible for these minor fractures.⁽⁶⁾ Secondary hyperparathyroidism causes dystrophic calcifications and subperiosteal bone resorption, which weakens the osseotendineous junction.^(7,8) Bony erosions were observed at tendon insertion sites in all six patients who presented with spontaneous tendon rupture, out of 169 who were undergoing haemodialysis.⁽⁹⁾ These six patients had raised PTH levels. This is similar to our presented case.

Obesity causes fatty changes in the tendons and, with the excess burden load, places greater stress on the knees when flexed.^(8,10) A meta-analysis of the literature on tendon ruptures concluded that younger patients have a tendency to sustain spontaneous tendon ruptures and are the ones who usually have

contributing factors of end-stage renal failure on dialysis, diabetes mellitus, hyperparathyroidism, obesity, systemic lupus erythematosis, steroid usage, alkaptonuria or gout.⁽¹¹⁻¹⁶⁾ The duration of dialysis was thought to be related to the spontaneous tendon ruptures.⁽⁸⁾ Chronic acidaemia associated with chronic renal disease causes degeneration of tendons, and the structure of the protein polysaccharide complex, which is responsible for the maturation of collagen.⁽⁸⁾ In this meta-analysis, all but one were treated surgically, and of those treated, 57% of patients enjoyed a good outcome on follow-up.

Imaging is usually the key to obtaining the diagnosis. MR imaging is very useful in these cases. However, ultrasonography may be a cheap, reliable

way to diagnose tendon ruptures, but it is operator-dependent.⁽¹⁷⁾ The treatment method was to attach the ruptured tendons onto the patella by passing sutures through tunnels drilled into the superior patella.⁽¹⁸⁾ However, for this patient, the sutures were attached into holes drilled into the superior patella. In conclusion, patients who present with knee pain and swelling, and with the inability to fully extend the knee, should be suspected of having a tendon rupture. There should be a high index of suspicion if the patient suffers from comorbidities, such as chronic renal impairment on dialysis. MR imaging was used to make the diagnosis and surgery provided an excellent outcome for our patient.

REFERENCES

- O'Shea K, Kenny P, Donovan J, Condon F, McElwain JP. Outcomes following quadriceps tendon ruptures. *Injury* 2002; 33:257-60.
- Kim YH, Shafi M, Lee YS, et al. Spontaneous and simultaneous rupture of both quadriceps tendons in a patient with chronic renal failure. A case studied by MRI both preoperatively and postoperatively. *Knee Surg Sports Traumatol Arthrosc* 2006; 14:55-9.
- De Franco P, Varghese J, Brown WW, Bastani B. Secondary hyperparathyroidism, and not beta 2-microglobulin amyloid, as a cause of spontaneous tendon rupture in patients on chronic hemodialysis. *Am J Kidney Dis* 1994; 24:951-5.
- Jones N, Kjellstrand CM. Spontaneous tendon ruptures in patients on chronic dialysis. *Am J Kidney Dis* 1997; 29:982.
- Shiota E, Tsuchiya K, Yamaoka K, Kawano O. Spontaneous major tendon ruptures in patients receiving long-term hemodialysis. *Clin Orthop Relat Res* 2002; 394:236-42.
- Ryuzaki M, Konishi K, Kasuga A, et al. Spontaneous rupture of the quadriceps tendon in patients on maintenance hemodialysis – report of three cases with clinicopathological observations. *Clin Nephrol* 1989; 32:144-8.
- Ribbans WJ, Angus PD. Simultaneous bilateral rupture of the quadriceps tendon. *Br J Clin Pract* 1989; 43:122-5.
- Bhole R, Flynn JC, Marbury TC. Quadriceps tendon ruptures in uremia. *Clin Orthop Relat Res* 1985; 195:200-6.
- Meneghello A, Bertoli M. Tendon disease and adjacent bone erosion in dialysis patients. *Br J Radiol* 1983; 56:915-20.
- Julius AJ. Rupture of the quadriceps tendon. *Neth J Surg* 1984; 36:134-6.
- Shah MK. Simultaneous bilateral rupture of quadriceps tendons: analysis of risk factors and associations. *South Med J* 2002; 95:860-6.
- Firooznia H, Seliger G, Abrams R, Sanz M. Bilateral spontaneous and simultaneous rupture of the quadriceps tendon. *Bull Hosp Joint Dis* 1973; 34:65-9.
- Lotem M, Berheim J, Conforty B. Spontaneous rupture of tendons. A complication of hemodialyzed patients treated for renal failure. *Nephron* 1978; 21:201-8.
- Novoa D, Romero R, Forteza J. Spontaneous bilateral rupture of the quadriceps tendon in uremia and kidney transplantation. *Clin Nephrol* 1987; 27:48.
- Preston FS, Adicoff A. Hyperparathyroidism with avulsion of three major tendons. Report of a case. *N Engl J Med* 1962; 266:968-71.
- Stern RE, Harwin SF. Spontaneous and simultaneous rupture of both quadriceps tendons. *Clin Orthop Relat Res* 1980; 147:188-9.
- Kålebo P, Allenmark C, Peterson L, Swärd L. Diagnostic value of ultrasonography in partial ruptures of the Achilles tendon. *Am J Sports Med* 1992; 20:378-81.
- Richards DP, Barber FA. Repair of quadriceps tendon ruptures using suture anchors. *Arthroscopy* 2002; 18:556-9.



Looking to hit that sales target?

Advertise with the **Singapore Medical Journal**.

The voice of academic medicine in Singapore and Southeast Asia since 1960

To advertise, please contact: **Li Li Loy**, Advertising Executive
 Mobile: **9634 9506** Tel: **6223 1264 ext 23** Email: **lili@sma.org.sg**