

Nimesulide-induced hepatotoxicity and fatal hepatic failure

Tan H H, Ong W M C, Lai S H, Chow W C

ABSTRACT

Non-steroidal anti-inflammatory drugs (NSAIDs) and cyclo-oxygenase-2 (cox-2) inhibitors are structurally heterogeneous drugs that share similar therapeutic actions and adverse effects. Hepatotoxicity, although a relatively rare adverse effect of this class of drugs, can be severe. This has led to the withdrawal of some NSAIDs from the market. Nimesulide is an NSAID, with cox-2 preference, which has been reported to cause death from hepatic failure. However, most reports have been from European countries. Asian reports include that from Israel and India. We report three patients who presented with acute hepatitis after being prescribed nimesulide, one of whom died from fulminant hepatic failure.

Keywords: acute hepatitis, cyclo-oxygenase inhibitors, fulminant hepatic failure, hepatotoxicity, nimesulide-induced hepatotoxicity, non-steroidal anti-inflammatory drugs

Singapore Med J 2007;48(6):582-585

INTRODUCTION

Nimesulide-induced hepatotoxicity was first reported in post-marketing surveillance studies.⁽¹⁾ Its presentation is varied, ranging from asymptomatic elevation of liver enzymes^(2,3) to death from hepatic failure.⁽⁴⁾ We report three patients who presented to our department in the year 2004 with acute onset of jaundice after the ingestion of nimesulide at therapeutic doses.

CASE REPORTS

In the year 2004, three Chinese adult patients presented to our department with acute onset of jaundice after having consumed nimesulide at different time intervals (Table I). All three patients were prescribed the drug for joint pains by their primary physicians, and were consuming the drug up to the time of their admission. Nimesulide was stopped upon admission of all three patients. None of the patients had prior drug allergies, atopy, blood transfusions nor significant alcohol intake. Patient 2 (female) had a history of intermittent intake

of traditional Chinese medication for three years prior to admission, but had stopped this at least six weeks prior to onset of symptoms. Patient 3 ingested nimesulide over a six-week period, where it was consumed daily for two weeks, interrupted for two weeks, then consumed again daily for two weeks. All patients were negative for acute viral hepatitis A, B, C, E, herpes simplex virus, Epstein-Barr virus, Cytomegalovirus and liver autoantibodies. Ultrasonography was normal and liver biochemistries were consistent with hepatocellular injury in all three patients. None of the patients had evidence of hypersensitivity, such as fever, rash nor significant hypereosinophilia. Patients 1 and 2 responded well to drug dechallenge, with a decline in liver enzymes and bilirubin levels. None of the patients were treated with steroids nor ursodeoxycholic acid. Patient 3, however, continued to deteriorate despite drug dechallenge, developing hepatic encephalopathy and hepatorenal syndrome. She did not improve despite a 72-hour trial of molecular adsorbent recirculating system (MARS) therapy and eventually demised. Liver histology was only available in patient 3, when an autopsy was performed upon her death. At autopsy, the liver was found to be cirrhotic. Microscopical examination showed regenerative nodules separated by fibrous bands, laden with a moderate mononuclear inflammatory infiltrate rich in lymphocytes admixed with some neutrophils and plasma cells. There was prominent cholestasis associated with biliary ductular proliferation. Within many of the nodules, hepatocellular necrosis were present. Interface and lobular inflammation were also present in other areas (Fig. 1). The features were those of acute hepatocellular injury occurring in a cirrhotic liver.

DISCUSSION

Nimesulide (4-nitro-2-phenoxyethanesulphonamide) is one of the newer classes of non-steroidal anti-inflammatory drugs (NSAIDs) with preferential cyclo-oxygenase-2 (cox-2) selectivity. Although not entirely unlike the newer cox-2 inhibitors (such as celecoxib, rofecoxib), which have 400- to 800-fold selectivity, nimesulide selectivity for cox-2 is in the order of 5- to 16-fold only.⁽⁵⁾ Nimesulide was first marketed in Italy in 1985 and has since then been launched in about 50 countries worldwide. The drug is currently off-patent and hence, is marketed

Department of Gastroenterology and Hepatology, Singapore General Hospital, Outram Road, Singapore 169608

Tan HH, MBBS, MRCP Registrar

Ong WMC, MBBS Medical Officer

Chow WC, MMed, MRCP, FAMS Senior Consultant

Centre for Forensic Medicine, Health Science Authority, Outram Road, Singapore 169078

Lai SH, MBBS, DMJ, MRCPATH Associate Consultant

Correspondence to: Dr Tan Hui-Hui
Tel: (65) 6321 4684
Fax: (65) 6227 3623
Email: mhyhui@singnet.com.sg

Table I. Summary of patient characteristics.

Characteristics	Patient 1	Patient 2	Patient 3
Age (years)	54	71	74
Gender	Male	Female	Female
Race	Chinese	Chinese	Chinese
Duration of nimesulide ingestion	19 days	Unknown	28 days (consumed over a 6-week period, with a 2-week interruption in between)
Drug consumed up to time of admission	Yes	Yes	Yes
Presenting complaint	Jaundice	Jaundice	Jaundice
Duration of jaundice prior to admission	1 days	14 days	2 days
Other symptoms (Duration preceding admission)	Nausea; dyspepsia (2 weeks)	None	Drowsiness (2 days)
Preceding concurrent drugs (all stopped prior to onset of symptoms)	Nil	TCM ^a	Diclofenac
Developed hepatic encephalopathy	No	No	Yes
Management	Dechallenge	Dechallenge	Dechallenge; MARS ^b
Peak bilirubin (umol/L) (time of occurrence from admission)	62 (Day 7)	53 (Day 9)	775 (Day 24)
Peak ALT ^c / AST ^d (xULN ^e) (time of occurrence from admission)	31 / 21 (Day 2)	27 / 26 (Day 6)	23 / 50 (Day 1)
Time from day of hospitalisation till resolution of liver function abnormalities	42 days	38 days	–
Outcome	Resolved	Resolved	Died

^a Traditional Chinese medication

^b Molecular adsorbent recirculating system

^c Alanine transferase

^d Aspartate transferase

^e Multiples of the upper limit of normal

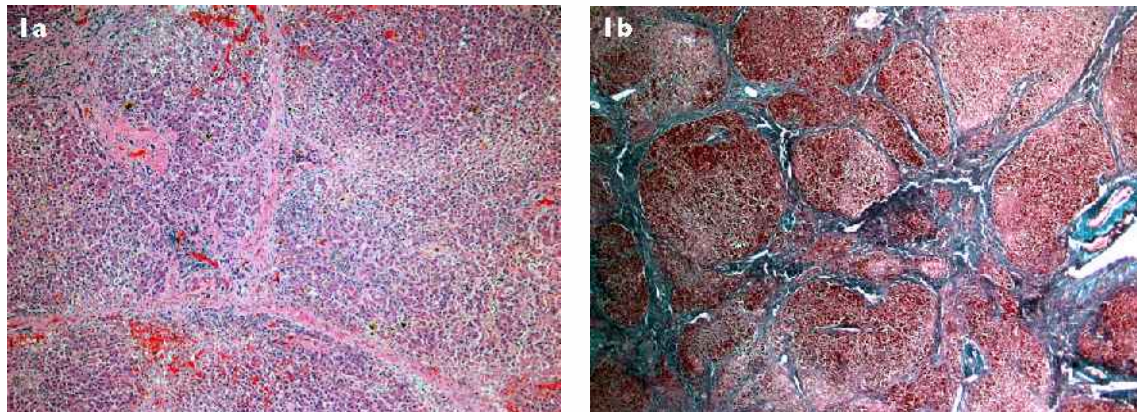


Fig. 1 Photomicrographs of the liver from patient 3 show (a) cirrhosis, foci of inflammation within the fibrous septa and lobules and areas of hepatocellular necrosis (Haematoxylin & eosin, $\times 5$); and (b) cirrhosis highlighted by special stains to accentuate cirrhosis of the liver (Masson's Trichrome, $\times 1.25$).

by a variety of firms.⁽⁶⁾ After its launch, various case reports of hepatotoxicity and even fatal hepatic failure caused some countries to re-examine the safety profile of the drug. This led to the withdrawal of the drug (temporary or otherwise) or a revision of product information in different countries. In Finland, for example, nimesulide-induced adverse effects reached more than 100 per

100,000 person years (the corresponding incidence for other NSAIDs was less than one per 100,000 person years), leading to the withdrawal of the drug in 2002. Spain followed suit soon after, within the same year.⁽⁷⁾ This prompted the European Union's Medical Products Evaluation Agency to issue a precautionary advice in 2004 on the use of the drug and its potential

complications. In Israel, the product information was revised to include a recommendation that liver function testing be done for patients every three weeks.⁽⁸⁾ Nimesulide has never been approved for use in countries like USA, UK, Canada, Australia and New Zealand in view of concerns over its safety profile. In Southeast Asia, the drug enjoys variable regulatory status. In Thailand, for example, only the tablet form of the drug is available; the suspension form has been withdrawn. In India, both tablet and gel forms have been available for about ten years.⁽⁶⁾ In Singapore, only the tablet and powder (sachet) forms are available and the drug is approved for the treatment of acute pain, painful osteoarthritis and primary dysmenorrhoea.

Nimesulide is rapidly and extensively absorbed in its oral form (tablets, granules or suspension) and it has a relatively short half-life in humans. This could account for the relatively fewer cases of severe gastrointestinal and renal toxicity reported.⁽⁹⁾ Nimesulide is mainly eliminated by metabolic transformation, via the cytochrome-P450 system, in the liver. Its principal metabolite is the 4'-hydroxy derivative. Excretion of the unchanged drug in the urine and faeces is negligible. Expectedly, hepatic insufficiency is known to have significant effects on its pharmacokinetic profile: the rate of elimination in such patients was markedly reduced when compared to that of healthy individuals.⁽¹⁰⁾

In the year 2004, the Pharmacovigilance unit of Health Sciences Authority of Singapore received a total of 1,139 voluntary adverse drug reaction reports.⁽¹¹⁾ There was a slight female preponderance with a female: male ratio of 1.5:1 (680 vs 448 reports). NSAIDs and antibiotics were the most commonly-reported culprit drugs, with the top two drugs being diclofenac and naproxen. When the reports were sorted by reaction-system classes, liver and biliary disorders were ranked 7th, constituting a total of 3.1% of adverse reactions. In the same year, it received three reports for nimesulide-induced adverse reactions. One patient was prescribed the drug for dysmenorrhoea while the other two were prescribed the drug for arthritic pains. Both the latter two patients presented with acute hepatitis. In the preceding year, 2003, it also received three reports for nimesulide-adverse reactions.

The severity of hepatotoxicity associated with NSAIDs is variable. Its clinicopathological spectrum spans from acute self-limited hepatitis, cholestasis, cholestatic hepatitis, hepatic granulomas to chronic hepatitis, chronic cholestasis with ductopenia and fulminant acute hepatic failure.^(4,12) Nimesulide has been linked to various cases of acute hepatitis, especially in women. Onset of symptoms varies between one and

15 weeks after ingestion, although a delay of up to eight months has been reported in one case report.⁽¹³⁾ Centrilobular or bridging necrosis and, occasionally, bland cholestasis have been reported on liver histology. Hypersensitivity features with peripheral eosinophilia have been reported, especially early during the onset of liver injury.⁽¹⁴⁾ Both immunological and idiosyncratic metabolic mechanisms have been implicated and it is likely that some reactions involve interaction between reactive metabolites and an immunological response as part of the reactive metabolite syndrome.⁽¹⁵⁾ Unfortunately, as with most drugs, detailed and informed mechanistic studies are lacking.⁽¹⁶⁾

Although gender has only been found to have a limited influence on the pharmacokinetic profiles of nimesulide and its metabolite, the same may not be true of its pattern of hepatic injury. In a case report of six cases of nimesulide-induced hepatotoxicity, van Steenberg et al reported on four female patients and two male patients, who developed acute hepatitis after initial treatment with nimesulide 200 mg per day.⁽¹⁴⁾ All six patients had liver biopsies performed. Interestingly, histology showed hepatocellular necrosis in all four female patients, while it demonstrated bland cholestasis in the remaining two male patients. In our series, liver histology for patient 3, a female, who had an autopsy performed, was compatible with that of acute hepatocellular injury in a cirrhotic liver. Although the same pattern of female preponderance for hepatocellular injury has been reported in other various isolated case reports, this gender-phenomenon is not well documented or studied. Perhaps, this is because liver biopsies are not commonly performed on patients who respond well to immediate drug dechallenge. A similar gender distribution between hepatocellular and cholestatic injuries has not been reported with any other NSAID.

Although fatal fulminant hepatic injury has been reported previously in patients on nimesulide, some of these fatalities have occurred in patients who either had pre-existing liver disease, other internal malignancies or in whom nimesulide was continued despite liver dysfunction. Caution against its use simultaneously with other NSAIDs has also been raised.^(1,14) While avoiding such potential fatalities might seem straightforward, the truth is never that easy. Firstly, because a portion of those deaths reported occurred in patients who were previously well and who had consumed the drug at therapeutic doses and, furthermore, were appropriately dechallenged at time of presentation. Secondly, our patient 3 highlights a common clinical problem; namely, that neither radiological imaging nor prior medical history could detect any evidence of her underlying hepatic cirrhosis. Cirrhosis was probably the reason

why she tolerated an insult to the liver less well than the other patients did. However, without such microscopic evidence, her primary physician would have assumed a normal liver at the time of his prescription of the drug. In real clinical situations, it may not always be easy to separate the potential “high-risk” group of patients from the “normal-risk” ones. This further underscores the importance of a thorough evaluation of patients. Restricting one’s history-taking and physical examination to only the primary complaint will further increase the risk of such complications. Ideally, patients on this drug should be monitored for liver and renal function (just as any other NSAIDs would predispose to such risks). However, there is no good evidence to suggest how frequent or prolonged such monitoring should be, nor if all patients (as opposed to “high-risk” patients only) on nimesulide should be monitored.

In conclusion, as with all other NSAIDs or COX-2 inhibitors, we caution against the prolonged use of nimesulide, especially in the elderly. The drug should not be used in patients with hepatic insufficiency nor concurrently with other NSAIDs. Doctors should be aware, when prescribing nimesulide, that hepatotoxicity is one of the adverse reactions of this drug and that this is potentially fatal.

REFERENCES

- Rainsford KD. An analysis from clinico-epidemiological data of the principal adverse events from the COX-2 selective NSAID, nimesulide, with particular reference to hepatic injury. *Inflammopharmacology* 1998; 6:203-21.
- Pasquale G, Scarcabarozzi I, D’Agostino R, Tadorelli G, Vallarino R. An assessment of the efficacy and tolerability of nimesulide vs paracetamol in children after adenotonsillectomy. *Drugs* 1993; 46 suppl 1:234-7.
- Fossaluzza V, Montagnani G. Efficacy and tolerability of nimesulide in elderly patients with osteoarthritis: double-blind trial versus naproxen. *J Int Med Res* 1989; 17:295-303.
- McCormick PA, Kennedy F, Curry M, Traynor O. COX-2 inhibitor and fulminant hepatic failure. *Lancet* 1999; 353:40-1. Comment in: *Lancet* 1999; 353:1447-8. *Lancet* 1999; 353:846.
- Hawkey CJ. COX-2 inhibitors. *Lancet* 1999; 353:307-14. Comment in: *Lancet* 1999; 353:1439-40.
- Drugs of current interest: nimesulide. *WHO Pharmaceuticals Newsletter* 2002; 4:12.
- Traversa G, Bianchi C, Da Cas R, et al. Cohort study of hepatotoxicity associated with nimesulide and other non-steroidal anti-inflammatory drugs. *BMJ* 2003; 327:18-22. Comment in: *BMJ* 2003; 327:1050-1.
- Elmaleh E. Nimesulide, clavulanic acid and hepatitis (letter). *J Int Med* 2000; 248:168. Comment on: *J Int Med* 2000; 247:153-5.
- Rainsford KD. Relationship of nimesulide safety to its pharmacokinetics: assessment of adverse reactions. *Rheumatology (Oxford)* 1999; 38 suppl 1:4-10.
- Bernareggi A. Clinical pharmacokinetics of nimesulide. *Clin Pharmacokinet* 1998; 35:247-74.
- Health Sciences Authority, Singapore. Analysis of ADR reports for year 2004. *Adverse Drug Reaction News* 2005; 7(1):5-7.
- Farrell GC. Liver disease produced by non-steroidal anti-inflammatory drugs. In: Farrell GC, Murray M, Mackay I, Hall P, eds. *Drug-induced Liver Disease*. London: Churchill Livingstone, 1994:371-88.
- Andrade RJ, Lucena MI, Fernandez MC, Gonzalez M. Fatal hepatitis associated with nimesulide. *J Hepatol* 2000; 32:174. Comment on: *J Hepatol* 1998; 135-41.
- Van Steenberghe W, Peeters P, De Bondt J, et al. Nimesulide-induced acute hepatitis: evidence from six cases. *J Hepatol* 1998; 29:135-41. Comment in: *J Hepatol* 2000; 32:174.
- Rabinovitz M, Van Thiel DH. Hepatotoxicity of nonsteroidal anti-inflammatory drugs. *Am J Gastroenterol* 1992; 87:1696-704.
- Teoh NC, Farrell GC. Hepatotoxicity associated with non-steroidal anti-inflammatory drugs. *Clin Liver Dis* 2003; 7:401-13.