

Desmoplastic round cell tumour of the abdomen

Hiralal, Gamanagatti S, Thulkar S, Rao SK

ABSTRACT

Desmoplastic round cell tumour is a very rare tumour of childhood and young adults, and is not usually suspected as an explanation of intraabdominal or pelvic tumour. We report two cases of desmoplastic round cell tumour of the abdomen in the paediatric age group, occurring in two boys, an 11-year-old and an 13-year-old. We aim to demonstrate the imaging findings and to emphasise the importance of including this tumour in the differential diagnosis of childhood intra-abdominal and pelvic tumours.

Keywords: abdominal neoplasms, desmoplastic round cell tumour, omental neoplasms, peritoneal neoplasms

Singapore Med J 2007; 48(1):e19–e21

INTRODUCTION

Desmoplastic round cell tumour (DRCT) is a distinct clinico-pathological entity that has been described recently^(1,2). This aggressive malignant neoplasm tends to occur in adolescents and young adults who present with vague abdominal discomfort or distension. These patients are often evaluated with cross-sectional imaging and the imaging features of this rare tumour have been briefly described in a very limited number of patients^(3,4). We report the imaging findings of this entity in two paediatric patients who presented with nonspecific abdominal symptoms.

CASE REPORTS

Case 1

An 11-year-old boy presented with history of abdominal discomfort for 20 days. Physical examination revealed tender hepatomegaly. No other mass was palpable. Routine laboratory investigations were normal. Ultrasonography (US) of the abdomen revealed multiple target lesions in liver and a large ill-defined heterogeneously-echoic mass lesion with internal calcifications in the retro-gastric location, medial to spleen. These findings were confirmed at computed tomography (CT) of abdomen (Fig. 1a).

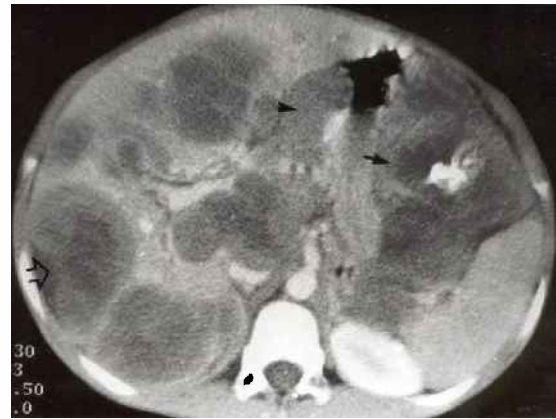


Fig. 1a Contrast-enhanced CT image of the abdomen shows a heterogeneously-enhancing mass lesion (arrow) with internal calcification. The mass is located in the greater omentum. There are coeliac and gastrohepatic lymphadenopathy (arrowhead) and multiple hypodense lesions in the liver.

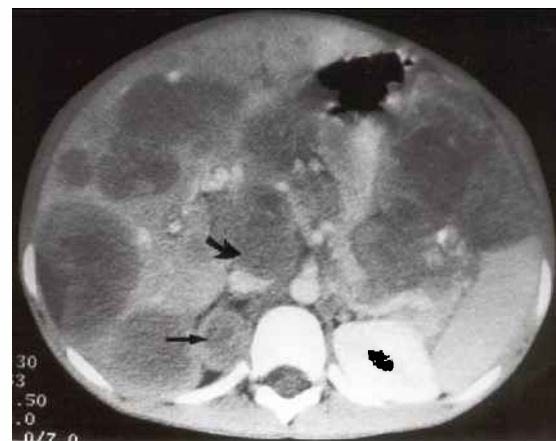

Fig. 1b Contrast-enhanced CT image of the abdomen shows a soft tissue mass lesion in right adrenal gland (arrow), peripancreatic lymphadenopathy (curved arrow) and multiple hypodense lesions in the liver.

In addition, there was a mass lesion in the right adrenal gland and multiple enlarged peripancreatic, coeliac and gastrohepatic lymph nodes (Fig. 1b).

Based on imaging features, diagnosis of gastric teratocarcinoma was made. US-guided trucut biopsy with histological analysis of the mass revealed cellular areas composed of small round cells with desmoplastic stroma interspersed in between the tumour cells, suggesting

Department of
Radiodiagnosis,
All India Institute
of Medical
Sciences,
Ansari Nagar,
New Delhi 110029,
India

Hiralal, MD
Radiologist

Gamanagatti S, MD
Assistant Professor

Thulkar S, MD
Associate Professor

Rao SK, MD
Assistant Professor

Correspondence to:
Dr Shivanand
Gamanagatti
Tel: (91) 11 2686 4851
ext 4889
Fax: (91) 11 2686 2663
Email: shiv223@
rediffmail.com

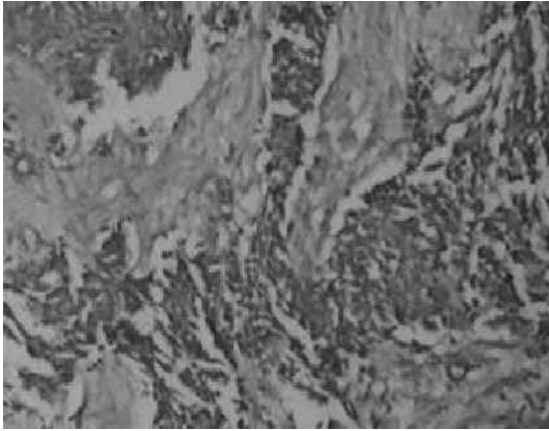


Fig. 2 Low power photomicrograph shows a tumour with cellular areas composed of small round cells with desmoplastic stroma (arrow) interspersed in between the tumour cells (Synaptophysin stain, x20).

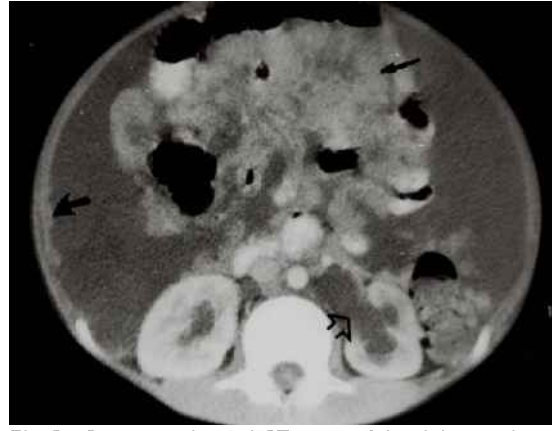

Fig. 3a Contrast-enhanced CT image of the abdomen shows multiple soft tissue mass lesions in the mesentery (arrow), ascites, nodular thickening of parietal peritoneum (curved arrow) and left-sided hydronephrosis (open arrow).

a round cell tumour (Fig. 2). The immunohistochemical studies revealed that the tumour cells were reactive to antibodies against keratin, desmin and positive for synaptophysin, confirming the diagnosis of DRCT. In view of the metastatic disease, chemotherapy was started. However, due to the aggressive nature of the disease, the patient died two months after diagnosis.

Case 2

A 13-year-old boy presented with a lump in the lower abdomen for ten days. The mass was progressively increasing in size. Physical examination revealed the presence of ascites, and a stony hard mass was felt anteriorly on per rectal examination. Routine laboratory tests were normal.

US revealed multiple solid mass lesions in the peritoneal cavity and pelvis, and ascites. These findings were confirmed at contrast-enhanced CT of the abdomen (Figs. 3a–b). All these masses were not confined to any organ-based primary site. By considering the imaging features, diagnosis of peritoneal carcinomatosis from an unknown primary was made. Trucut biopsy with histological analysis of mass showed the features of DRCT. This patient died one week after the diagnosis.

DISCUSSION

DRCT is an aggressive malignancy found predominantly in adolescents and young adults. The group of round cell tumour includes tumours such as Ewing's sarcoma, neuroblastoma, Wilm's tumour, rhabdomyosarcoma and primitive neuroectodermal tumour⁽⁵⁾. DRCT is a distinct entity with well-recognised histological features, karyotype and immunochemical characteristics⁽⁶⁾. The cell of origin may be from mesothelial, submesothelial or subserosal mesenchyme of the abdominal cavity. At histological analysis, the tumour manifests as islands

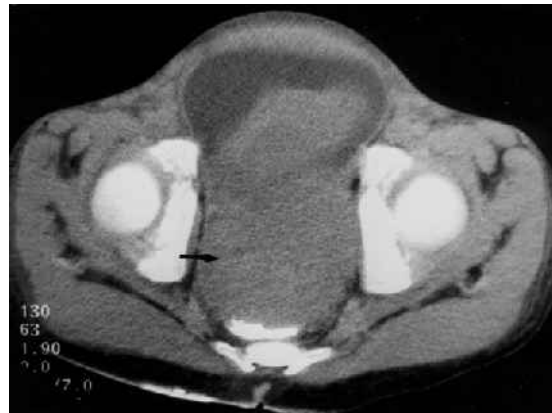

Fig. 3b Contrast-enhanced CT image (with rectal contrast) of the pelvis shows a large soft tissue mass lesion (arrow) with invasion of the anterior rectal wall.

of small blue cells surrounded by fibrous stroma. On immunohistochemical studies, DRCT are immunoreactive with antibodies to keratin, epithelial membrane antigen, vimentin, desmin and neuron-specific enolase. In our cases, both of the tumours were reactive to desmin, keratin and showed positivity for synaptophysin. DRCT is associated with a unique and specific chromosomal abnormality, t(11:22)(p13:q12)⁽⁵⁾.

DRCT was first recognised in 1987 by Sesterhenn et al, who described 17 cases of young males with DRCT arising in the pelvis or scrotum⁽¹⁾. At the time of diagnosis, patient's age ranges from three to 48 years, with median age of 21 years. A male-to-female ratio of 3:1 has been reported in the literature. The manifestations of intraabdominal DRCT are usually nonspecific, with signs and symptoms such as vague abdominal discomfort or palpable abdominal mass⁽⁷⁾. Because of the nonspecific manifestations of DRCT, patients are often evaluated by various imaging modalities. The most characteristic imaging feature of DRCT is single or multiple, lobulated

peritoneal soft tissue masses without an apparent organ of origin. These are located within the omentum, mesentery, perisplenic space, paravesical region, retroperitoneum and in the scrotum⁽⁸⁾. DRCT may be associated with ascites, hepatic metastases, lymphadenopathy, tumour calcification, diffuse nodular peritoneal thickening, and hydronephrosis due to obstructing tumour.

Radiological differential diagnoses of this entity are broad, and include various neoplastic, inflammatory and other uncommon processes. Peritoneal carcinomatosis from various primary malignancies, malignant mesothelioma of peritoneum, gastrointestinal carcinoid, malignant melanoma, and soft-tissue sarcomas such as malignant fibrous histiocytoma, may also have a similar radiological appearance. Desmoid fibromatosis, peritoneal tuberculosis, fibrosing mesenteritis, splenosis, and amyloidosis are other disorders that overlap with the appearance of DRCT^(8,9). Omental and mesenteric masses of DRCT may resemble conditions with marked lymphadenopathy, such as malignant lymphoma, Castleman disease, Whipple disease, mycobacteriosis, and actinomycosis⁽⁸⁾. In the pelvis, differential diagnosis include various neoplastic or inflammatory disorders of the reproductive tract. Similarly, in a young male patient with a scrotal mass, diagnostic considerations include germ cell and other testicular neoplasms, paratesticular sarcoma, and tumefactive inflammatory processes. The paratesticular location of desmoplastic small round cell tumour allows exclusion of the much more common testicular neoplasms⁽⁸⁾.

The prognosis of DRCT is very poor. In the vast majority of cases, it follows a course toward lethal progression. However, aggressive multimodality therapy consisting of high-dose chemotherapy, surgical

resection and radiotherapy may prolong the survival. Median survival is approximately 17 months⁽⁸⁾. In practice, the presence of a presumed organ-based primary site strongly favours the diagnosis of carcinomatosis, whereas an associated pleural rind likely represents mesothelioma. In the absence of an apparent primary tumour in an adolescent or young adult, DRCT should be considered. However, given the large overlap in the radiological appearances of peritoneal diseases, biopsy is generally recommended. In summary, although DRCT is rare entity, radiologists should familiarise themselves with this rare entity because the diagnosis may be first suggested by the imaging findings.

REFERENCES

1. Sesterhenn I, Davis CJ, Mostofi FK. Undifferentiated malignant epithelial tumors involving serosal surfaces of scrotum and abdomen in young males. *J Urol* 1987; (Suppl) 137:214A.
2. Gerald WL, Miller HK, Battifora H, et al. Intra-abdominal desmoplastic small round cell tumor. Report of 19 cases of a distinctive type of high-grade polyphenotypic malignancy affecting young individuals. *Am J Surg Pathol* 1991; 15:499-513. Comment in: *Am J Surg Pathol* 1992; 16:306-7.
3. Dao HN, Dachman AH. CT findings of regression in intraabdominal desmoplastic small-cell tumor. *Clin Imaging* 1995; 19:244-6.
4. Varma DG, McDaniel K, Ordonez NG, et al. Primary malignant small cell tumor of the abdomen: CT findings in five cases. *AJR Am J Roentgenol* 1992; 158:1031-4.
5. Amato RJ, Ellerhorst JA, Ayala AG. Intraabdominal desmoplastic small cell tumor. Report and discussion of five cases. *Cancer* 1996; 78:845-51.
6. Takhtani D, Saleeb SF, Teplick SK. General case of the day. Desmoplastic small round cell tumor of the abdomen with scrotal metastases. *Radiographics* 1999; 19:252-4.
7. Leuschner I, Radig K, Harms D. Desmoplastic small round cell tumor. *Semin Diagn Pathol* 1996; 13:204-12.
8. Pickhardt PJ, Fisher AJ, Balfe DM, Dehner LP, Huettner PC. Desmoplastic small round cell tumor of the abdomen: radiologic-histopathologic correlation. *Radiology* 1999; 210:633-8.
9. Pickhardt PJ, Bhalla S. Primary neoplasms of peritoneal and sub-peritoneal origin: CT findings. *Radiographics* 2005; 25:983-95.