

DELAYED INTRACRANIAL HAEMORRHAGE IN HEAD INJURY

M Zahari, A K Mohd Ali, S Chandrasekharan

ABSTRACT

To determine the incidence of delayed intracranial haemorrhage and the indication for repeat computed tomography (CT), a one and a half year retrospective study was made. A total of 289 patients had CT scan for head injury of which 78 (26.9%) had multiple scans. Out of these, 5 patients developed delayed haemorrhages (one extradural, one subdural and three intracerebral haematoma). The incidence of delayed intracranial haemorrhage in our series is small when compared with others. The main predisposing factors are decompressive surgery, hyperventilation and cerebral dehydration therapy. It is important to know when to repeat the CT scan. A review of the literature regarding this aspect is presented and compared with our protocol. Intracranial pressure monitoring plays an increasingly important role in the management of head injury and should be used to decide the patient requiring repeat CT. Follow-up CT without other indication is not necessary.

Keywords: delayed intracranial haemorrhage, head injury, delayed extradural haematoma, delayed intracerebral haematoma, computed tomography

SINGAPORE MED J 1996; Vol 37: 285-287

INTRODUCTION

There have been numerous reports regarding the risk of delayed intracranial haemorrhage after head injury. Sequential or repeat computed tomography have been advocated to detect these lesions. In the past, certain centres have done sequential CT merely based on the number of days post-trauma^(1,2). It is now considered unnecessary and CT scans are only done when it is thought to be useful for further management⁽³⁻⁵⁾. The indication and the timing of the repeat CT scan, however, are issues that are being reviewed and practice may vary between centres.

The purpose of this study is to determine the incidence of delayed intracranial haemorrhage and the scenario in which they occur. A review of the literature regarding the indication of repeat CT is also presented.

PATIENTS AND METHODS

All patients admitted to the neurosurgical unit, Hospital Universiti Sains Malaysia, Kelantan, Malaysia who had repeat CT between August 1990 and December 1991 were reviewed.

The initial CT were analysed for any intracranial injury. The repeat CT scans were analysed to detect any new lesion, specifically a delayed haematoma, defined by previous authors as a lesion of increased attenuation developing after admission to hospital in a part of the brain which the admission CT had suggested was normal^(4,6). The number of extraaxial haemorrhages (extradural or subdural haemorrhage) operated were also noted.

All the CT scans were done with a Phillips Tomoscan 350

whole body scanner. 9mm axial cuts were taken from the base to the vertex. In the majority of cases, no intravenous contrast media were given.

The indication(s) for repeat CT as well as the management post CT were reviewed. The protocol for repeat CT at our unit are as follows: (1) Glasgow Coma Scale (GCS) drops, (2) GCS static, (3) GCS not improving as much as expected, (4) focal sign developed, (5) on ventilator, (6) check post-surgery, (7) follow-up, and (8) extradural haematoma (EDH)/subdural haematoma (SDH) not operated.

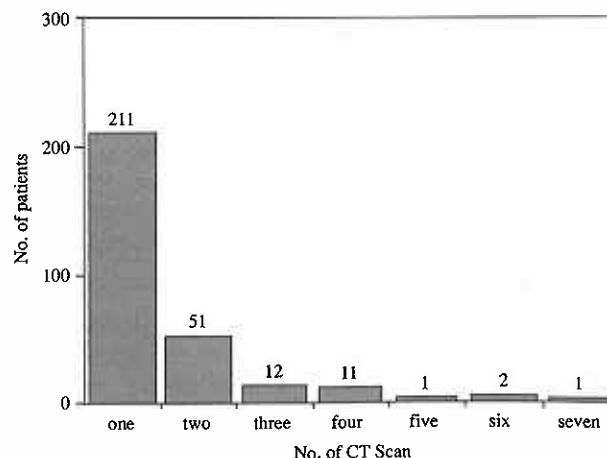
RESULTS

Seventy-eight (26.9%) out of 289 patients had multiple CT scans for head injury. The number of CT scans done per patient are shown in Fig 1. The majority of patients with repeat CT had CT scan done twice.

Out of the 289 cases, 5 patients (1.74%) developed delayed intracranial haemorrhages, two of these were extraaxial haematoma (one EDH and one SDH). Both required emergency craniotomies. The other 3 cases were delayed intracerebral haematomas. All were treated conservatively (Table I). There were a total of 46 extraaxial haemorrhages (40 EDH and 6 SDH) operated during this period.

Fig 2 shows the correlation between the number of CT scans done for each particular indication. The number of CT scan which

Fig 1 – No. of CT scan vs no. of patients



Department of Radiology
Hospital Universiti Sains Malaysia
15990 Kubang Kerian
Kelantan
Malaysia

M Zahari, FRCR (Radiology)
Lecturer

A K Mohd Ali, DMRD (Radiology)
Lecturer

Department of Surgery
Hospital Universiti Sains Malaysia
S Chandrasekharan, MCH (Neuro)
Lecturer

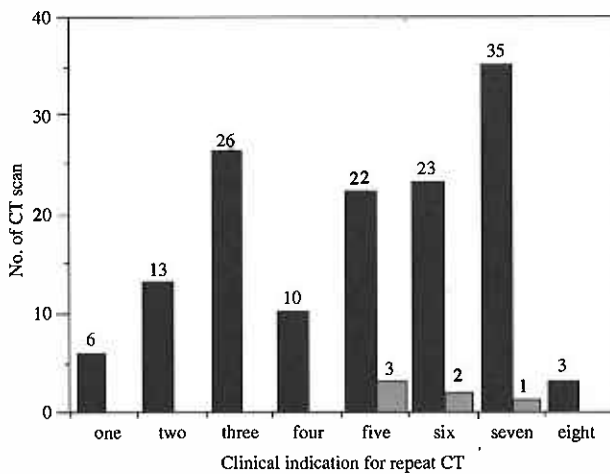
Correspondence to: Dr Zahari Mahbar

Table I – Delayed haematomas detected

Patient	Age (Years)	Initial CT	Previous surgery	Ventilator	Delayed haematoma	Interval with previous CT	Surgery required	Clinical Outcome
1. MRA	15	L frontal haematoma	Yes	Yes	R parietal EDH	2 days	Yes	Survived, Poor outcome
2. HLN	54	L SDH	Yes	No	R SDH	7 days	Yes	Survived, Good recovery
3. MY	42	Bifrontal contusion, L frontal haematoma	No	Yes	R frontal haematoma	2 days	No	Survived, Good recovery
4. HY	48	Generalised oedema	No	Yes	R temporal haematoma	3 days	No	Survived, Good recovery
5. NMJ	18	L frontal haematoma	No	Yes	L frontal haematoma	3 days	No	Survived, Good recovery

EDH - Extradural haematoma
SDH - Subdural haematoma

Fig 2 – Clinical indication for repeat CT vs no. of CT



One: GCS drops; Two: GCS static;
Three: GCE not improving as much as expected;
Four: Focal sign developed; Five: on ventilator;
Six: Check post-surgery; Seven: Follow-up CT;
Eight: EDH/SDH not operated

■ Total no. of CT
■ Delayed haematomas detected

detected a delayed intracranial haemorrhage according to the indication for repeat CT is also illustrated.

Among patients on ventilator and those who had surgery (or both), 4 cases of delayed haemorrhages were detected. Follow-up CT without any other indication detected one delayed intracerebral haemorrhage. The other indications did not detect any case of delayed haemorrhage.

DISCUSSION

The existence of delayed intracranial haemorrhages has been increasingly recognised with the advent of CT^(6,7). It has become clear that despite a normal initial CT after evacuation of a haematoma, the risk of developing a delayed haemorrhage exist.

Its actual incidence however is small. Our study showed only 5 cases out of 289 (one EDH, one SDH and 3 intracerebral haematomas) developed delayed intracranial haemorrhages. This is slightly lower compared with the series by Borthne et al⁽⁸⁾ who had 9 cases of delayed intracranial haemorrhage (2 EDH, one SDH and 6 intracerebral haematomas) out of 300 patients.

Most series written on delayed extradural haematoma (DEDH) had a detection rate of 5% - 10%^(6,9,10). We only detected

one out of 40 EDH cases (2.5%). Poon et al⁽⁷⁾ noted an incidence of 30% (22 out of 73 cases). We believe that our lower detection rate is due to our rural setup where patients are referred very late from the peripheral centres and occasionally, only when their condition deteriorate. So-called delayed haematoma may have already surfaced. In the series by Poon et al⁽⁷⁾, the patients had an initial CT less than one hour after trauma.

Several factors are known to contribute towards the development of delayed extraaxial haemorrhages. These include hypovolemia and/or hypotension, surgical decompression, dehydration therapy and hyperventilation^(7,10). It has been postulated that the removal of the tamponading effect by these mechanisms lead to the delayed haemorrhages^(11,12).

Both of our cases of extraaxial haemorrhages had previous decompressive surgery. In addition, one was also on ventilator. Di Rocco et al⁽¹¹⁾ noted that about half of the delayed epidural haematoma occurred following craniotomy to remove another haematoma. Rivas et al⁽¹⁰⁾ in his series, found that 8 of 13 of his cases occurred following decompressive surgery or were initially hypotensive and resuscitated. These two mechanisms are thus very important and increased vigilance are needed when managing them.

Delayed intracerebral haematoma is thought to be due to a local failure of cerebral blood flow regulation secondary to the injury. Relaxation of cerebrovascular resistance leads to transmission of intracerebral pressure to the capillary bed and thus haematoma formation⁽⁹⁾. Relief of tamponading effect after surgical decompression is another factor^(9,13).

The significance of delayed intracerebral haematoma is unlike the extraaxial lesion as most of them are conservatively treated⁽⁴⁾. All three of our cases were conservatively treated and survived.

The risk of intracranial haematomas, however, can never be totally discounted even when risk factors are not present. Miller et al⁽¹⁴⁾ studied 183 patients with initial full GCS who later developed traumatic intracranial haematomas requiring evacuation. Sixteen percent of these had no skull fracture or focal neurological signs and symptoms initially. Numerous case reports attest to this possibility^(15,16).

It is thus difficult to predict the development of these haematomas. Their presence are undeniable but they are actually rare. Although risk factors are known, they can occur under almost any circumstances. Time-based repeat CT will detect the delayed haematomas but will utilise a lot of resources. It is thus

important to know when to repeat the CT scan.

Various indications for repeat CT have been espoused. Frankhauser et al⁽⁷⁾ in 1983 proposed the following:

1. After 2-3 days if the first CT shows a fracture with an overlying collection of blood too small for surgical evacuation;
2. In all cases of secondary deterioration;
3. Where there is a secondary elevation of intracerebral pressure (ICP);
4. Where there is no clinical improvement;
5. In cases where there is no persistent elevation of ICP after evacuation of intracranial haemorrhage;
6. After 12 to 24 hours for all paralysed and ventilated patients.

Bucci et al⁽³⁾ in 1986 suggested that polytrauma patients must be rescanned after correction of hypovolemia even if the initial CT was normal. In addition, a repeat CT within 24 hours was also suggested to detect a delayed contralateral haematoma after surgical decompression.

Lately, the indications for repeat CT have been simplified. Gentleman et al⁽⁴⁾ in 1989 mentioned that repeat CT is indicated when:

1. Mean ICP becomes elevated above 30 mmHg,
2. There is clinical deterioration,
3. There is failure to improve.

A similar protocol was advocated by Hadley⁽⁵⁾ in 1991.

It is clear that the indication for repeat CT takes into account all of the known risk factors as mentioned earlier. In addition, the role of intracranial pressure (ICP) monitoring has been emphasised, in particular by the later authors.

In severe head injury, ICP monitoring detects rising intracranial pressure early. The patient can then be scanned to determine whether the raised ICP is due to a new haemorrhage or generalised brain-swelling. Appropriate treatment, either surgical evacuation or measures to reduce brain swelling, can be instituted. CT only detects focal lesion relatively late. It is a fallacy also to use the CT scan as an indicator of ICP as the ICP may be normal despite contrary evidence on the CT scan⁽¹²⁾. Thus determining ICP in hyperventilation and/or mannitol therapy using CT scan can be erroneous.

Review of the indications of repeat CT at our unit indicate that our doctors generally follow the guideline as set by these authors. The only difference is that some patients simply have follow-up CT scans. When delayed intracerebral haematoma is detected, the treatment is conservative. More intracerebral haematomas will be detected by routine follow-up CT but the significant ones would have been suspected clinically⁽⁷⁾. Routine follow-up CT is probably not necessary. There are other important indications for repeat CT, but on these indications in our series, no cases of delayed haemorrhage was detected. A larger series would be needed to further evaluate this.

CONCLUSION

CT scans are useful to detect delayed intracranial haemorrhages

after head injury. The incidence of such lesions are small although the actual number would depend on the timing of the initial CT scan and the imaging protocol. Patients on hyperventilation/mannitol therapy or who undergo surgical decompression are at the highest risk.

There are many indications for repeat CT scan. Use of intracranial pressure monitoring devices in severe head injury is increasingly becoming more important and should be used to determine which patient requires repeat CT. Routine follow-up CT is not indicated.

REFERENCES

1. Kobayashi S, Nakasawa S, Otsuka T. Clinical value of serial computed tomography with severe head injury. *Surg Neurol* 1983; 20: 25-9.
2. Lipper MH, Kishore PR, Girevendulis AK, Miller JD, Beckcr DP. Delayed intracranial hematoma in patients with severe head injury. *Radiology* 1979; 133: 645-9.
3. Bucci MN, Philips TW, McGillicuddy JE. Delayed epidural haemorrhage in hypotensive multiple trauma patients. *Neurosurgery* 1986; 19: 65-8.
4. Gentleman D, Nath F, Macpherson P. Diagnosis and management of traumatic intracerebral haematomas. *Br J Neurosurg* 1989; 3: 367-72.
5. Hadley DM. Head trauma. Its investigation, follow-up and the clinical importance of imaging. *Current Imaging* 1991; 3: 64-73.
6. Milo R, Razon N, Schiffer J. Delayed epidural haematoma. A review. *Acta Neurochir (Wien)* 1987; 84: 13-23.
7. Poon WS, Rehman SU, Poon CYF, Li AKC. Traumatic extradural haematoma of delayed onset is not a rarity. *Neurosurgery* 1992; 30: 681-6.
8. Borthne A, Sortland O, Blikra G. Head injuries with delayed intracranial haemorrhage. *Tidsskr Nor Loegeferen* 1992; 112: 3425-8. (abstract)
9. Piepmier JM, Wagner FC Jr. Delayed post-traumatic extracerebral haematomas. *J Trauma* 1982; 22: 455-60.
10. Rivas JJ, Lobato RD, Sarabia R, Cordobes S, Cabrera A, Gomez P. Extradural haematoma: An analysis of factors influencing the course of 161 patients. *Neurosurgery* 1988; 23: 44-51.
11. Di Rocco A, Ellis SJ, Landes C. Delayed epidural haematoma. *Neuroradiology* 1991; 33: 253-4.
12. Lobato RD, Rivas JJ, Cordobes F, Alted E, Perez C, Sarabia R, et al. Acute epidural haematoma: An analysis of factors influencing the outcome of patients undergoing surgery in coma. *J Neurosurg* 1988; 68: 48-57.
13. Hirsh LF. Delayed traumatic intracerebral hematomas after surgical decompression. *Neurosurgery* 1979; 5: 653-5.
14. Miller JD, Murray LS, Teasdale GM. Development of a traumatic intracranial haematoma after a minor head injury. *Neurosurgery* 1990; 27: 669-73.
15. McFeelay PJ, Blissard KS. Delayed traumatic intracerebral haematoma (DTICH) and the determination of the manner of death. A case report and review of the literature. *Forensic Sci* 1988; 33: 801-5.
16. Elsner H, Rigamonti D, Corradino G, Schelegei R Jr, Joslyn J. Delayed traumatic intracerebral haematomas: "Spat-Appoplexie". Report of 2 cases. *J Neurosurg* 1990; 72: 813-5.
17. Frankhauser H, Uske A, De Tribolet N. Les haematomas epidurcaux retardes. A porpos d'une serie de 8 cases. *Neurochirurgie* 1983; 29: 255-60.