

ELECTROCARDIOGRAPHIC CASE

SYNCOPE IN AN ELDERLY

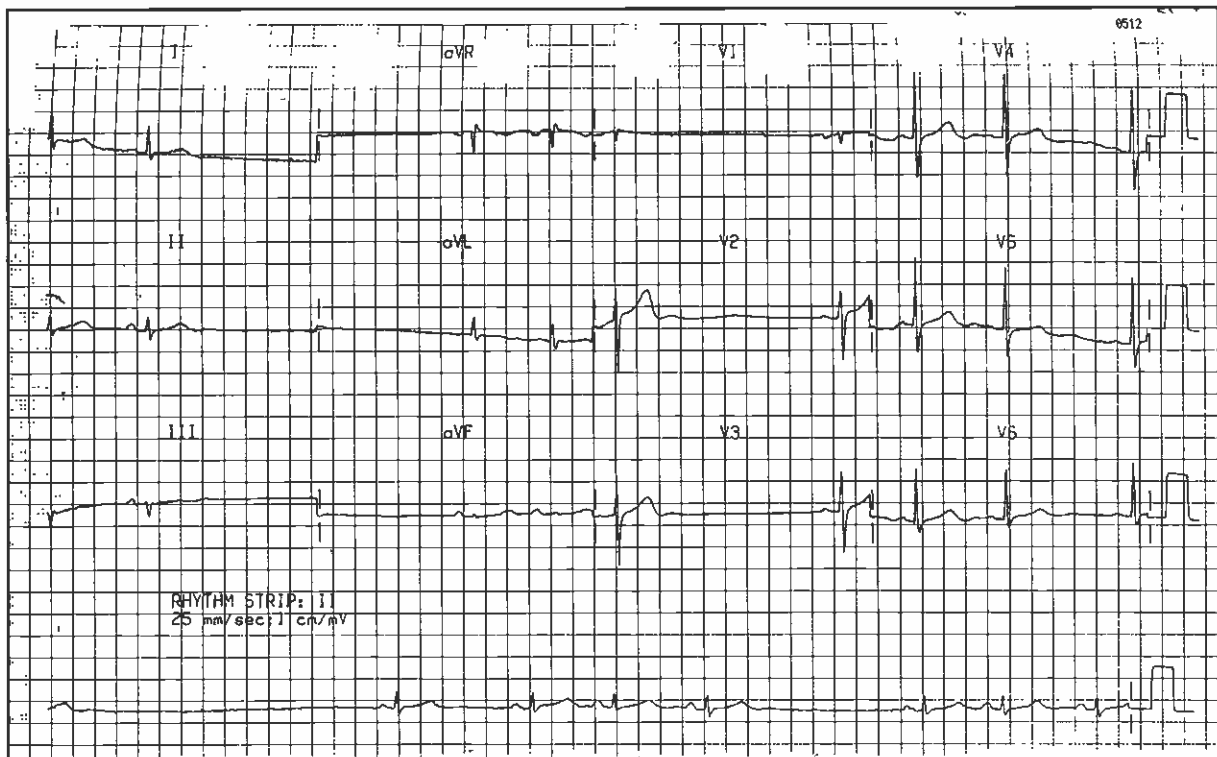
J S Ardian, W S Teo

CASE HISTORY

A 62-year-old lady presented with complaints of palpitation and giddiness for the last 3-4 years. She was admitted to the hospital with history of syncope on getting up from the chair. She has no history of angina or cardiovascular risk factors. The clinical examination was unremarkable and the blood pressure was 140/70 mmHg. Her ECG is as shown in Fig 1. What is the diagnosis? (Answer on page 236-237)

SINGAPORE MED J 1996; Vol 37: 205 & 236-237

Fig 1- 12 leads ECG on admission.



Singapore Heart Centre
Singapore General Hospital
Outram Road
Singapore 169608

J S Ardian, MD
Registrar

W S Teo, MBBS, M Med (Int Med), MRCP (UK)
Consultant

Correspondence to: Dr W S Teo