

MESIAL TEMPORAL LOBE EPILEPSY IN SINGAPORE

M W L Chee, P Pillay, K K Tan, F Hui, S G Chee

ABSTRACT

Mesial temporal lobe epilepsy due to mesial temporal sclerosis is a distinctive syndrome and a surgically remediable form of epilepsy. We present 26 Singaporean cases of mesial temporal lobe epilepsy defined by clinical, electroencephalographic and MR features and validated by good surgical outcome (12 seizure free, 5 with two or fewer seizures) in all 17 patients who have so far undergone surgery and who have been followed up for at least 6 months. Sixty-five percent of patients experienced their first seizure in the setting of a febrile illness. Seventy-three percent of patients had seizure onset before the age of 10 years and the median interval between seizure onset and intractability of seizures was 3.75 years. 80.7 % of patients had an aura and an equal number had at least one lateralising sign during their seizures. Sixty-four percent of patients had predominantly unilateral anterior temporal interictal spikes. Eighty-eight percent of patients had seizures which were lateralised on scalp ictal EEG. MRI abnormalities were most frequently seen in the head and body of the hippocampal formation. Asymmetric hippocampal atrophy was more common than hippocampal T2 or T2 signal changes. There is much similarity in characteristics of mesial temporal lobe epilepsy in our population compared to what has been published regarding Caucasian subjects.*

Keywords: temporal lobe epilepsy, electroencephalography, epilepsy surgery, magnetic resonance imaging

SINGAPORE MED J 1995; Vol 36: 621-627

INTRODUCTION

The term 'temporal lobe epilepsy' has been used for many years to denote a syndrome of recurrent simple partial or complex partial seizures where seizure symptoms appear to originate from the limbic structures in the mesial temporal region. Mesial temporal sclerosis was first described by Bouchet and Cazauvieilh in 1825⁽¹⁾ but use of this term and the clinical significance of this lesion was not recognised till later. Publications in the 1950's referred to the hippocampus and its role in epilepsy^(2,4) and it became accepted that the hippocampus was a key structure in that its removal was crucial to surgical success. In the late 1980's when non-invasive structural and functional imaging modalities appeared, there was a boost in the popularity of epilepsy surgery as a treatment for refractory partial epilepsy. The term 'mesial temporal lobe epilepsy' (MTLE) with rather distinct clinical and radiologic features was coined to highlight incremental observations made in the course of refining temporal lobe epilepsy surgery⁽⁵⁻⁷⁾. We present our experience with this entity in

Singapore, highlight its key features and point out the significance of recognising this syndrome.

MATERIALS AND METHODS

Twenty-six patients who had apparently unilateral hippocampal MR abnormalities were identified from a larger group of 46 patients who underwent evaluation of refractory complex partial seizures. Each of the patients had at least two seizures a month despite being on appropriate anticonvulsants for at least a year. Average seizure frequency was determined by seizure diary kept at least three months. The accuracy of seizure frequency was verified by interviewing a close relative. Auras were classified according to the scheme used by Palmi et al⁽⁸⁾.

Video EEG monitoring was performed from between 4 to 12 days in 25 patients (two patients had double studies) with scalp and sphenoidal electrodes using a Telefactor system. Analysis of interictal spikes followed rules set forth by Morris et al⁽⁹⁾. Ictal EEGs were analysed according to principles set forth by Risenger et al⁽¹⁰⁾. The terminology used to describe ictal behaviour followed that used by Chee et al⁽¹¹⁾.

MRI's were performed on General Electric 1.5 T Signa machines. All patients underwent imaging with 'FSE T2' or T2 weighted coronal slices. In 13 patients, spoiled gradient echo images (SPGR) were obtained utilising 35/5/1 (TR/TE/Nex) a pulse sequence, flip angle 35 degrees, matrix size 256 x 192, 2 mm contiguous slices. Eleven patients had IR images 3500/26/300 (TR/TE/TI), matrix size 256 x 192, 5 mm slices. Asymmetry of amygdala and hippocampal regions was assessed visually by dividing this region into 4 parts: Amygdala, hippocampal head, hippocampal body and hippocampal tail. The anatomic landmarks for this segregation were those used by Watson et al⁽¹²⁾. Increased signal of the hippocampus was looked for in the T2/FSE images and asymmetric signal in the IR images constituted abnormal changes. Severity of MR abnormality was judged on a 4 point analog scale ranging from 0 to 3. Zero on this scale means no abnormality and '3' indicates severe abnormality.

Accuracy of lateralisation and localisation of the seizure focus was validated by good outcome following temporal lobectomy in all patients who underwent temporal lobectomy. Pathologic material was not available for analysis because of the use of suction as a means of removing the hippocampus.

RESULTS

The patients' age ranged from 15 to 46 years with a median age

Department of Neurology
Singapore General Hospital
Outram Road
Singapore 169608

M W L Chee, MBBS, MRCP (UK), FAMS
Consultant Neurologist

Department of Neurosurgery
Singapore General Hospital

P Pillay, MBBS, FRCS, FAMS
Consultant and Head

Department of Neurosurgery
Tan Tock Seng Hospital
Moulmein Road
Singapore 308433

K K Tan, MBBS, FRCS, FAMS
Senior Consultant

Department of Diagnostic Radiology
Tan Tock Seng Hospital

F Hui, MBBS, FRCR, FAMS
Consultant Radiologist

S G Chee, MBBS, FRCR, FAMS
Consultant Radiologist

Correspondence to: Dr M W L Chee

of 31.5 years (Table I). The age of onset of seizures ranged from 6 months to 26 years. Eleven (42%) out of 24 patients had their first seizure before the age of three years. Nineteen (73%) patients had an onset of seizures before the age of 10 years. The interval between seizure onset and the occurrence of frequent spontaneous seizures ranged from zero to 21.5 years (median 3.75 years). The duration of recurrent seizures ranged from 8 to 34 years. There were 14 females and 12 males. There were 20 Chinese, 3 Malay, 2 Indian and one Eurasian patients. Nine patients had left hippocampal atrophy and 17 had right hippocampal atrophy.

The most common underlying aetiology was 'febrile seizures' (46.1%). Five patients (19.2%) listed as having 'brain infection' were hospitalised for seizures which accompanied a febrile illness. These either had status epilepticus or a prolonged hospital course. Lumbar puncture results were not available but these patients or their relatives recall being told that they had a 'brain infection'. In total, 17 (65.4%) of patients had their first seizure in relation to a febrile illness. Three (15.4%) patients were sure their first seizure did not occur in the setting of a febrile illness. One felt that childhood head trauma might have been an aetiological factor. In 5 patients (19.2%), circumstances surrounding the first seizure were forgotten.

An aura was reported by 21 (80.7%) of the patients. Viscero-sensory auras were reported in 12 patients. Of these, epigastric aura was present in 9, palpitations in 2 and nausea in 1. Fear was observed by 4 patients. Giddiness was reported by 4 patients, one of whom also complained of a strange feeling which he could not describe. Cephalic aura was seen in one patient.

Twenty-one (80.8%) patients had at least one lateralising clinical feature from history or video EEG monitoring. Eleven patients had dystonic posturing contralateral to the ictal focus. Ten patients had version. Seven patients had unilateral upper extremity automatisms which were ipsilateral to the side of

seizure origin. Four patients had non-versive head turning which was ipsilateral in three and a mixture of both in one patient. Clear dysnomia was seen in two patients and ictal speech was present in one patient. Five patients had bland seizures with no lateralising signs.

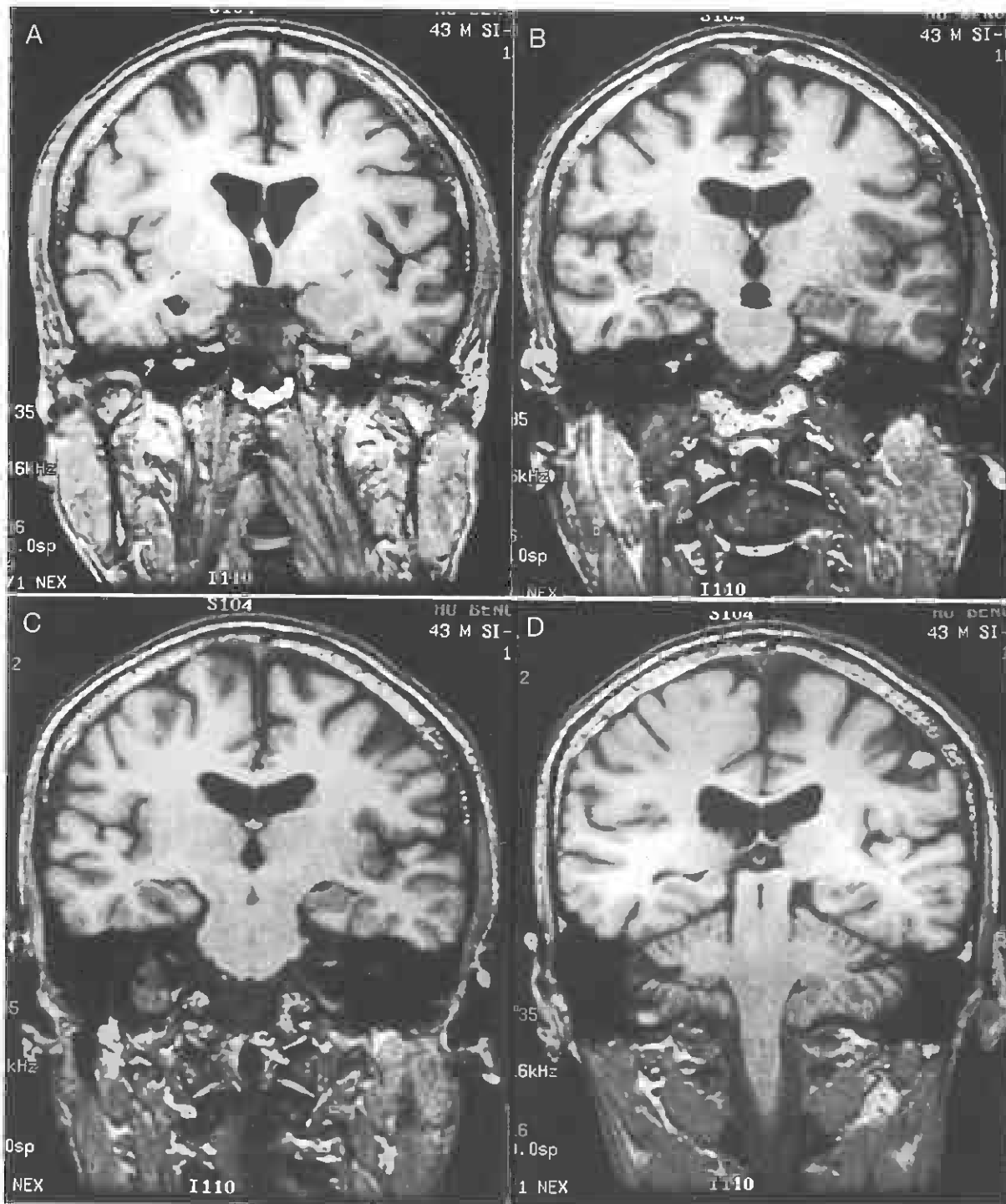
Interictal EEG showed predominantly unilateral anterior or sphenoidal interictal temporal spikes (as defined by the presence of 90% or greater spikes originating from one side) in 16 out of 25 (64%) patients who underwent video-EEG monitoring. One of these had fronto-central in addition to mesial temporal spikes. Seven (28%) patients had between 50-90% spikes originating from the ipsilateral anterior temporal or sphenoidal electrodes. One patient had no interictal spikes, another patient had falsely lateralised spikes. In 22 of 25 (88%) patients, ictal EEG recordings provided useful lateralising information. In three patients ictal patterns could not be lateralised. The single patient who declined video-EEG monitoring had unilateral right anterior temporal interictal spikes on routine EEG, unequivocal unilateral right hippocampal atrophy on MRI and she also had a typical complex partial seizure in the clinic.

Asymmetric atrophy of the mesial temporal structures (Fig 1 a-d, 2 a-d and 3 a-d) was seen in 48%, 96%, 92% and 77% (Table II) of patients in the amygdala, hippocampal head, body and tail respectively. Increased T2 (Fig 3e) or FSE T2* signal was seen in 12%, 92%, 88% and 50% of patients in the four anatomic subdivisions (amygdala, hippocampal head, body and tail). Thus, abnormalities were most frequently seen in the head and body of the hippocampal formation and least frequently in the amygdala. Preliminary experience with inversion recovery images (11 cases) suggests that this sequence is as sensitive as the SPGR sequence. Abnormality unique to IR images was not observed. Asymmetry of the temporal horn as a feature distinct from hippocampal abnormalities was seen in 54% of patients but was misleading in one of these (4%). Collateral white matter atrophy

Table I – Clinical characteristics of patients with intractable MTLE

Patient	Sex	Age at first seizure (yrs)	Age seizures became intractable	Present age (yrs)	Aetiology	Aura	Ictal lateralising clinical signs
AAL	F	3	13	25	'CNS infection'	epigastric	dystonia
ARI	M	10	10	34	unknown	none	version
BKS	M	0.58	16	24	'CNS infection'	epigastric	version
CYW	M	0.9	4	19	febrile seizure	cephalic	version, automatisms
CBS	F	14	14	45	'CNS infection'	epigastric	none
CCK	M	3	12	46	febrile seizure	epigastric;fear	head turn
HBT	M	0.5	22	43	febrile seizure	none	dystonia, automatisms
JLLL	F	1	9	38	febrile seizure	epigastric, giddiness	dystonia, version
KBA	F	26	26	34	no recall	palpitations	version, head turn
KLC	F	10	15	22	no recall	epigastric	none
KHK	F	7	unknown	36	febrile seizure	vertigo	none
LKN	F	1	2	36	no recall	giddiness	version, automatisms
LSH	M	23	23	31	unknown	epigastric	none
LYM	F	7	7	32	febrile seizure	anxiety, palpitation	dystonia, version, speech
MSG	M	2	10	27	febrile seizure	none	head turn
NHT	F	4	5	37	no recall	none	automatisms
OTS	M	11	17	37	'CNS infection'	funny feeling	dystonia, dysnomia
PSY	F	3	7	15	febrile seizure	chest sensation, nausea	dystonia, automatisms
SBA	F	19	19	31	unknown	fear, nausea	none
SBS	F	0.9	4	16	'CNS infection'	funny feeling	version
TCJ	M	9	9	27	head trauma	giddiness	dystonia
TPK	M	2	12	28	febrile seizure	feels strange, giddiness	dystonia, version
TCM	F	2	2	24	febrile seizure	epigastric	automatisms
CLV	M	1	10	35	febrile seizure	fear, anger	dystonia, version
YKS	M	2	unknown	26	no recall	epigastric	dystonia, automatisms
YPC	F	3	18	32	febrile seizure	fear	dystonia, dysnomia

Fig 1(A-D) – Sequence of 3D SPGR, coronal MRI images of a patient with right mesial temporal lobe epilepsy showing severe (grade ‘3’) head and body and tail atrophy . The sequence of images shows one cut each at the amygdala + anterior hippocampal head (1A) , hippocampal head / body junction (1B) , body (1C) and tail (1D).



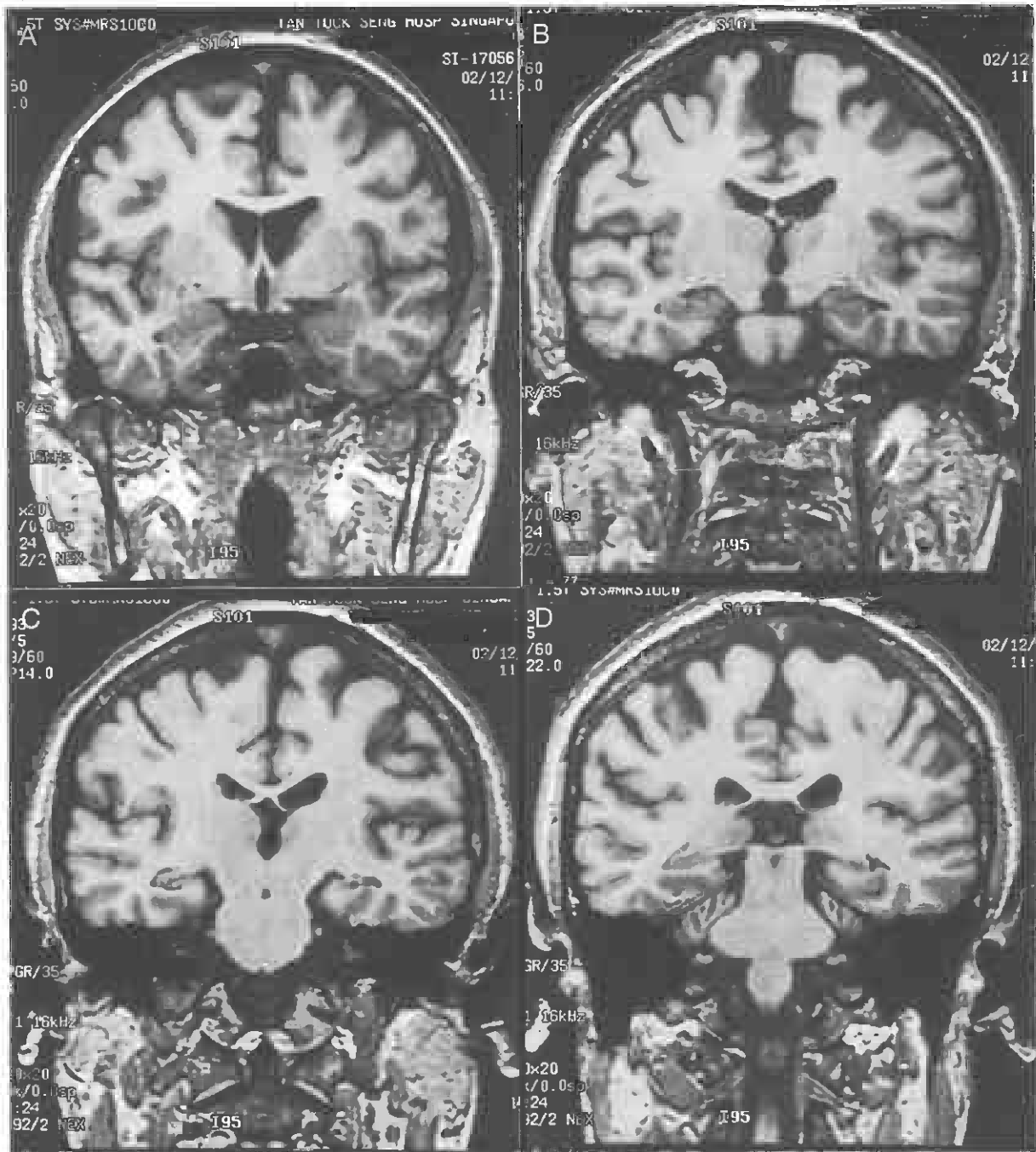
was seen in 54% on the side ipsilateral to the abnormal hippocampus.

Of the 17 patients who had temporal lobectomy and at least 6 months of follow-up, 9 had satisfactory resection of the amygdala, hippocampal head and body and part of the lateral temporal neocortex. Seven had resection of the part of the temporal neocortex and limited resection of the mesial temporal structures. One patient did not have post operative MR. Twelve of these 17 patients (66%) were seizure-free at six months. The remaining five patients had one or two seizures. Thirteen patients have at least one year of follow-up following surgery and, of

these, 9 have been seizure-free. Eight were truly seizure-free for a year and one patient was seizure-free except for one seizure when he defaulted anticonvulsant medication for a week (this type of case is counted as ‘seizure-free’ in most surgical series). Three patients had three or fewer seizures a year and one patient had four seizures in his first post-operative year although this still represented a greater than 50% reduction in seizures. These favourable surgical results help validate the diagnosis of mesial temporal lobe epilepsy in this series.

All patients are still on anticonvulsant medications although at reduced doses, reduced number of medications or a combination

Fig 2(A-D) – 3D SPGR, coronal MR images of a patient with moderate (grade ‘2’) hippocampal head atrophy (2A) , severe (grade ‘3’) left hippocampal body (2B, 2C) and tail atrophy (2D).



of both. It is envisaged that a few patients might be seizure-free off medications. However, we are conservative about full medication withdrawal.

DISCUSSION

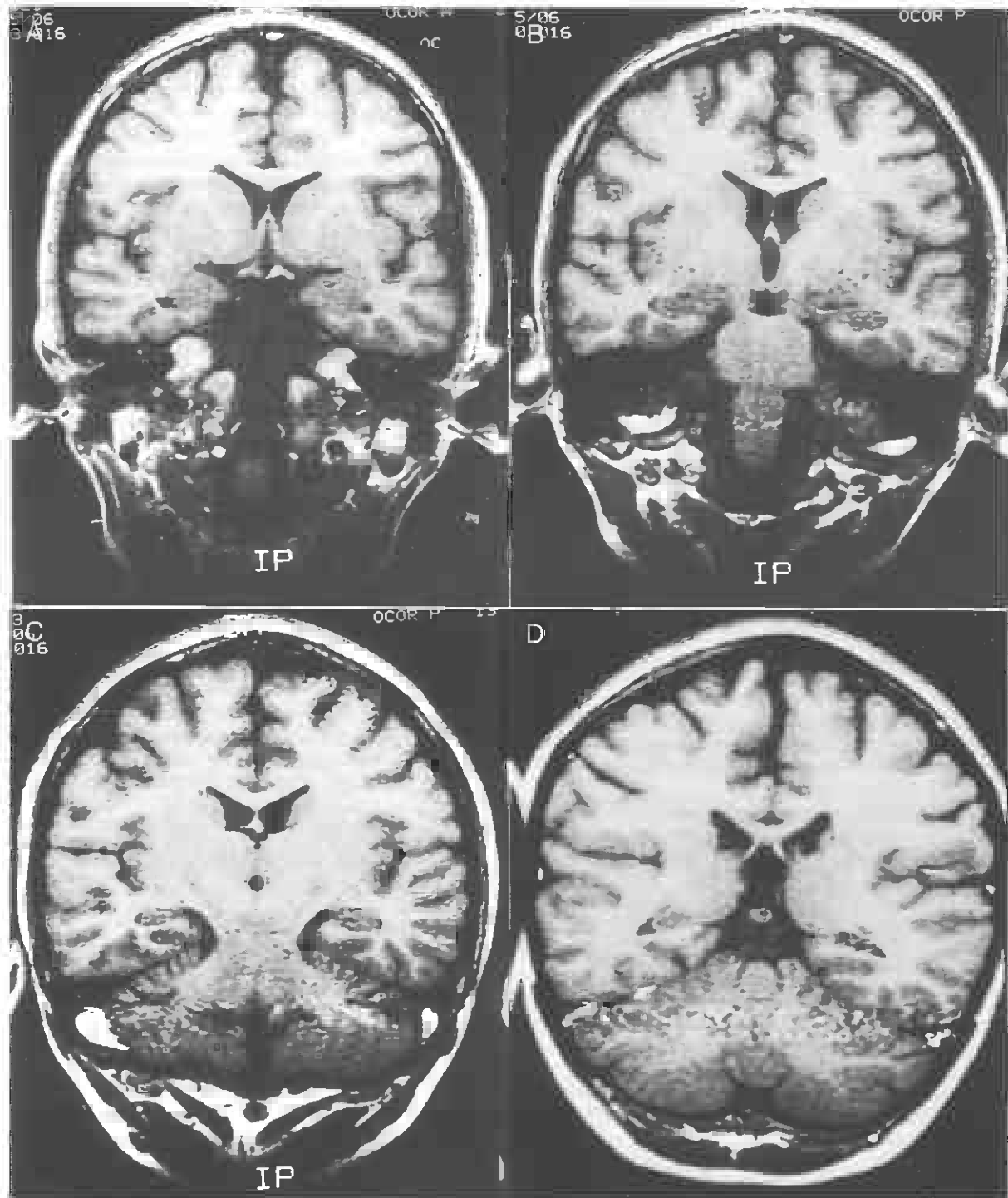
Patients with mesial temporal lobe epilepsy (MTLE) form the largest group of patients who have surgically remediable, intractable, focal epilepsy⁽¹³⁾ and relatively normal cognitive function. They begin to have seizures while in the first three decades of life, a period when vocational and social skills are acquired.

There is a spectrum of severity of MTLE and some patients achieve good seizure control with anticonvulsant medication. Other patients like those we report have intractable seizures despite having tried several anti-epileptic medications. For these,

temporal lobectomy has proved to be a highly effective treatment from the point of seizure control⁽⁵⁾. Sub-optimal result from a psycho-social viewpoint is likely a result of being in the ‘sick role’ for most of the patient’s developmental period. It is therefore logical for persons with MTLE to be identified as soon as possible and to be offered surgery soon if an adequate trial of medication has failed to control seizures. We found that a median time of 3.75 years elapsed between the onset of the first seizure and the perception that the seizures were frequent and disabling. This time is time lost in potentially productive activity and every effort should be made to refer patients suspected of having MTLE to a centre capable of confirming the diagnosis and optimising treatment.

In identifying MTLE a history of febrile seizures, certain types of aura, an EEG showing anterior temporal spikes, seizures

Fig 3 (A-D) – T1W coronal MR showing symmetric amygdala (3A) and hippocampal head (3B) anatomy minimal (grade ‘1’) atrophy of the right hippocampal body with some flattening of the usually oval hippocampal body (3C). The hippocampal tail is symmetric (3D).

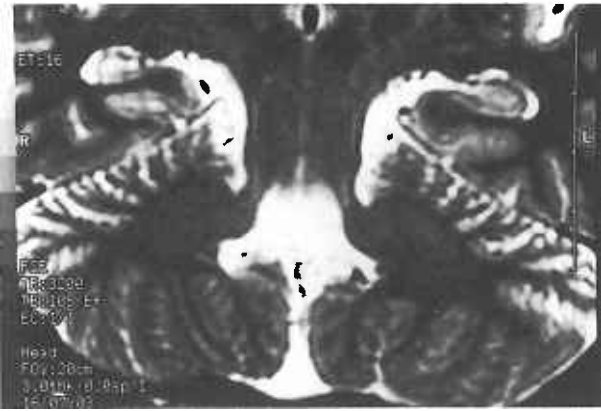

arising exclusively or predominantly from one temporal region and an MRI showing unilateral hippocampal atrophy are the cardinal findings. Auras are an important indicator of seizure origin. Although spread of an aura from an ictal focus that is not capable of generating symptoms to the temporal lobe is well documented, a majority of patients with visceral and psychic auras have mesial temporal lobe epilepsy⁽⁸⁾. Although 80% of our patients had auras, many did not volunteer a history of an aura and direct questioning was frequently necessary.

Features in the seizure history that support a diagnosis of temporal lobe epilepsy include the presence of automatisms

involving the mouth or upper extremity, dystonic posturing, post-ictal dysnomia⁽¹¹⁾ and post-ictal cough⁽¹⁴⁾. In addition mesial temporal lobe seizures are often longer in duration than non-mesial temporal lobe seizures. Clinical signs occurring during a seizure can help lateralise the seizure focus⁽¹⁵⁾. Clinical signs useful in lateralising the seizure focus include version⁽¹⁶⁾, head turning⁽¹¹⁾, dystonic posturing^(17,18), unilateral upper extremity automatisms⁽¹⁹⁾, post-ictal dysnomia^(20,21), and unilateral ictal blinking⁽²²⁾. However it is frequently difficult to get the relatives to recall which side is involved. Video EEG monitoring frequently clarifies this.

Fig 3E – The T2W coronal MR shows increased signal in the abnormal right hippocampal body.



The presence of temporal interictal spikes is suggestive but not diagnostic of temporal lobe epilepsy as extratemporal epilepsy give rise to temporal spikes. Integration of clinical and MRI correlation should always be done. Predominantly unilateral temporal interictal spikes are a good lateralising feature^(9,23) but the presence of independent left and right temporal spikes is not a contraindication to further evaluation of a patient who has predominantly unilateral seizures⁽²⁴⁾. It is likely that mesial temporal lobe epilepsy is a bilateral disease but clinically significant abnormalities are frequently unilateral.

Ictal EEG recording of patients with MTLE using scalp and sphenoidal electrodes in contrast to using intracranial electrodes was not initially felt to be useful in lateralising or localising the abnormal temporal lobe but with more experience this has changed^(10,25). This is particularly so when history, clinical observation of seizures and MRI are concordant in implicating unilateral mesial temporal disease. Non-invasive pre-surgical evaluation protocols can be successful in selecting good surgical candidates for temporal lobectomy⁽²⁶⁾.

In lieu of pathological evidence of mesial temporal sclerosis we used MR as a validating criterion in determining that a patient had MTLE. Unilateral hippocampal atrophy has recently been shown to be a sensitive and specific indicator of mesial temporal lobe epilepsy⁽²⁷⁻³⁰⁾. Studies validating the accuracy of MR include those comparing hippocampal cell loss with extent of atrophy^(31,32), surgical outcome and hippocampal asymmetry⁽³³⁾ and neuropsychological performance in relation to extent of

hippocampal atrophy^(32,34). In our experience, thin slice 3D spoiled gradient echo images with T1 like contrast emphasising anatomical detail were more sensitive than T2 weighted images but both sequences are essential in a MR protocol designed to support a diagnosis of MTLE. The high yield of T2 signal abnormality in our series is likely to be a result of MRI being a validating factor in patient selection. Asymmetry is most frequent in the head and body of the hippocampal formation in accordance with the findings of Cook et al⁽³⁰⁾. We agree with Bronen⁽³⁵⁾ that asymmetry of the temporal horns can be misleading but did not find that atrophy of the collateral white matter as useful a sign as they did. Our limited experience with IR images suggests that this imaging sequence provides complimentary information to T2 and 3D spoiled gradient recall images but we did not encounter cases where abnormalities were confined to this sequence⁽³⁶⁾. It is important to realise this data-set does not make a statement about the sensitivity of MR in the diagnosis of MTLE. Rather, the relative yields of different image sequences serve as a guide to how likely imaging abnormalities described in MTLE are actually seen.

The similarities in clinical and MR characteristics of this cohort of patients and those reported from a Caucasian population suggest that there are no ethnic differences in the characteristics of mesial temporal lobe epilepsy. Although it may be argued that the selection criteria for this study were deterministic for MTLE as it is reported in series involving Caucasians, the concordance of findings across clinical, EEG and MR parameters is striking.

The up-front cost in providing surgery as an option for patients with intractable MTLE is significant although at approximately \$US 4000 (for subsidised patients; inclusive of a presurgical workup) and \$US 11 000 for full paying patients⁽³⁷⁾, the cost of providing this in Singapore is lower than in major overseas centres. Further, the promise of returning a potentially productive individual back to the workforce instead of being a dependent is attractive. Financial modeling indicates that epilepsy surgery in well selected patients is more cost effective than chronic medical treatment in a North American setting⁽³⁸⁾. It is expected that with the burgeoning of regional economies and the increasing health care costs for the chronic sick, early recognition and aggressive management of MTLE will shift it from a luxury to a necessity.

ACKNOWLEDGEMENT

The first author would like to thank Dr Helen Tjia, Dr Tan Chai Beng, Dr Yeow Yew Khim, Dr N V Ramani for supporting the

Table II – Summary of MRI findings

Severity of MRI abnormality	amygdala atrophy	head atrophy	body atrophy	tail atrophy	amygdala incr. T2 signal	head incr. T2 signal	body incr. T2 signal	tail incr. T2 signal	amygdala IR abnormal	head IR abnormal	body IR abnormal	tail IR abnormal	inferior horn asymmetry	collateral white matter atrophy
not seen (0)	13	1	2	6	22	2	3	12	10	1	1	10	12	11
mild (1)	4	6	4	6	3	6	7	5	1	3	3	0	4	8
moderate (2)	7	11	12	7	0	11	11	6	0	6	6	1	7	4
severe (3)	1	8	8	7	0	6	4	1	0	1	1	0	2	1
total	25	26	26	26	25	25	25	24	11	11	11	11	25	24
missing value	1	0	0	0	1	1	1	2	15	15	15	15	0*	2
not seen	52%	4%	8%	23%	88%	8%	12%	50%	91%	9%	9%	91%	46%	46%
mild (1)	16%	23%	15%	23%	12%	24%	28%	21%	9%	27%	27%	0%	15%	33%
moderate (2)	28%	42%	46%	27%	0%	44%	44%	25%	0%	55%	55%	9%	27%	17%
severe (3)	4%	31%	31%	27%	0%	24%	16%	4%	0%	9%	9%	0%	8%	4%
mislateralised*													4%	
Positive for feature	48%	96%	92%	77%	12%	92%	88%	50%	9%	91%	91%	9%	50%	54%

(note there are missing image sequences in some patients and this reflects upgrading of techniques over the time this data set was acquired)

epilepsy surgery programme at Tan Tock Seng Hospital where a majority of this work was done.

REFERENCES

- Bouchet, Cazauvieilh. De l'épilepsie considérée dans ses rapports avec l'alienation mentale. *Arch Gen Med* 1825;9:510-42.
- Gastaut H. So-called "psychomotor" and "temporal" lobe epilepsy. *Epilepsia* 1953;5:59-99.
- Sano K, Malmud N. Clinical significance of sclerosis of the cornu ammonis. *Arch Neurol Psychiatr* 1953;44:483-506.
- Falconer M, Hill D, Meyer A, Mitchell W, Pond D. Treatment of temporal lobe epilepsy by temporal lobectomy. A survey of findings and results. *Lancet* 1955;i:827-35.
- Engel J Jr. Recent advances in surgical treatment of temporal lobe epilepsy. *Acta Neurol Scand* 1992;85:71-80.
- Wieser H, Engel JJ, Williamson P, Babb T. Surgically remediable temporal lobe epilepsy syndromes. In: Engel Jr. J, ed. *Surgical treatment of the epilepsies*. 2nd ed. New York: Raven Press, 1993:49-63.
- French JA, Williamson PD, Thadani VM, Darcey TM, Mattson RH, Spencer SS, et al. Characteristics of medial temporal lobe epilepsy: I. Results of history and physical examination. *Ann Neurol* 1993;34:774-80.
- Palmini A, Gloor P. The localizing value of auras in partial seizures: a prospective and retrospective study. *Neurology* 1992;42:801-8.
- Morris HHD, Kanner A, Luders H, Murphy D, Dinner DS, Wyllie E, et al. Can sharp waves localized at the sphenoidal electrode accurately identify a mesio-temporal epileptogenic focus? *Epilepsia* 1989;30:532-9.
- Risinger MW, Engel JJ Jr, Van Ness PC, Henry TR, Crandall PH. Ictal localization of temporal lobe seizures with scalp/sphenoidal recordings. *Neurology* 1989;39:1288-93.
- Chee MW, Kotagal P, Van Ness PC, Gragg L, Murphy D, Luders HO. Lateralizing signs in intractable partial epilepsy: blinded multiple-observer analysis. *Neurology* 1993;43:2519-25.
- Watson C, Andermann F, Gloor P, Jones-Gotman M, Peters T, Evans A, et al. Anatomic basis of amygdaloid and hippocampal volume measurement by magnetic resonance imaging. *Neurology* 1992;42:1743-50.
- Engel JJ. Update of surgical treatment of the epilepsies: Summary of the second International Palm Desert Conference on the surgical treatment of the epilepsies (1992). *Neurology* 1993;43:1612-7.
- Van Ness P, Marotta J, Kucera A, Klem G, Chee M. Postictal cough is a sign of temporal lobe epilepsy (abstract). *Neurology* 1993;43:A273.
- Williamson P, Wieser H, Delgado-Escueta A. Clinical characteristics of partial seizures. In: Engel J Jr, ed. *Surgical treatment of the epilepsies*. New York: Raven Press, 1987:101-20.
- Wyllie E, Lüders H, Morris H, Lesser R, Dinner D. The lateralizing value of versive head and eye movements during epileptic seizures. *Neurology* 1986;36:606-11.
- Kotagal P, Luders H, Morris HH, Dinner DS, Wyllie E, Godoy J, et al. Dystonic posturing in complex partial seizures of temporal lobe onset: a new lateralizing sign. *Neurology* 1989;39:196-201.
- Newton M, Berkovic S, Austin M, Reutens D, McKay W, Bladin P. Dystonia, clinical lateralization, and regional blood flow changes in temporal lobe seizures. *Neurology* 1992;42:371-7.
- Walker E, Sharbrough F. The significance of lateralized ictal paresis occurring during complex partial seizures [abstract]. *Epilepsia* 1988;29:665.
- Gabr M, Lüders H, Dinner D, Morris H, Wyllie E. Speech manifestations in lateralization of temporal lobe seizures. *Ann Neurol* 1989;25:82-7.
- Privitera M, Morris G, Gilliam F. Postictal language assessment and lateralization of complex partial seizures. *Ann Neurol* 1991;30:391-6.
- Benbadis S, Kotagal P, Klem G. Unilateral eye blinking: a lateralizing sign in partial seizures (abstract). *Epilepsia* 1994;34:14.
- Chung MY, Walczak TS, Lewis DV, Dawson DV, Radtke R. Temporal lobectomy and independent bitemporal interictal activity: what degree of lateralization is sufficient? *Epilepsia* 1991;32:195-201.
- So N, Olivier A, Andermann F, Gloor P, Quesney LF. Results of surgical treatment in patients with bitemporal epileptiform abnormalities. *Ann Neurol* 1989;25:432-9.
- Walczak TS, Radtke RA, Lewis DV. Accuracy and interobserver reliability of scalp ictal EEG. *Neurology* 1992;42:2279-85.
- Sperling MR, O'Connor MJ, Saykin AJ, Phillips CA, Morrell MJ, Bridgman PA, et al. A noninvasive protocol for anterior temporal lobectomy. *Neurology* 1992;42:416-22.
- Jackson GD, Berkovic SF, Tress BM, Kalnins RM, Fabinyi GC, Bladin PF. Hippocampal sclerosis can be reliably detected by magnetic resonance imaging. *Neurology* 1990;40:1869-75.
- Berkovic S, Andermann F, Olivier A, Ethier R, Melanson D, Robitaille Y, et al. Hippocampal sclerosis in temporal lobe epilepsy demonstrated by magnetic resonance imaging. *Ann Neurol* 1991;29:175-82.
- Cascino GD, Jack CR Jr, Sharbrough FW, Kelly PJ, Marsh WR. MRI assessments of hippocampal pathology in extratemporal lesional epilepsy. *Neurology* 1993;43:2380-2.
- Cook MJ, Fish DR, Shorvon SD, Straughan K, Stevens JM. Hippocampal volumetric and morphometric studies in frontal and temporal lobe epilepsy. *Brain* 1992;115:1001-15.
- Cascino GD, Jack CR Jr, Parisi JE, Sharbrough FW, Hirschorn KA, Meyer FB, et al. Magnetic resonance imaging-based volume studies in temporal lobe epilepsy: pathological correlations. *Ann Neurol* 1991;30:31-6.
- Lencz T, McCarthy G, Bronen RA, Scott TM, Inserni JA, Sass KJ, et al. Quantitative magnetic resonance imaging in temporal lobe epilepsy: relationship to neuropathology and neuropsychological function. *Ann Neurol* 1992;31:629-37.
- Garcia PA, Laxer KD, Barbaro NM, Dillon WP. Prognostic value of qualitative magnetic resonance imaging hippocampal abnormalities in patients undergoing temporal lobectomy for medically refractory seizures. *Epilepsia* 1994;35:520-4.
- Trenerry MR, Jack CR Jr, Ivnik RJ, Sharbrough FW, Cascino GD, Hirschorn KA, et al. MRI hippocampal volumes and memory function before and after temporal lobectomy. *Neurology* 1993;43:1800-5.
- Bronen R, Cheung G, Charles J, Kim J, Spencer D, Spencer S, et al. Imaging findings in hippocampal sclerosis: correlation with pathology. *AJNR* 1991;12:933-40.
- Jackson GD, Kuzniecky RI, Cascino GD. Hippocampal sclerosis without detectable hippocampal atrophy. *Neurology* 1994;44:42-6.
- SGH Finance Section. Personal communication. 1995.
- Wiebe S, Blume W, Girvin J, Gafni A. Economic evaluation of temporal lobe epilepsy surgery (abstract). *Epilepsia* 1994;35:46.