

ELECTROCARDIOGRAPHIC CASE

LEFT VENTRICULAR HYPERTROPHY IN A YOUNG ADULT

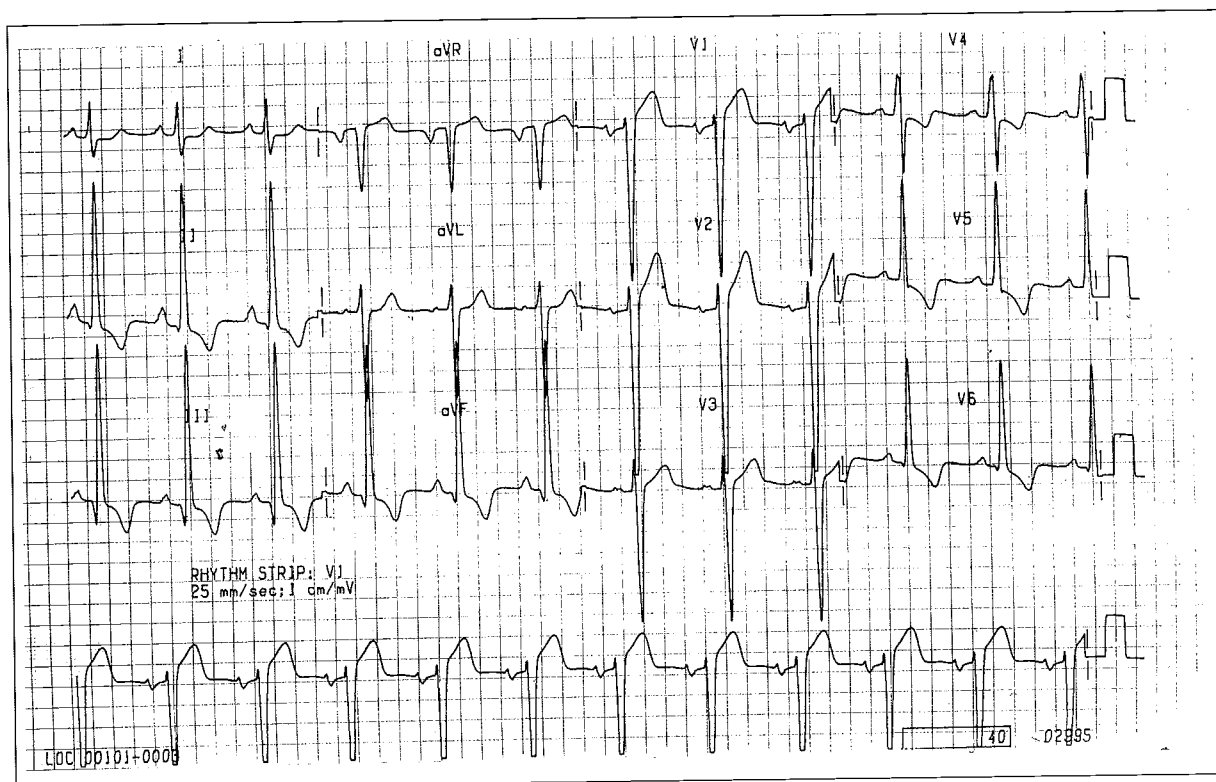
W S Teo

CASE REPORT

A 21-year-old male was referred for investigation of complaint of chest pain associated with breathlessness during exertion. There was no history of leg swelling, orthopnoea or paroxysmal nocturnal dyspnoea. He had no history of hypertension, family history of heart disease or sudden death. On clinical examination, he was well built. The blood pressure was normal. The pulse had a jerky nature. There was an additional fourth heart sound and a short late systolic murmur over the left sternal edge. His 12 lead electrocardiogram is shown in Fig 1. What is your diagnosis? Answer on page 450

SINGAPORE MED J 1995; Vol 36: 432 & 450

Fig 1 - 12 lead electrocardiogram of the patient



Department of Cardiology
Singapore Heart Centre
Singapore General Hospital
Mistri Wing, Third Hospital Avenue
Singapore 0316

W S Teo, MBBS, M Med (Int Med), MRCP (UK), FAMS
Consultant