

## ELECTROCARDIOGRAPHIC CASE

# TALL PRECORDIAL T WAVES WITH DEPRESSED ST TAKE-OFF: AN EARLY SIGN OF ACUTE MYOCARDIAL INFARCTION?

C S Soo

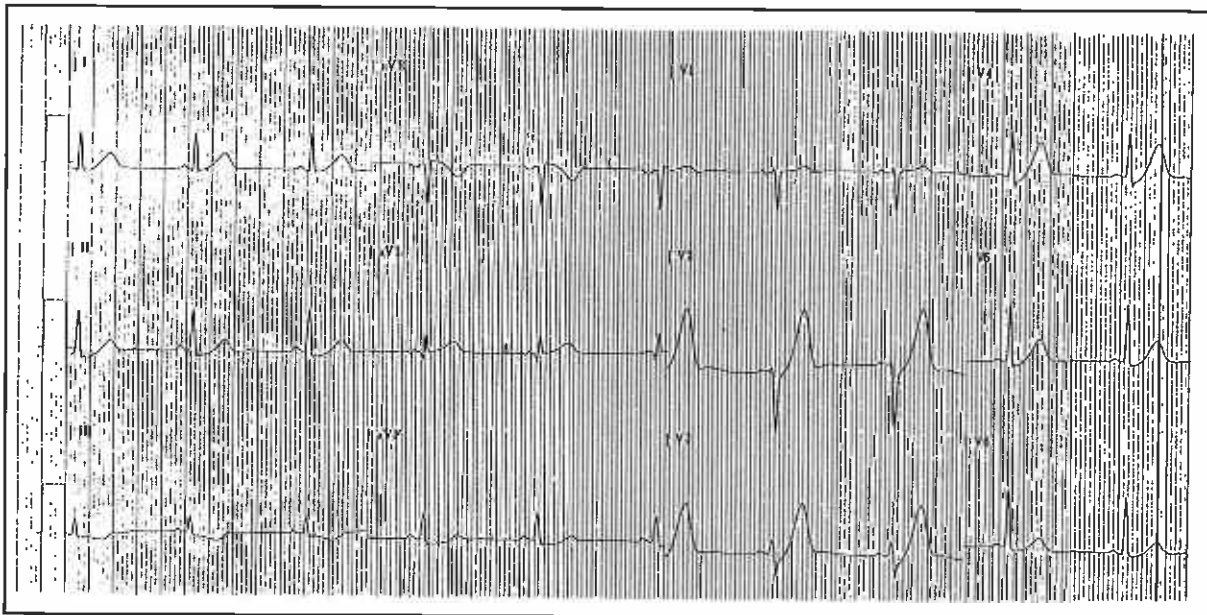
### CASE REPORT

A 38-year-old Indian gentleman presented with sudden onset of acute, gripping retrosternal chest pain which lasted one hour. There was no past history of angina or myocardial infarction. His coronary risk factors were family history of premature coronary artery disease and smoking (10 cigarettes/day). Clinical examination was unremarkable. The initial 12-lead electrocardiogram (ECG) is shown in Fig 1.

What is your diagnosis? Would you initiate thrombolytic therapy? (Answer on page 236-237)

SINGAPORE MED J 1995; Vol 36: 216 & 236-237

Fig 1 - Initial ECG



Department of Medicine  
Universiti Malaya  
59100 Kuala Lumpur  
Malaysia

C S Soo, MBBS, MRCP (UK)  
Lecturer and Cardiologist