

PALLIATION OF ADVANCED GASTRIC CANCER BY LAPAROSCOPIC GASTROJEJUNOSTOMY

C K Kum, C H A Yap, P M Y Goh

ABSTRACT

Palliation of unresectable gastric carcinoma by conventional gastrojejunostomy is associated with significant morbidity and mortality. Laparoscopic gastrojejunostomy may be an alternative as it can achieve the same results with less morbidity. This is a case report of a 68-year-old man with an obstructed, unresectable gastric carcinoma that has metastasized to the lungs and liver. Attempt at laser boring was unsuccessful. Laparoscopic assessment revealed an immobile tumour fixed to the pancreas. A totally intraabdominal laparoscopic gastrojejunostomy was fashioned with endoGIAs (USSC Norwalk, CT). Operation time was 85 minutes. He was able to tolerate feeds on the 3rd postoperative day (POD), diet on the 5th POD and was discharged on the 8th POD. Satisfactory palliation at home was achieved for ten weeks before death. Laparoscopic gastrojejunostomy is thus a good option for palliation of obstructed advanced gastric cancer.

Keywords: gastric carcinoma, laparoscopic gastrojejunostomy, palliation

SINGAPORE MED J 1995; Vol 36: 228-229

INTRODUCTION

The principle of palliative surgery in advanced malignancy is to achieve rapid alleviation of symptoms with minimal morbidity and mortality. Resection is still the best form of palliation in advanced gastric carcinoma⁽¹⁾. However, some patients have unresectable tumours or extensive metastases that make resection not worthwhile. Traditionally, open gastrojejunostomy is the only viable option available. Conventional gastrojejunostomy is, however, associated with a high morbidity of about 55% and mortality of about 22%⁽²⁾. Wound complications, chest infections and prolonged ileus are the main sources of morbidity. Laparoscopic surgery may be an alternative if it can achieve the same palliation with less morbidity and can shorten hospital stay. This is report of a totally intraabdominal laparoscopic gastrojejunostomy in a patient with unresectable metastatic gastric carcinoma.

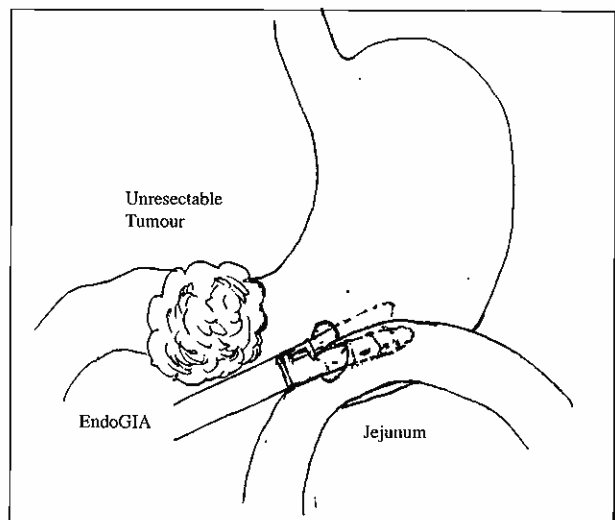
CASE REPORT

The patient was a 68-year-old Chinese man who presented in October 1992 with emesis after meals and significant loss of weight over a period of six months. Clinically he was malnourished. Abdominal examination revealed a large irregular fixed mass in the epigastrium. The liver was not palpable. Blood investigations showed anaemia (Hb 10.2 g/dL), hypoalbuminemia (albumin 33 g/L) and raised alkaline phosphatase level (459 U/L; three times above normal). The raised alkaline phosphatase suggested the presence of liver metastases. Chest X-ray revealed extensive lung metastases. Gastroscopy showed a large malignant tumour in the antrum that had occluded the pylorus. Biopsy revealed moderately differentiated adenocarcinoma. In view of the advanced disease, laser ablation was planned but had to be abandoned when the

pylorus could not be identified. Barium meal showed that the upper half of the stomach was free of tumour and thus amenable to a bypass procedure.

The patient was put under general anaesthesia. Carbon dioxide pneumoperitoneum was created via a Verres needle through a subumbilical incision. A 10mm port was placed in the subumbilical region through which the 0 degree 10mm laparoscope was introduced. The tumour was noted to have extensive local invasion and there were also multiple liver metastases. A probe, inserted through another 12mm port placed in the right lumbar region, found the tumour to be fixed to be pancreas. Another 12mm port was placed in the left lumbar region followed by a fourth 10mm port in the epigastrium. The duodenal-jejunal junction was identified and an appropriate loop of jejunum was brought up to the anterior wall of the proximal stomach. Separate stab incisions were made in the jejunum and stomach with a pair of coagulation scissors through which the limbs of the 30mm endoGIA (USSC Norwalk, CT) were inserted and fired (Fig 1). A second application of the stapler in the same line extended the anastomosis to about 60mm. These two applications were made through the right-sided 12mm port. Thereafter, the stapler was inserted through the left 12mm port and the enterostomy was closed with another two applications (Fig 2). The total procedure time was 85 minutes.

Fig 1 – Closure of the enterostomy with two more applications of the endoGIA®



Department of Surgery
National University Hospital
Lower Kent Ridge Road
Singapore 0511

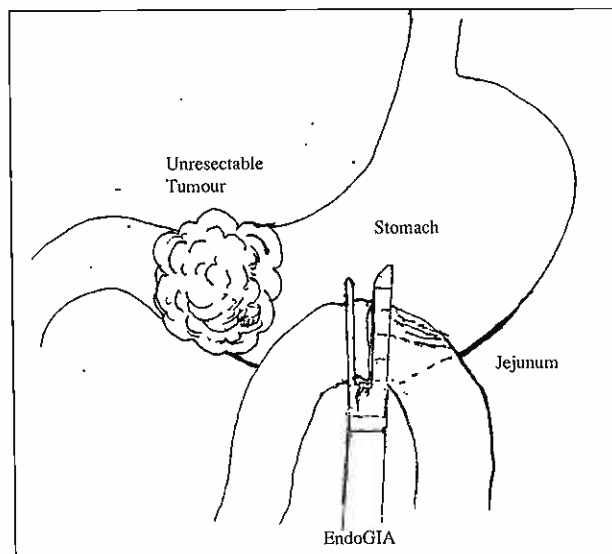
C K Kum, FRCS
Registrar

C H A Yap, MBBS
Resident

P M Y Goh, FRCS
Consultant

Correspondence to : Dr C K Kum

Fig 2 – Gastro-jejunostomy created with two sequential applications of endoGIA®



The postoperative recovery was uneventful. Bowel sounds returned on the second postoperative day (POD) and feeds were tolerated on the third POD. The patient could eat solid food on the fifth POD and was discharged on the eighth POD. The delay in discharge was due to his poor general condition. He remained asymptomatic at home till he was readmitted ten weeks later

with terminal disease related to the distant metastases. He was still able to tolerate liquid feeds at that time. He expired shortly after admission.

DISCUSSION

Palliation for advanced gastric carcinoma, either by resection or bypass, is associated with high morbidity and mortality^(1,2). Prolongation of hospitalisation from operative morbidity deprives the patient of time spent at home and thus undermines the purpose of the surgery. Lo et al⁽²⁾ reported a mean of 6.5 days before diet was tolerated and an average hospitalisation of 13.3 days after conventional gastrojejunostomy. Recent advances in laparoscopic surgery have enabled us to perform gastrojejunostomy with minimal trauma to the patient. The advantages were reflected in the rapid recovery of the patient. The main disadvantage was the cost of the disposable instruments which was about S\$1,500.

In the case of advanced but resectable tumours without metastases, laparoscopic Billroth II gastrectomy is also technically possible⁽³⁾. Both procedures, however, are under evaluation and should only be performed under a strict prospective audit.

REFERENCES

1. Ekblom GA, Gleystean JJ. Gastric malignancy: resection for palliation. *Surgery* 1980;88:476-81.
2. Lo NN, Kee SG, Nambiar R. Palliative gastrojejunostomy for advanced carcinoma of the stomach. *Ann Acad Med Singapore* 1991;20:356-8.
3. Goh PMY, Tekant Y, Kum CK, Isaac J, Ngoi SS. Totally Intraabdominal Laparoscopic Billroth II Gastrectomy. *Surge Endosc* 1992;6:160.