

## A YOUNG MAN WITH BROAD-COMPLEX TACHYCARDIA

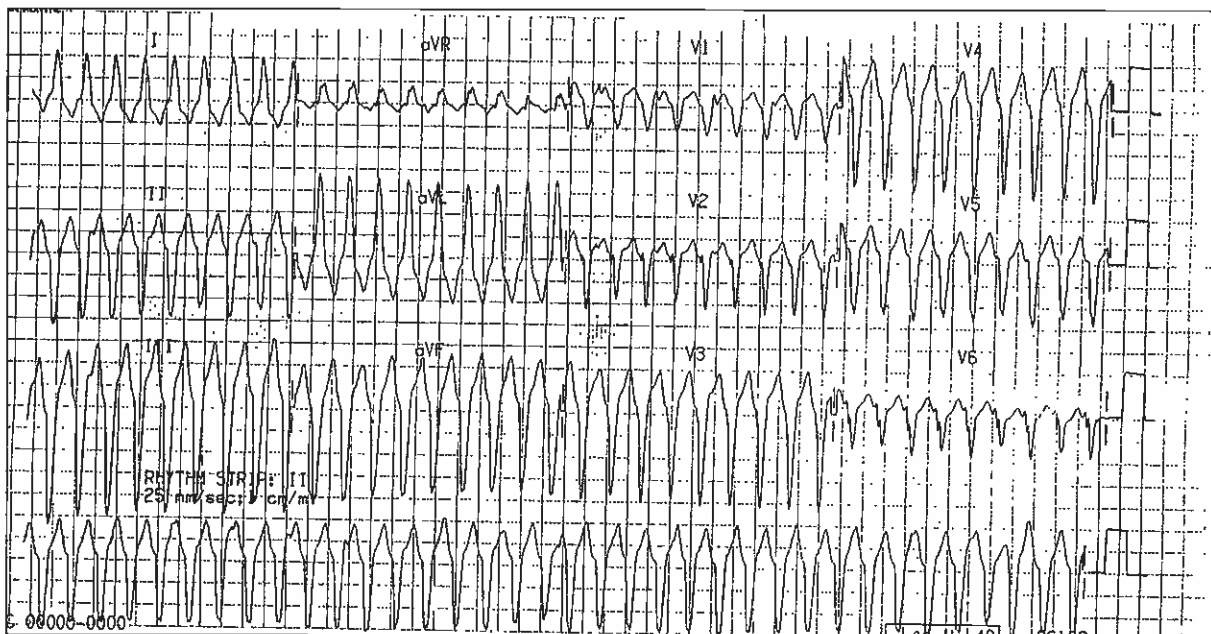
S T Lim, W S Teo

SINGAPORE MED J 1995; Vol 36: 88-89 & 117

### CASE REPORT

SSG, a 25-year-old previously healthy Chinese male, presented with palpitation and giddiness which came on immediately after a soccer game. His 12-lead ECG recorded in Accident and Emergency Department is shown in Fig 1. Another 12-lead ECG during sinus rhythm is shown in Fig 2. What is your diagnosis? (Answer on page 117)

Fig 1 – 12 lead ECG recorded at the A&E Dept



---

Department of Cardiology  
Singapore General Hospital  
Outram Road  
Singapore 0316

S T Lim, MBBS, M Med (Int Med), MRCP (UK)  
Registrar

W S Teo, MBBS, M Med (Int Med), MRCP (UK), FAMS  
Consultant

Correspondence to: Dr W S Teo

---

Fig 2 – ECG during sinus rhythm

