

# THE ABDOMINAL COCOON: A CASE REPORT

Kyaw Kyaw

## ABSTRACT

A 15-year-old Chinese girl, with abdominal cocoon, is reported. The literature (in English) concerning the condition was reviewed. Also, a possible cause is suggested and the various terms used for this condition are discussed.

**Keywords:** abdominal cocoon, intestinal obstruction, sclerosing peritonitis

SINGAPORE MED J 1994; Vol 35: 653-654

## INTRODUCTION

First described by Foo et al<sup>(1)</sup> in 1978, abdominal cocoon is a rare condition that afflicts mostly young Asian girls of perimenarchal age. It is characterised by a fibrous membrane encasing the whole or the distal part of the small intestine like a cocoon causing intestinal obstruction. Its aetiology is still not definitely known since there is no previous history of abdominal operation, peritonitis or prolonged drug intake in all cases. Subsequent to this report there has been more reports of similar condition mostly using the same term, abdominal cocoon, while a few used different terms. We would like to present our own patient, a 15-year-old Chinese girl, with abdominal cocoon, and at the same time review the literature (in English), suggest a possible cause and clarify the various terms so as to avoid confusion in future reports.

## CASE REPORT

A 15-year-old Chinese girl was admitted in March 1992 with a one-week history of a suprapubic mass which was associated with severe colicky abdominal pain on the day of admission. She has had abdominal pain of lesser severity, off and on, for the past one month. Her menarche was at 14 years of age and has had regular menstrual periods since. She was well previously.

On examination she was afebrile. There was a definite mass in the suprapubic area about 15cm in diameter. It was tender but mobile. Otherwise, the abdomen was soft. Ultrasound studies by a gynaecologist revealed the mass to consist of both solid and cystic areas. She was admitted to the gynaecological ward with a diagnosis of twisted ovarian tumour and urgent laparotomy was done.

We were called in when the mass was found to be dilated coils of small intestine. Actually the whole of the small intestine was found to be encased by a hazy well-formed membrane. There was no free fluid. The membrane was closely adherent to the intestine without any space in between. It was also covering the transverse colon and liver above, ascending and descending colon at the sides and the pelvic organs inferiorly. Anteriorly it fused with the anterior parietal peritoneum. Greater omentum was not seen. Small intestine was short, dilated and kinked inside. The membrane was easily stripped off from the serosal layer of small intestine releasing the kinks. Incidental appendectomy was also done.

Except for delay in tolerating oral feeding, which was possible on the 5th postoperative day, the recovery was

uneventful. She was discharged on the 9th postoperative day and was found to be free from abdominal pain up to the last follow-up.

Pathological report of the membrane came back as poorly cellular fibrous connective tissue. Appendix showed periappendicitis.

## DISCUSSION

After Foo et al<sup>(1)</sup>, a few more cases with similar condition have been reported, altogether adding up to twenty-three cases, including ours. Except for two male patients<sup>(2,3)</sup> and a 4-year-old girl from India<sup>(4)</sup>, the rest are young girls within the narrow age range of 12 to 18 years. Among the girls, all except three<sup>(5-7)</sup> are Asians (Table I). Apart from a girl who underwent appendectomy nine months before<sup>(5)</sup>, all have no previous history of peritonitis.

All presented as intestinal obstruction and/or abdominal mass necessitating laparotomy ultimately. Typical operative finding is that of a well-formed membrane covering or encasing the small intestine like a cocoon, causing kinks, leading to intestinal obstruction. The membrane has variable extensions laterally, superiorly and inferiorly. Stripping that membrane from the intestine is usually easy. The absence of greater omentum is recorded in two other cases<sup>(3,8)</sup>. Pathological examination reveals the membrane to be fibro-collagenous tissue with variable inflammatory reaction. Simple lysis of adhesions relieving the kinks is the effective treatment for this condition.

Table I – Reported cases of abdominal cocoon<sup>(12)</sup>

Reference	Cases (no.)	Age (yr)	Race	Sex	Months since menarche
1	10	13-18	Chinese 8 Malay 2	F F	4-24
5	1	12	Caucasian	F	not mentioned
6	1	12	Caucasian	F	not mentioned
7	1	14	? Arab	F	premenarche
8	1	15	Pakistan	F	premenarche*
12	1	17	? Nigerian	F	24
Present	1	15	Chinese	F	12
3	5	13-15	Chinese 2 Indian 2	F F	6-24
		43	Chinese	M	not applicable
4	1	4	Indian	F	premenarche
2	1	35	? Israelis	M	not applicable

\* Having symptoms before menarche

Aetiology of this condition is still not known, although there is some similarity between this and sclerosing encapsulating peritonitis (SEP), found in patients having LeVeen shunt, practolol and continuous ambulatory peritoneal dialysis<sup>(9,10)</sup>,

Department of Surgery  
University Hospital (USM)  
15990 Kelantan  
Malaysia

Kyaw Kyaw, FRCSEd  
Clinical Specialist

except for the fact that it is more severe in SEP. Retrograde menstruation as suggested by the original authors<sup>(1)</sup> is unlikely since there are two teenage girls before menarche<sup>(7,8)</sup>. Congenital anomaly is also not likely as almost all cases are in their teens. The most accepted postulation in subclinical viral peritonitis from transfallopian migration. To this we would like to add congenital absence of greater omentum as a predisposing factor. This makes the peritoneal cavity prone to infection with less virulent organism without inciting frank peritonitis.

As for nomenclature, the first authors<sup>(1)</sup> named it as abdominal cocoon. Misnomer by Sayfan et al<sup>(6)</sup> as peritoneal encapsulation is clarified by Sieck et al<sup>(7)</sup> in their report of an abdominal cocoon and a peritoneal encapsulation. Idiopathic sclerosing peritonitis is used in two reports<sup>(2,5)</sup> – one in a man and the other in a girl. Under the heading of sclerosing peritonitis, Ellis<sup>(11)</sup> mentioned the condition of abdominal cocoon. Cambria et al<sup>(9)</sup> use the term “the abdominal cocoon syndrome” in what is supposed to be a case of SEP.

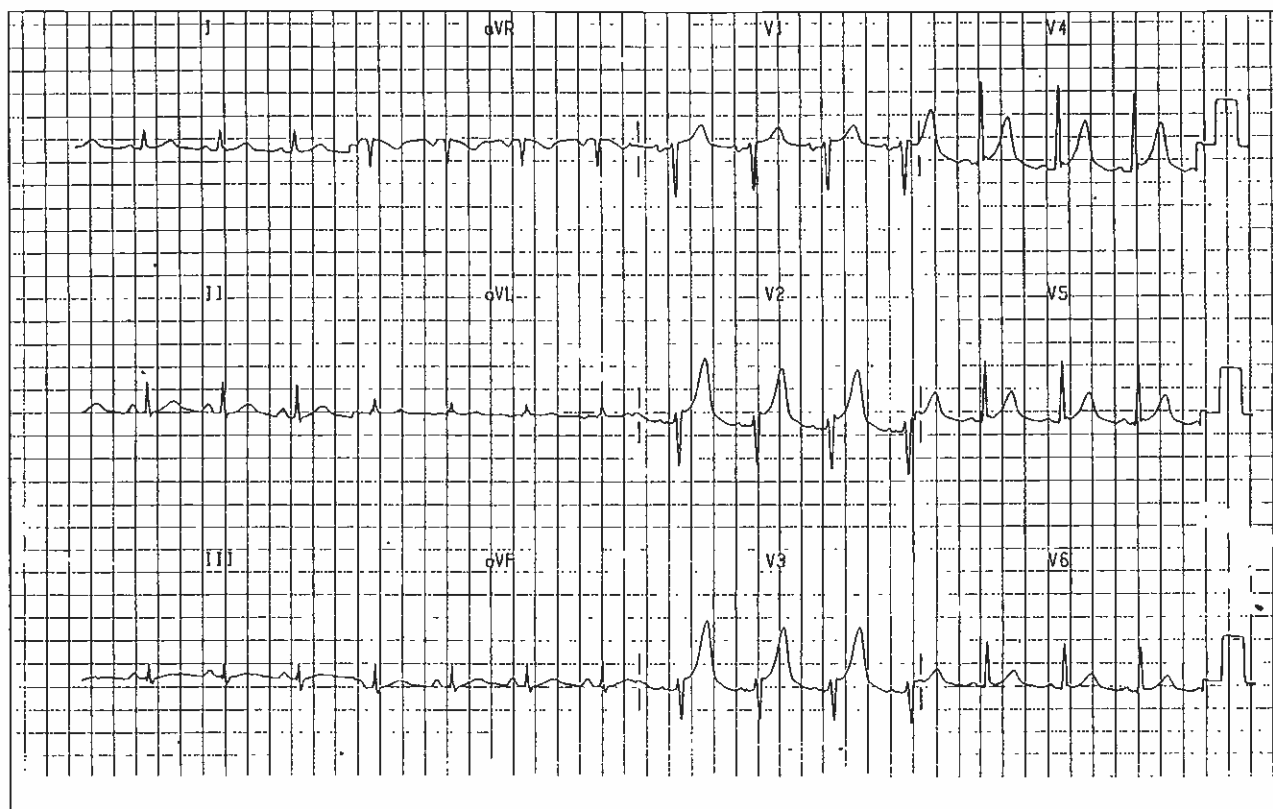
All these conditions may be due to the same aetiological agent occurring in different sets of patients with different predisposing factors. But for the time being to avoid confusion

we would like to suggest that the term “abdominal cocoon” be used as advocated by the first authors<sup>(1)</sup>.

#### REFERENCES

1. Foo TK, Ng KC, Rauff A, Foong WC, Sinniah R. Unusual small intestinal obstruction in adolescent girls: the abdominal cocoon. *Br J Surg* 1978; 65:427-30.
2. Burstein M, Galun E, Ben-Chetrit E. Idiopathic sclerosing peritonitis in a man. *J Clin Gastroenterol* 1990; 12:698-701.
3. Yip FWK, Lee SH. The abdominal cocoon. *Aust NZ J Surg* 1992; 62:638-42.
4. Rao PLNG, Mitra SK, Pathak IC. Abdominal cocoon – a cause of intestinal obstruction in a 4-year-old girl. *Indian Pediatr* 1979; 16:1047-8.
5. Dehn TCB, Lucas MG, Wood RFM. Idiopathic sclerosing peritonitis. *Postgrad Med J* 1985; 61:841-2.
6. Sayfan J, Adam YG, Reif R. Peritoneal encapsulation in childhood. *Am J Surg* 1979; 138:725-7.
7. Sieck JO, Cowgill R, Larkworthy W. Peritoneal encapsulation and abdominal cocoon. *Gastroenterology* 1983; 84:1597-601.
8. Macklin J, Hall C, Feldman MA. Unusual cause of small bowel obstruction in adolescent girls: the abdominal cocoon. *J R Coll Surg Edinb* 1991; 36:50-2.
9. Cambria RP, Shamberger RC. Small bowel obstruction caused by the abdominal cocoon syndrome: Possible association with LeVeen shunt. *Surgery* 1984; 95:501-3.
10. Kitter DS, Korpe SW, Raytch RE, Smith GW. Surgical aspects of sclerosing encapsulating peritonitis. *Arch Surg* 1990; 125:1626-8.
11. Ellis H. Special forms of intestinal obstruction. In: Schwartz SI, Ellis H, eds. *Maingot's abdominal operations*. 9th ed. Connecticut: Appleton & Lange, 1990:905-32.
12. Marinho A, Adelusi B. The abdominal cocoon. Case report. *Br J Obstet Gynaecol* 1980; 87:249-50.

Fig 3 – 12 lead electrocardiogram of the patient after catheter ablation



#### ANSWER TO ELECTROCARDIOGRAPHIC CASE

**Diagnosis:** Wolff-Parkinson-White syndrome with atrial flutter-fibrillation.

#### DISCUSSION

Fig 1 shows the presence of an irregular non-sustained broad QRS complex tachycardia (rate up to 220/min) of right bundle-branch block morphology and left axis. This is superimposed on sinus rhythm which has a slurred onset of R wave suggestive of a delta wave seen in complex 5,6 and 13 of the lead II rhythm strip at the bottom of Fig 1. The broad complexes are caused by atrial fibrillation/flutter with antegrade conduction over the accessory pathway.

Wolff-Parkinson-White (WPW) syndrome occurs when accessory atrio-ventricular connections composed of working myocardial fibres outside the specialised conducting tissue allow pre-excitation of the ventricle, causing symptoms due to tachyarrhythmias. Three features typify the ECG abnormalities of patients with the usual form of WPW syndrome: (i) PR interval <120ms during sinus rhythm; (ii) QRS duration >120ms with a slurred, slowly rising onset of QRS in some leads (delta wave); and (iii) secondary ST-T wave changes directed opposite to the major delta/QRS vectors<sup>(1)</sup>. The most common tachycardia associated with the WPW syndrome is characterised by a normal QRS, rates of 150 to 250 beats/min, and sudden onset and termination. The mechanism is macro-reentry caused by antegrade conduction over the AV node-His bundle and retrograde conduction over the accessory pathway (orthodromic AV reciprocating tachycardia). In patients with pre-excitation, wide-QRS tachycardias can be caused by multiple mechanisms:

(i) atrial flutter or atrial fibrillation (AF) with antegrade conduction over the accessory pathway, (ii) orthodromic reciprocating tachycardia with pre-existing or functional bundle branch block, (iii) antidromic reciprocating tachycardia, (iv) AV reentrant or AV nodal reentrant tachycardia with bystander accessory pathway conduction, or (v) ventricular tachycardia<sup>(2)</sup>. In this patient, the last four causes are unlikely because of the marked irregularity of the rhythm.

Digoxin has been reported to shorten refractoriness in the accessory pathway and speed the ventricular response in patients with atrial fibrillation; there have also been reports of ventricular fibrillation after digoxin. It is therefore not advisable to use digoxin as a single drug in patients with WPW syndrome who have or may develop atrial flutter or fibrillation. In patients with AF or flutter, drugs that prolong refractoriness in the accessory pathway, often coupled with drugs that prolong AV node refractoriness (eg procainamide) must be used. Class III drugs, eg amiodarone, which has an effect on both areas, can also be used. If the ventricular response is very rapid and haemodynamic instability ensues, cardioversion is the initial treatment of choice. Termination of an orthodromic reciprocating tachycardia (ie narrow QRS, regular R-R) should be approached as for AV nodal reentry. This patient was given intravenous flecainide, a class Ic antiarrhythmic agent<sup>(3)</sup>; however the patient developed a very rapid tachycardia (Fig 2: rate 225 beats/min) as a result of 1:1 conduction of atrial flutter over the accessory pathway. His blood pressure dropped to 80mmHg systolic during this tachycardia. This illustrates the danger of proarrhythmia in the use of antiarrhythmic drugs, ie precipitation of more tachycardias by the use of drugs. The tachycardia was pace-terminated.

## MANAGEMENT

Patients with pre-excitation who are completely asymptomatic may not require electrophysiological study (EPS)<sup>(4,5)</sup> or therapy. However if symptoms are frequent or significant, then therapy should be initiated. Three options exist: (i) Drugs to prolong conduction time and/or refractoriness in the AV node, accessory pathway or both; (ii) catheter ablation; and (iii) surgical ablation. Our patient underwent successful radiofrequency ablation of a left posterolateral accessory pathway. His ECG (Fig 3) post-ablation showed no more pre-excitation.

## REFERENCES

1. Wellens HJJ, Brugada PC, Penn OC, Gorgales AP, Smeets J. Pre-excitation syndromes. In: Zipes D, Jalife J. eds. *Cardiac Electrophysiology: From Cell to Bedside*. Philadelphia, USA: W B Saunders Company 1990: 691-702.
2. Prystowsky EN, Packer DL. Pre-excited tachycardias. In: Zipes D, Jalife J. eds. *Cardiac Electrophysiology: From Cell to Bedside*. Philadelphia, USA: W B Saunders Company 1990: 475-9.
3. Kim SS, Smith P, Ruffy R. Treatment of atrial tachy-arrhythmias and preexcitation syndrome with flecainide acetate. *Am J Cardiol* 1988; 62:29 D
4. Sharma AD, Yee R, Guiraudon G, Klein GJ. Sensitivity and specificity of invasive and non-invasive testing for risk of sudden death in WPW syndrome. *J Am Coll Cardiol* 1987; 10:373-5.
5. Klein GJ, Yee R, Sharma AD. Longitudinal electro-physiological assessment of asymptomatic patients with WPW electrocardiographic pattern. *N Engl J Med* 1989; 320:1229-35.