

ELECTROCARDIOGRAPHIC CASE

A MAN WITH DILATED CARDIOMYOPATHY AND A SLOW HEART RATE

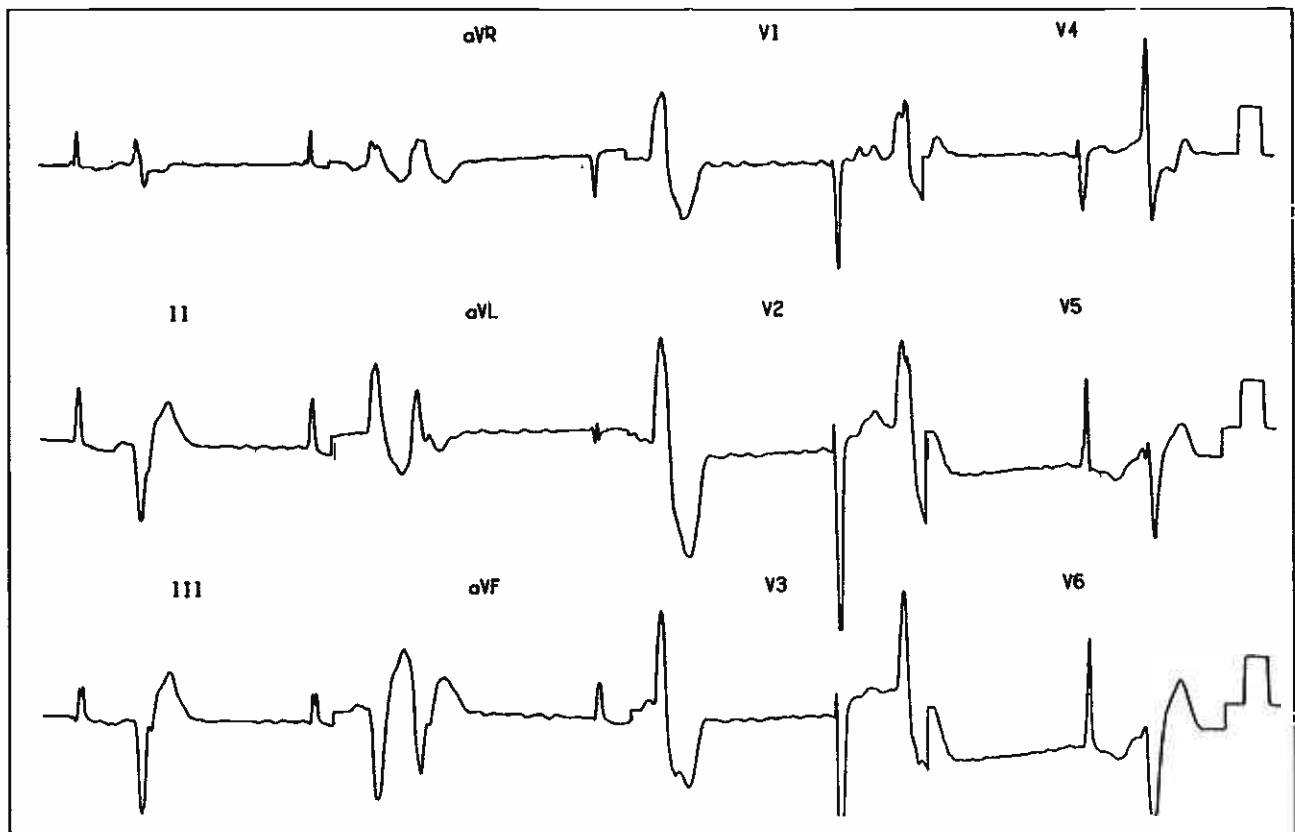
P P Goh, W S Teo

CASE HISTORY

A 45-year-old man with a 2-year history of exertional dyspnoea was diagnosed to have dilated cardiomyopathy. He was treated with frusemide, potassium supplement and digoxin with symptomatic improvement. However, on outpatient follow-up, he was found to have a bizarre-looking electrocardiogram (Figs 1a and 1b). What is your diagnosis? (Answer on Page 327)

SINGAPORE MED J 1994; Vol 35: 312-313 & 332

Fig 1a – 12-lead electrocardiogram at presentation



Department of Cardiology
Singapore General Hospital
Outram Road
Singapore 0316

P P Goh, MBBS, MRCP (UK)
Registrar

W S Teo, MBBS, M Med(Int Med), MRCP (UK), FAMS
Consultant

Correspondence to: Dr W S Teo

Fig 1b – Rhythm strip

