

RADIOLOGICAL DIAGNOSIS OF ACCIDENTAL OESOPHAGEAL INTUBATION

Y K Chan

ABSTRACT

Oesophageal intubation is rapidly fatal if not recognised. We report a patient who not only survived an oesophageal intubation but who had chest X-rays taken which showed an oesophageal intubation which was initially recognised by the attending physician.

Keywords: oesophageal intubation, radiological diagnosis.

SINGAPORE MED J 1994; Vol 35:327-328

INTRODUCTION

Successful endotracheal intubation ordinarily entails laryngoscopy, placement of the tracheal tube and subsequently ensuring that it has not been placed in the oesophagus or bronchus. Failure to diagnose oesophageal intubation is immediately fatal if the patient has no spontaneous respiration. Methods used to diagnose oesophageal intubation⁽¹⁾ are hence methods which produce confirmation of tube placement within seconds of the intubation. We describe here a radiological diagnosis which is definitely not a routine method for excluding oesophageal intubation as this does not confer rapid diagnosis.

CASE REPORT

An 83-year-old Indian man was admitted with a complaint of breathlessness on the evening of admission. He was an asthmatic on regular terbutaline inhaler and was known to have ischaemic heart disease treated with glyceryl trinitrate and isosorbide dinitrate. On examination he was dyspneic, cold, clammy and had rhonchi bilaterally. A diagnosis of asthma with a differential diagnosis of pulmonary oedema was made. Nebulised bronchodilators were administered but in spite of therapy he deteriorated and was taken to the resuscitation room, where he was 'intubated' and ventilated with an Air-viva bag with 15 litres of oxygen. A blood gas done following this showed persistent hypoxia and hypercarbia (pO_2 5 kpa, pCO_2 11.8 kpa, HCO_3 22.6, pH 7.02, BE-11.3). A chest X-ray (Fig 1) was also done. The patient was then referred to the anaesthetist.

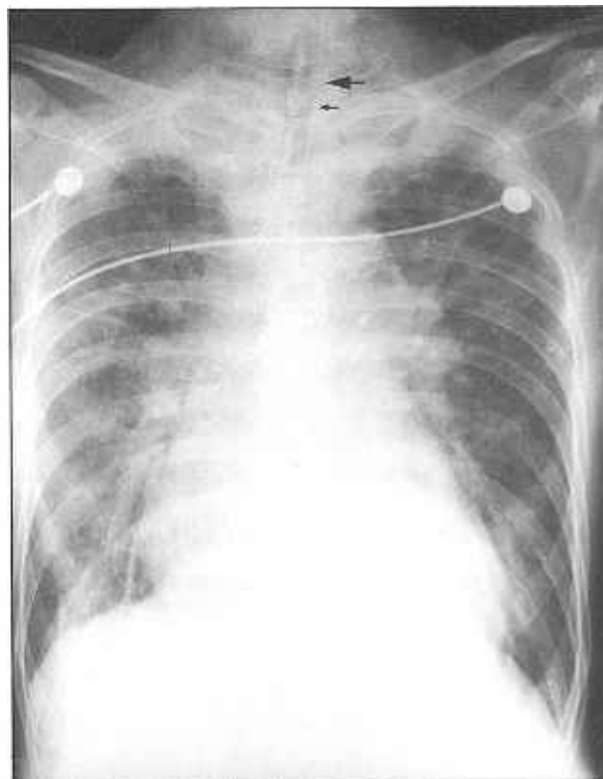
Assessment by the anaesthetist whilst the patient was still in the resuscitation room revealed that chest movement was minimal and breath sounds were inaudible with ventilation. At laryngoscopy the tube was not in the trachea. It was estimated that the tube had been in the oesophagus for at least half an hour before the misplacement was discovered. The tube was removed and the patient correctly reintubated. Reexamination of the chest X-ray substantiated our initial suspicion of an oesophageal intubation. A blood gas done subsequently revealed adequate oxygenation and a normalisation of his pCO_2 . He was admitted to the Intensive Care Unit where he had an uneventful recovery.

DISCUSSION

It is routine practice to perform a chest X-ray after tracheal intubation to ensure optimal intratracheal intubation, that is, with

the tip 5 to 7 cm above the carina⁽²⁾. Very often chest X-rays are the only means of diagnosing unintentional endobronchial intubation. They are never taken to differentiate intratracheal and oesophageal intubation.

Fig 1 – Chest X-ray of the patient showing oesophageal intubation. The outline of the endotracheal tube (big arrow) is beyond the opacity of the tracheobronchial column (small arrow) in the proximal part of the trachea.

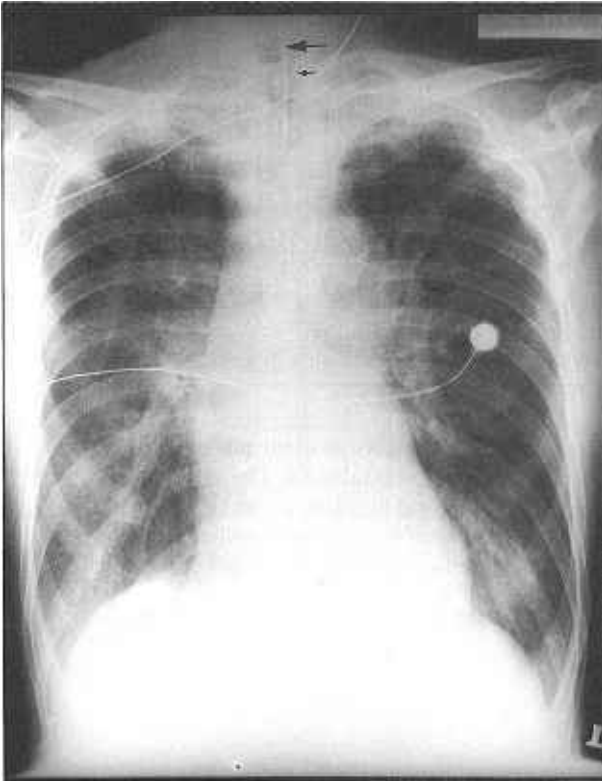


However, if oesophageal intubation is present, it is not difficult to diagnose its presence in the chest X-ray. The outline of the endotracheal tube is beyond the opacity of the tracheobronchial column. It must be emphasised that the outline of a correctly placed cuffed endotracheal tube will be centrally placed in the tracheobronchial column sitting parallel to the long axis of the trachea (Fig 2). Batra et al⁽³⁾ who similarly reported an oesophageal intubation that was evident from the chest X-ray noted that all the attending physicians interpreted the distal deviation of the tube as endobronchial intubation even though the distal end was not centrally placed in the bronchus.

Department of Anaesthesiology
Faculty of Medicine
University of Malaya
59100 Kuala Lumpur
Malaysia

YK Chan, FFARCSI
Lecturer

Fig 2 – Chest X-ray of the patient after correct placement of the tube. The tube (big arrow) is centrally placed in the tracheobronchial column (small arrow) sitting parallel to the long axis of the trachea.



It is interesting to speculate how the patient managed to survive the episode of oesophageal intubation. The patient was never paralysed and hence spontaneous ventilation was present throughout though inadequate. The oesophageal intubation could also have contributed minimally to the ventilation. Pollard and Junius⁽⁴⁾ demonstrated chest movement from oesophageal intubation similar to that obtained after endotracheal intubation. They found through cadaveric dissection that the chest movement was caused by the flat oesophagus distending into a firm tube which lifted the heart and upper mediastinal structures forward thus elevating the sternum and ribs. This chest movement could possibly allow movement of air into the lungs and contributed to his survival.

It should be emphasised that clinical methods of checking endotracheal intubation usually employed such as listening to air entry over the chest and stomach and compressing over the chest to determine if air exits from the endotracheal tube are not foolproof evidence of correct placement. Capnometers if available provide more reliable evidence and if it is possible to demonstrate full-sized capnograms even after a few tidal breaths it is almost foolproof that the tube is in the trachea and not the oesophagus. If capnometers are not available and if there is any doubt that the tube is not correctly placed, one should remove it and commence manual face mask ventilation without delay.

REFERENCES

1. Birmingham PK, Cheney FW, Ward RJ. Oesophageal intubation: A review of detection techniques. *Anaesth Analg* 1986; 65: 886-91.
2. Jacobson HG, Heitzman ER. Radiological evaluation of patients receiving assisted ventilation. *JAMA* 1981; 245: 858-60.
3. Batra AK, Lhon MA. Uneventful prolonged misdiagnosis of oesophageal intubation. *Crit Care Med* 1983; 11: 763-4.
4. Pollard BJ, Junius F. Accidental intubation of the oesophagus. *Anaesth Intensive Care* 1980; 8: 183-6.