

HDR INTRALUMINAL BRACHYTHERAPY FOR LUNG TUMOURS – A CASE REPORT

J T S Wee, E T L Yang, Y C Lim

ABSTRACT

The lung is a common site for cancer to occur, for both primary as well as metastases. The presence of such tumours can give rise to symptoms such as haemoptysis, cough, breathlessness and pneumonia. In most cases, treatment is strictly for palliation. We present a case report of a patient with an endobronchial metastasis from a primary hypernephroma which recurred following external beam radiotherapy. He was treated with a single fraction of intraluminal brachytherapy to a dose of 10Gy at 1 cm from the axis on a High Dose Rate Ir¹⁹² Remote Afterloading Machine. There were no adverse effects following treatment. On follow-up 7 months later, the patient did not have any further recurrence of breathlessness although his disease had progressed at other sites.

Keywords: lung cancer, endobronchial tumours, palliation, intraluminal radiotherapy, brachytherapy

SINGAPORE MED J 1994; Vol 35:325-326

INTRODUCTION

Tumours of the lung are common. They could be of bronchogenic origin or represent metastases from other sites. Whenever they occur, they can potentially cause distressing symptoms such as haemoptysis, cough, breathlessness and chest infections. Radiotherapy has been found useful in palliating such symptoms. However, recurrences after external beam radiotherapy present a major problem for clinicians.

We present a case report of a patient with breathlessness from a metastatic renal cell carcinoma, who was treated with intraluminal endobronchial brachytherapy with good palliation.

CASE REPORT

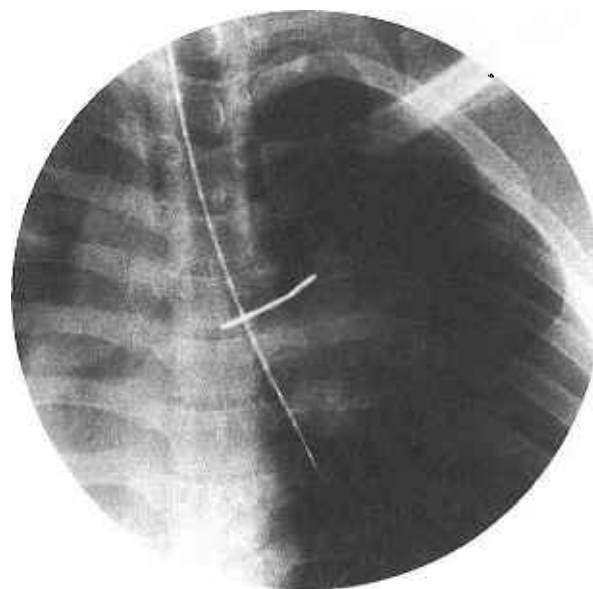
LHC (male, 32 years of age, Chinese) had a nephrectomy for renal cell carcinoma in 1982 and remained well till 1990 when he developed metastases to the right lung. This was left alone, and in July 1991 he developed progressive dyspnoea and also a local recurrence in the tumour bed. The pulmonary lesion was lasered to cause re-expansion of the lung, and the renal bed was irradiated. However, the relief was temporary, and he became breathless again, and this time received external beam radiotherapy which provided temporary respite.

We then proceeded to treat the endobronchial tumour which was the cause of his breathlessness with a single fraction of intraluminal brachytherapy, using a High Dose Rate (HDR)¹⁹²Ir source from a Gammamed remote after-loading machine. A bronchial catheter, which has an external diameter of 1.9 mm was inserted through the working channel of a flexible bronchoscope and threaded past the site of the obstruction. The bronchoscope was removed, leaving the catheter in place, and a planning radiograph (Fig 1) was taken. The treatment parameters were then loaded into a computer, an isodose distribution produced

(Fig 2) and the treatment commenced. A single dose of 10Gy at 1 cm from the catheter axis was delivered to a 6 cm length in 6.2 minutes. The patient was awake throughout the whole procedure, and tolerated it very well. There were no adverse effects following the treatment, he felt more comfortable the following day and was up and about.

The patient was last seen about 7 months after the procedure, and although his disease had progressed at other sites, there was no further recurrence of breathlessness.

Fig 1 – Planning Radiograph



Department of Therapeutic Radiology
Singapore General Hospital
Outram Road
Singapore 0316

J T S Wee, MBBS, FRCR (UK)
Senior Registrar

E T L Yang, MBBS, DMRT, FRCR (UK)
Consultant

Department of Cardiothoracic Surgery
Singapore General Hospital

Y C Lim, MBBS, FRCS, FAMS
Consultant

Correspondence to: Dr J T S Wee

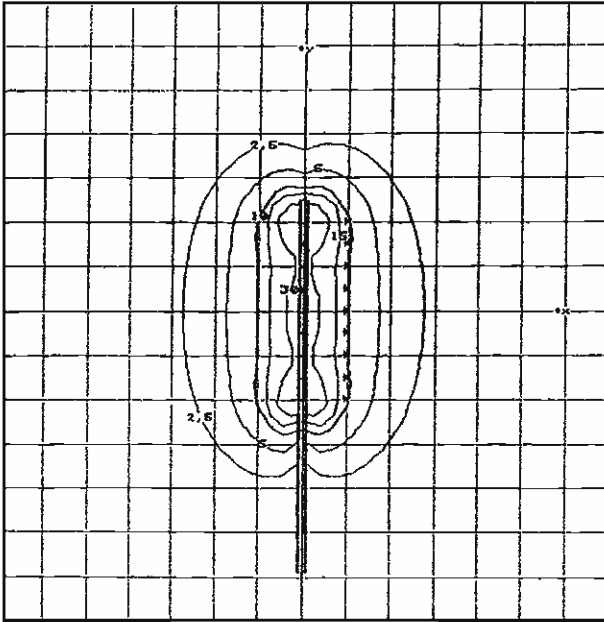
Endobronchial Brachytherapy

Brachytherapy for lung tumours has been around since 1933 when Kernan⁽¹⁾ used Radon-222 seeds to implant cancers of the trachea and bronchus via the right bronchoscope. However, brachytherapy techniques were only described⁽²⁾ in 1983. With the introduction of the neodymium-YAG laser for photo-resection of tracheal and endobronchial obstruction from malignant tumours, brachytherapy became more widely applicable.

Rowland⁽³⁾ used HDR brachytherapy as the sole modality treatment in lung cancers and reported a 70% improvement in symptomatic relief, with 7 out of 8 patients who suffered haemoptysis receiving rapid relief.

The advantages of this treatment include: very short treatment time, an outpatient procedure, good palliation to the patient, and

Fig 2 - Isodose Distribution



The basis for calculation is a short Ir-192 line source with an activity of 370 GBq (10 Ci) and a reference dose rate of 1 202mC m/hkg

Isodose values: 2.5, 5, 10, 15, 30 Gray

good protection for staff. It can also be used for previously irradiated tumours.

REFERENCES

1. Kernan JD. Carcinoma of lung and bronchus – treatment with radon implantation and diathermy. *Arch Otolaryngol* 1933; 17: 457-75.
2. Mendiõndo OA. Endobronchial brachytherapy in the treatment of recurrent bronchogenic carcinoma. *Int J Radiation Oncol Biol Physics* 1983; 9: 579-82.
3. Rowland CG, Pagliero KM. HDR Brachytherapy as the sole modality treatment in lung cancer. In: Mould RF, ed. *Brachytherapy 2*. The Netherlands: Nucletron, 1989: 489-90.