

ELECTROCARDIOGRAPHIC CASE

A PREGNANT LADY WITH NARROW COMPLEX TACHYCARDIA

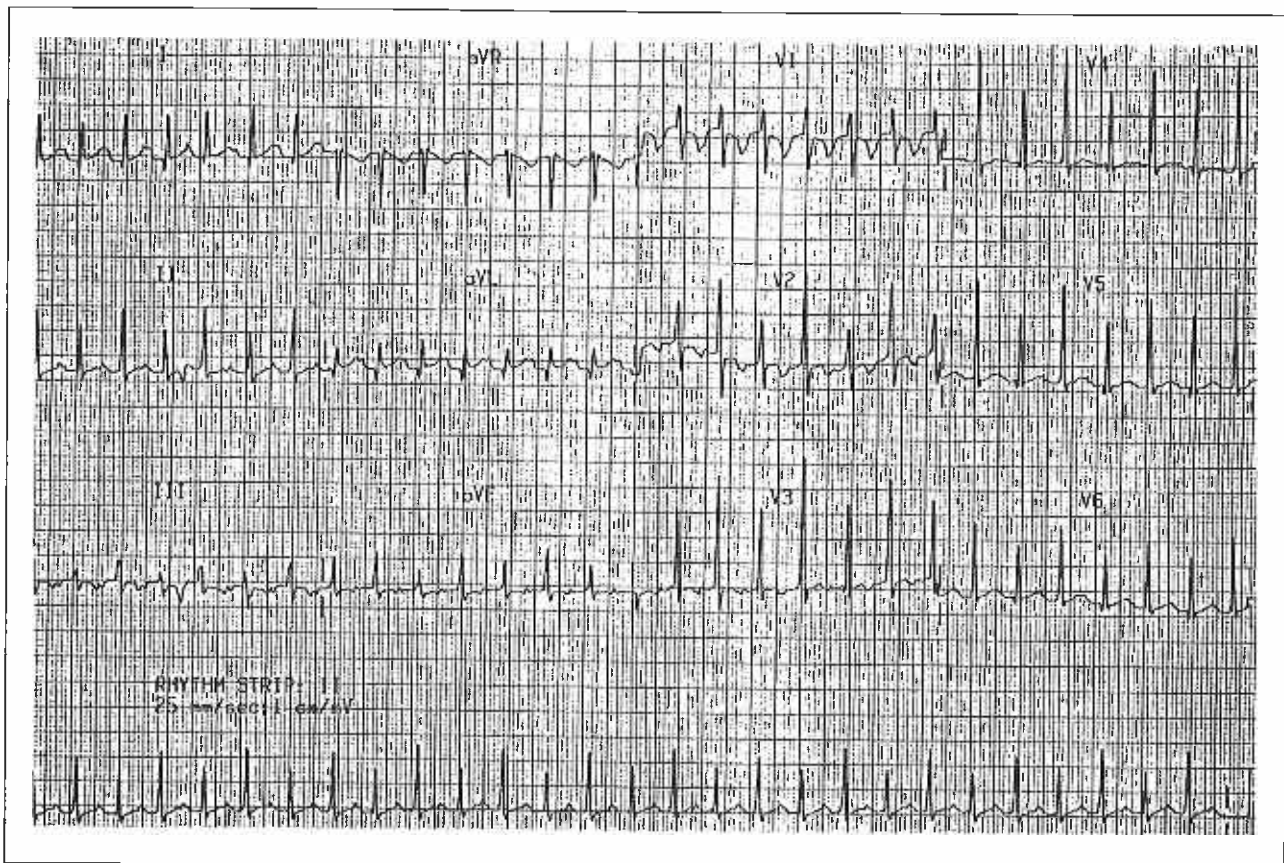
R M L Kam, C Y Lee, W S Teo

CASE HISTORY

A 32-year-old lady in her thirtieth week of pregnancy complained of palpitations after an upper respiratory tract infection one week earlier. Fig 1 shows the 12-lead electrocardiogram at the emergency room. Fig 2 shows the electrocardiogram after 5mg of intravenous verapamil was given. What is your diagnosis? (Answer on page 116-117)

SINGAPORE MED J 1994; Vol 35: 100-101 & 116-117

Fig 1 – 12-lead electrocardiogram at initial presentation.



Department of Cardiology
Singapore General Hospital
Outram Road
Singapore 0316

R M L Kam, MBBS, M Med (Int Med), MRCP (UK)
Registrar

C Y Lee, MBBS, M Med (Int Med)
Registrar

W S Teo, MBBS, M Med (Int Med), MRCP (UK), FAMS
Consultant

Correspondence to: Dr W S Teo

Fig 2 – 12-lead electrocardiogram after 5 mg of intravenous verapamil

