

TWO INTERESTING CASES OF NON-FATAL MELIOIDOSIS FROM ALEXANDRA HOSPITAL IN SINGAPORE

Y F Chiew, S W Chee, P K Mah, W L S Chew

ABSTRACT

Two cases of non-fatal infection due to *Pseudomonas Pseudomallei* are reported to describe the interesting clinical features of panophthalmitis and haemorrhagic bullae.

Keywords: panophthalmitis, haemorrhagic bullae, melioidosis

SINGAPORE MED J 1994; Vol 35: 77-78

INTRODUCTION

Melioidosis is an important infectious disease because it affects many parts of the world⁽¹⁾ and had a high mortality rate of about 45%⁽²⁾.

The disease was first recognised in 1911 by Whitmore and Krishnaswamy in Rangoon⁽³⁾. Sporadic reports followed and gradually became more frequent especially from endemic areas in Southeast Asia and Northern Australia. The actual number of cases also increased dramatically and Thailand is an example of such an increase. The first report in a Thai patient was in 1955 and there was no other case report until 1976 when 10 cases were presented⁽⁴⁾. At the the National Workshop in Melioidosis in Bangkok in 1985, more than 700 Thai cases were discussed. The increase could be attributed to (i) an improvement in bacteriological and clinical detection, or (ii) there could be a real increase in recent years, or (iii) a combination of both (i) and (ii).

In Singapore, the first report was made by Gilmour in 1931⁽⁵⁾. Thin et al in 1970 reported 10 cases of which one came from Singapore⁽⁶⁾. Chan⁽⁷⁾ in 1985 and Wei⁽⁸⁾ in 1989 reported altogether 5 fatal cases of melioidosis.

The two interesting cases were obtained from Alexandra Hospital which is a government-funded hospital with 430 beds. Indeed there has been a dramatic increase of melioidosis in recent years throughout Singapore as observed by Tan⁽⁹⁾.

Microbiology Division
Department of Laboratory Medicine
National University Hospital
Lower Kent Ridge Road
Singapore 0511

Y F Chiew, MBBS, M Med (Int Med), FCCP
Senior Registrar

Ang Mo Kio Community Hospital
17 Ang Mo Kio Ave 9
Singapore 2056

S W Chee, MBBS
Medical Officer

Department of Medicine
Alexandra Hospital
Alexandra Road
Singapore 0314

P K Mah, MBBS (Syd), MRACP, FRACP
Consultant Physician

W L S Chew, MBBS, FRACP, MRACP
Head

Correspondence to: Dr Y F Chiew
Dept of Medical Microbiology
The London Hospital Medical College
Turner Street
London E1 2AD
England

CASE REPORTS

Case 1

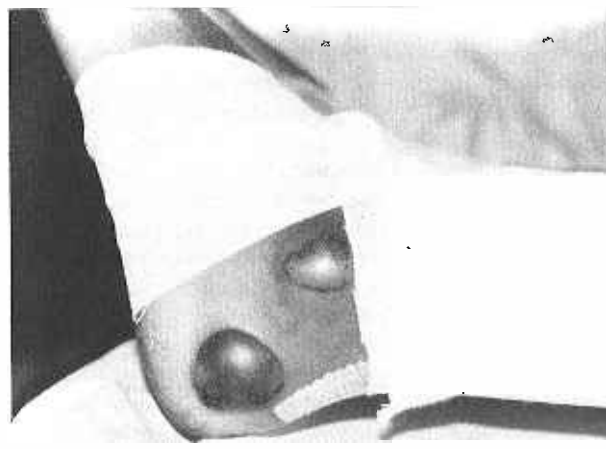
A 51-year-old Chinese tour guide to Thailand was admitted in June 1987 with complaints of 8 days of fever and weight loss. He was a known diabetic of 9 years on regular oral hypoglycemic medication. Clinical examination revealed a toxic looking man with few pustules over his face, trunk and prepuce. There was leucocytosis of $14.6 \times 10^9/l$ and chest X-ray showed early right middle lobe pneumonia. Ampicillin and gentamicin were prescribed on Day 1 of admission for community-acquired pneumonia. This was changed to ceftazidime and crystalline penicillin on Day 3 when there was no improvement in the fever. On Day 3 the patient complained of right-sided visual disturbance. An eye surgeon diagnosed right metastatic panophthalmitis. There were striae in the cornea, an hypopyon in the anterior chamber and severe conjunctivitis.

Repeat chest X-ray on Day 6 showed bilateral widespread nodular shadows with cavitations and right hemidiaphragm. There was severe hypoproteinemia of 4.5g/dl and albumin of 1.7g/dl. Blood and pus cultures on Day 1 grew *P. Pseudomallei*. The dose of ceftazidime was increased to 2 gm 8 hourly and crystalline penicillin was changed to piperacillin. The radiological abnormalities cleared up over 6 weeks. Unfortunately severe right visual disturbance persisted.

Case 2

A 17-year-old Chinese female student was admitted in July 1990. She had daily low grade fever of one month duration and 2 days of rash. During hospitalisation, tender erythematous papules were noted over the legs. The same lesions developed into fluctuant pustular nodules and finally haemorrhagic bullae (Fig 1). New and similar lesions appeared on the elbows, left forearm and nape. Mild pallor was also noted.

Fig 1 - Haemorrhagic bullae on the leg of Case 2



Haemoglobin was 7.8 gm/dl, reticulocyte count 3.4% and blood film showed microcytosis and hypochromia. Haemoglobin electrophoresis confirmed beta thalassaemia minor. Skin biopsy demonstrated abscess. Bacterial cultures were negative. Numerous serological tests for unusual infections were sent out and amongst these IgM-IHA for *P. Pseudomallei* titre was 5000 on Day 8. Ceftazidime was started on Day 7 for 17 days followed by oral tetracycline for four months. The lesions healed with minimal scarring.

DISCUSSION

Two cases of melioidosis with unusual manifestations from Alexandra Hospital in Singapore were studied retrospectively. Both had underlying medical conditions – diabetes mellitus (Case 1) and beta thalassaemia minor (Case 2). The source of infection probably came from Singapore. Thin et al⁽¹⁰⁾ in 1971 found *P. Pseudomallei* in the surface water of Singapore.

The outcome of the disease was closely associated with the clinical presentation of the patient⁽²⁾. Case 1 had bacteraemic disseminated disease but it was restricted to the lungs, right eye and few pustules over the body and he survived. Case 2 had probable disease because she had fever lasting at least 14 days and a positive serologic test without a detectable infectious site and negative blood cultures.

The two cases described illustrate the protean behaviour of melioidosis and hence the difficulty in diagnosis. A high index of suspicion confirmed by bacteriological isolation and supported by serological identification is necessary for the diagnosis of melioidosis.

REFERENCES

1. Dance DAB. Melioidosis: the tip of the iceberg? Clin Microbiol Rev 1991; 4:52-60.
2. Punyagupta S. Melioidosis: Review of 686 cases and presentation of a new clinical classification. In: Punyagupta S, Sirisanthana T, Stapatayavong B. eds. Melioidosis - Proceedings of National Workshop on melioidosis. Thailand: Bangkok Medical Publisher. 1989: 217-29.
3. Whitmore A, Krishnaswami CS. An account of disease of a hitherto undescribed infective disease occurring among the population of Rangoon. In Med Gaz 1912; 47: 262-7.
4. Punyagupta S, Attasampunna P, Jayanetra P, Kurathong S. Melioidosis: A medical problem among the Thai? J Med Council Thai 1976; 5: 419-35 (in Thai).
5. Gilmour CCB. A case of melioidosis in Singapore. Malayan Med J 1931; 6: 12-3.
6. Thin RNT, Brown M, Stewart JB, Garrett CJ. Melioidosis: A report of ten cases. Q J Med 1970, 39: 115-27.
7. Chan KW. Acute septicemic melioidosis: A report of 3 fatal cases. Singapore Med J 1985; 26: 382-5.
8. Wei SS. *Pseudomonas Pseudomallei* pneumonia with septicemia – case report. Singapore Med J 1989, 30: 205-7.
9. Tan AL. Melioidosis: epidemiology and antibiogram of cases in Singapore. Singapore Med J 1990; 31: 335-7.
10. Thin RNT, Groves M, Rapmund G, Mariappan M. *Pseudomonas Pseudomallei* in the surface water of Singapore. Singapore Med J 1971; 12: 181-2.