

Q WAVES IN INFERIOR LIMB LEADS - ? ACUTE MYOCARDIAL INFARCTION

S A Gunawan, W S Teo

CASE REPORT

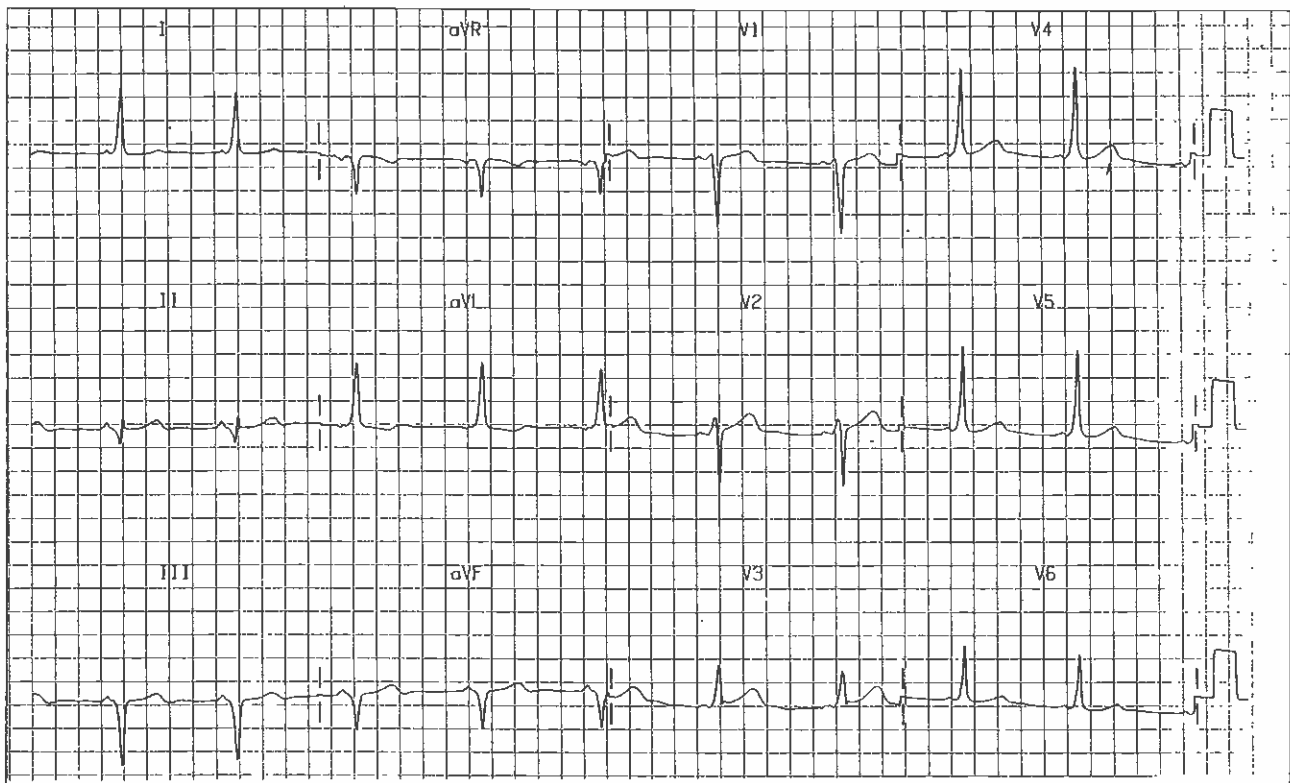
A 52-year-old female Chinese was admitted with complaints of epigastric discomfort associated with palpitations. Each episode lasted for about one hour and was associated with slight giddiness. Her main coronary risk factor was that of a history of hyperlipidaemia. The clinical examination was unremarkable. Her blood pressure was 140/90 mmHg and the pulse rate was 80 beats per minute. The examination of the heart revealed no abnormalities.

Her 12 lead electrocardiogram is shown below. What is your diagnosis?

(Answer on Page 469)

SINGAPORE MED J 1993; Vol 34: 452 & 469

Fig 1 - 12 lead electrocardiogram on admission



Department of Cardiology
Singapore General Hospital
Outram Road
Singapore 0316

S A Gunawan, MD
Registrar

W S Teo, MBBS, M Med(Int Med), MRCP(UK), FAMS
Consultant

Correspondence to: Dr W S Teo