

T WAVE INVERSION IN A WOMAN WITH GIDDINESS AND WEAKNESS

R M L Kam, W S Teo

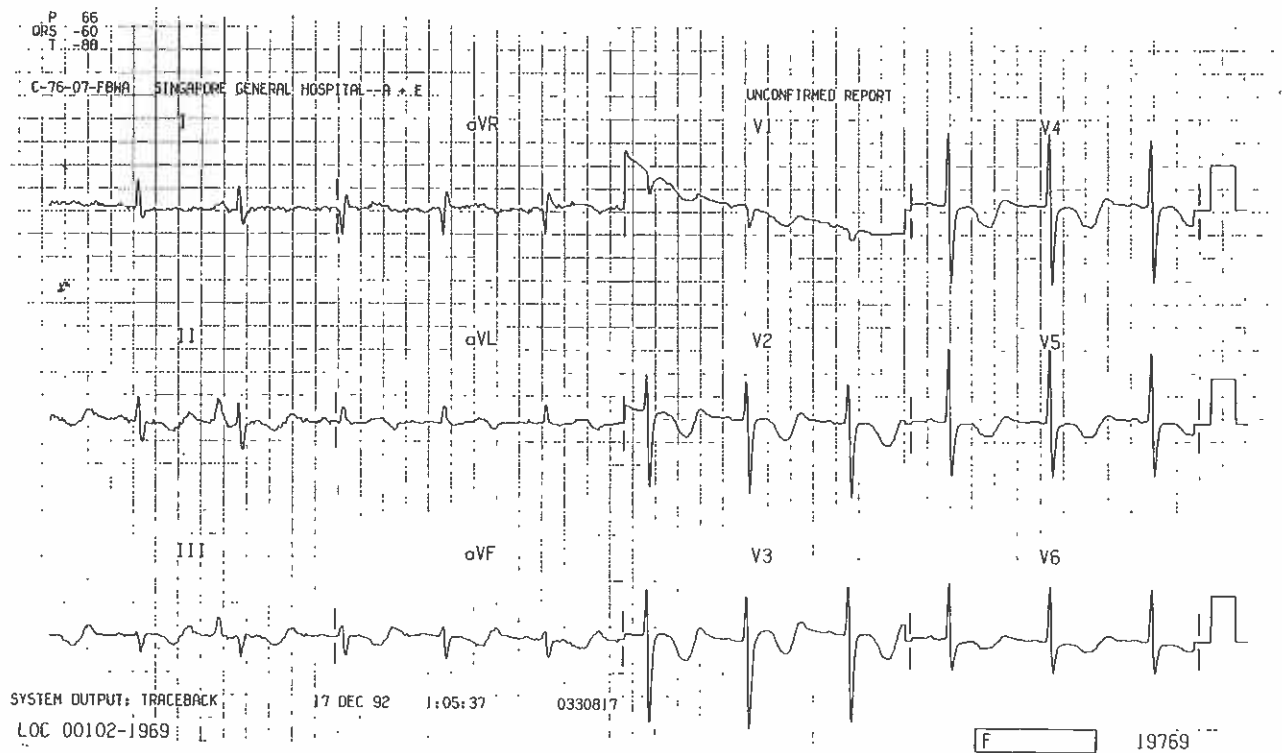
SINGAPORE MED J 1993; Vol 34: 351 & 363

CASE HISTORY

A 55-year-old woman complained of giddiness and weakness. A 12-lead electrocardiogram (Fig 1) was done. What are the

abnormalities and what should be looked for in the history? (Answer on Page 363)

Fig 1 - 12-lead electrocardiogram of the patient at initial presentation



Department of Cardiology
Singapore General Hospital
Outram Road
Singapore 0316

R M L Kam, MBBS, M Med (Int Med), MRCP (UK)
Registrar

W S Teo, MBBS, M Med (Int Med), MRCP (UK), FAMS
Consultant

Correspondence to: Dr W S Teo