

## AN UNUSUAL CAUSE OF GIDDINESS

K S Ng, M H Choo

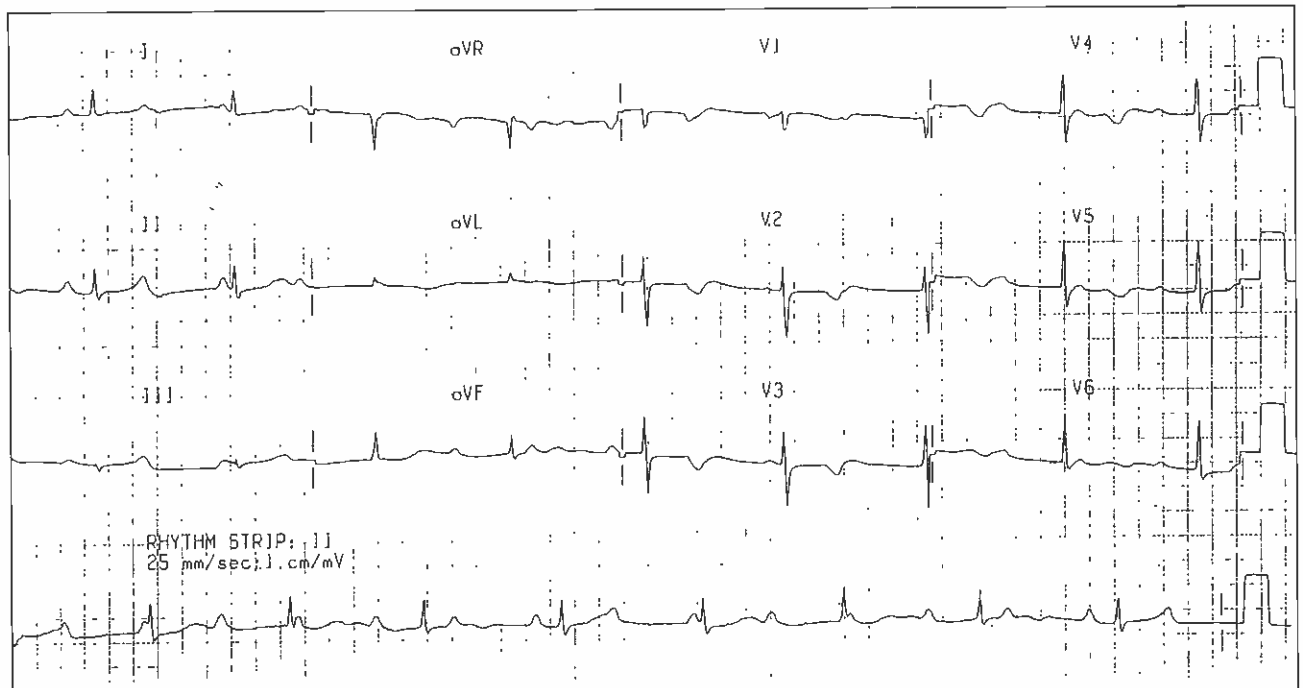
### CASE REPORT

A 46-year-old Chinese female was investigated for cardiac arrest. She had never experienced syncope, palpitations, dyspnea or angina pectoris. Apart from hypertension, there was no past history of heart disease, or family history of sudden death. On clinical examination, her general condition was satisfactory. The blood pressure was 200/95. The pulse rate was 55 beats/minute, regular. Jugular venous pressure was not elevated. There was a grade 2/6 ejection systolic murmur along the left sternal edge, and a grade 2/6 pansystolic murmur at the apex. The lungs were clear. Her first 12 lead ECG is shown in Fig 1. Subsequently, during an episode of giddiness, another ECG was done and is shown in Fig 2.

What is your diagnosis? (Answer on Page 92)

SINGAPORE MED J 1993; Vol 34: 81-82

Fig. 1 – 12 lead ECG at initial presentation



Cardiac Department  
National University Hospital  
Lower Kent Ridge Road  
Singapore 0511

K S Ng, MBBS, MRCP(UK)  
Registrar

M H Choo, M Med(Int Med), FRCP(UK)  
Chief

Correspondence to: Dr K S Ng

Fig. 2 - ECG rhythm strip at time of patient's complaint of giddiness

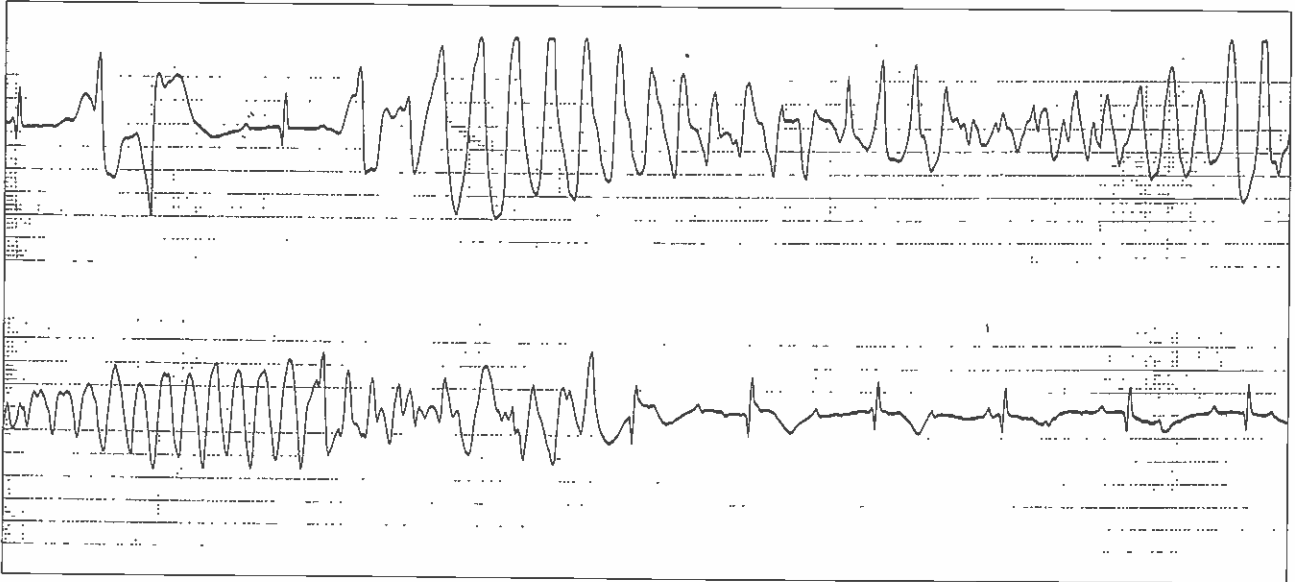


Fig. 3 - 12 lead ECG after pacemaker implant

