

# ELECTROCARDIOGRAPHIC CASE

## DIFFERENTIAL DIAGNOSES OF TALL R WAVE IN V1

R Kam, W S Teo

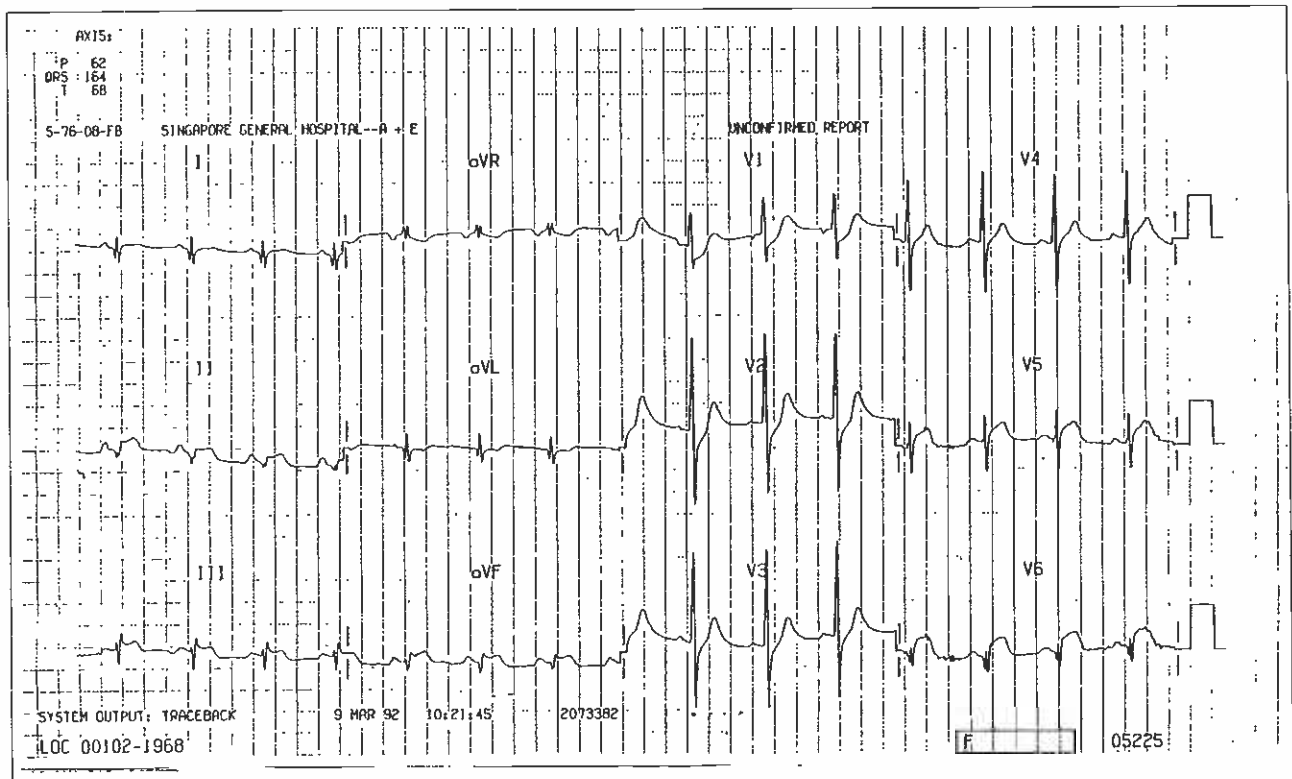
### CASE HISTORY

A 61-year-old man, who complained of chest pain threw a generalised fit while waiting at the triage area of the Accident and Emergency department. The fit lasted for 30 seconds and was over by the time he was brought to the resuscitation room. The 12 lead ECG which was done after the fit is shown in Fig 1.

What is the diagnosis? (Answer on Page 648)

SINGAPORE MED J 1992; Vol 33: 638

Fig 1 - 12 lead electrocardiogram of the patient at the Accident and Emergency department



Department of Cardiology  
Singapore General Hospital  
Outram Road  
Singapore 0316

R Kam, MBBS, MMed (Int Med), MRCP (UK)  
Registrar

W S Teo, MBBS, MMed (Int Med), MRCP (UK), FAMS  
Senior Registrar

Correspondence to: Dr W S Teo