

ELECTROCARDIOGRAPHIC CASE

WIDE COMPLEX TACHYCARDIA

W S Teo, A Tan

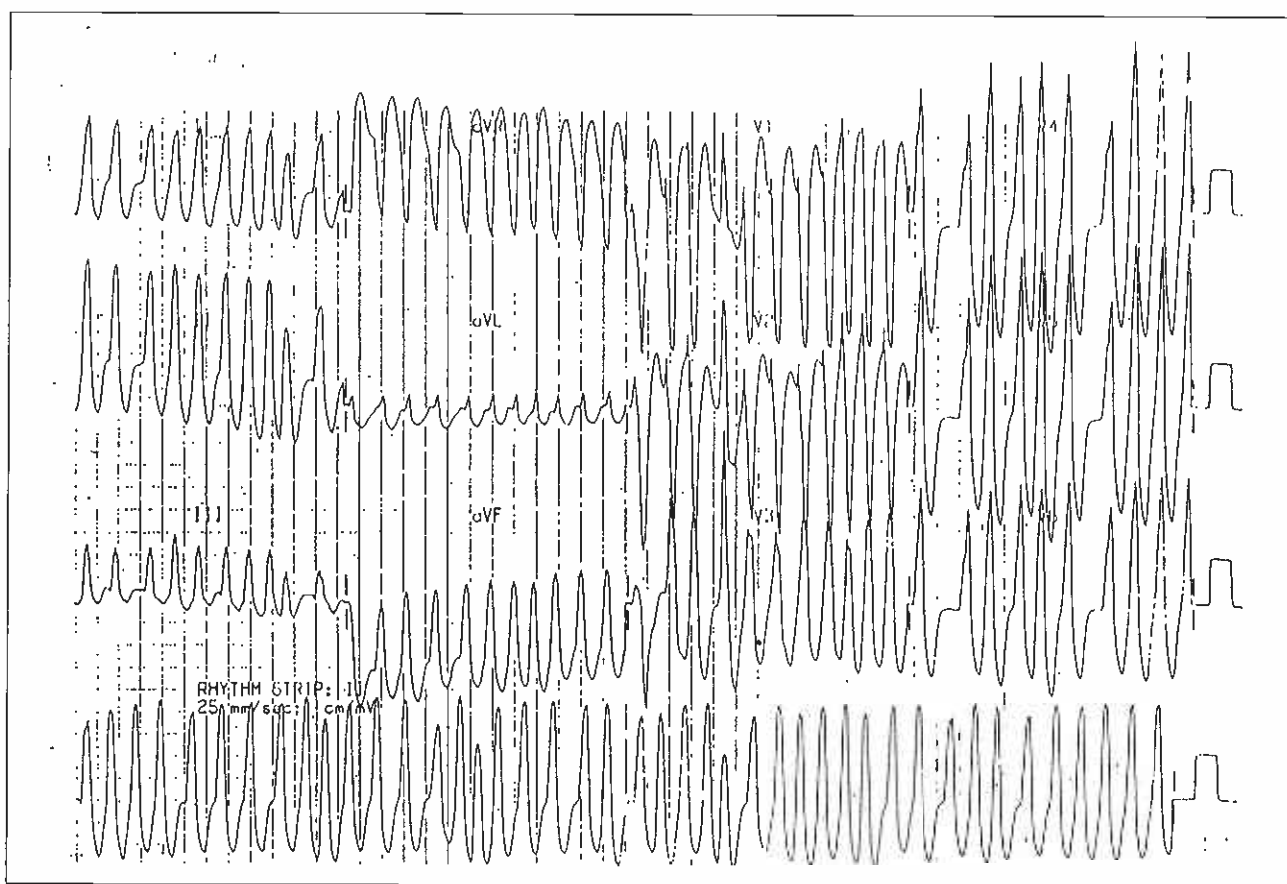
CASE REPORT

ESW, a 33-year-old male Chinese, was admitted with complaint of palpitations associated with giddiness. He had a known history of heart disease since 1978 with 6 previous admissions to the Singapore General Hospital. The palpitations will come on suddenly and was associated with breathlessness and giddiness. There was a family history of a younger brother who died suddenly at the age of 19 during physical activity. His father had a history of palpitations as well. The electrocardiogram during tachycardia is illustrated in Fig 1. Intravenous procainamide failed to convert the tachycardia to sinus rhythm. The patient became hypotensive with a systolic blood pressure of 85 mmHg and had to be cardioverted.

What is your diagnosis? (Answer on Page 534)

SINGAPORE MED J 1992; Vol 33: 519-520

Fig 1 - 12 lead electrocardiogram during tachycardia on admission to hospital.



Department of Cardiology
Singapore General Hospital
Outram Road
Singapore 0316

W S Teo, MBBS, M Med(Int Med), MRCP(UK), FAMS
Senior Registrar

A Tan, MBBS, M Med(Int Med), FRACP, FAMS
Head & Senior Consultant Cardiologist

Correspondence to: Dr W S Teo

Fig 2 - 12 lead electrocardiogram during sinus rhythm.

